

The 'Great Imitator': A Case of COVID-19 Presenting with Encephalitis and Acute Coronary Syndrome

Guntur Darmawan^{1,2,3}, Samadhi Tulus Makmud⁴

¹Department of Internal Medicine, Faculty of Medicine, Krida Wacana Christian University, Jakarta, Indonesia.

²Department of Internal Medicine, Sumber Waras General Hospital, Jakarta, Indonesia.

³Department of Internal Medicine, Faculty of Medicine, Universitas Padjadjaran, Bandung, Indonesia.

⁴Department of Neurology, Sumber Waras General Hospital, Jakarta, Indonesia.

Corresponding Author:

Guntur Darmawan, MD. Department of Internal Medicine, Faculty of Medicine, Krida Wacana Christian University. Jl. Arjuna Utara no. 6, Jakarta 11470, Indonesia. email: guntur.darmawan@ukrida.ac.id.

ABSTRAK

Meskipun manifestasi tipikal Coronavirus disease-19 (COVID-19) adalah gejala saluran nafas, COVID-19 dapat memiliki tampilan awal klinis gejala ekstra-pulmonal. Kami melaporkan satu kasus menarik COVID-19 pada pasien perempuan dengan gejala awal gangguan sistem saraf pusat dan infark miokardial. Keterlibatan multiorgan pada infeksi COVID-19 memungkinkan presentasi klinis atipikal yang mungkin terabaikan oleh klinisi.

Kata kunci: COVID-19, manifestasi ekstra-pulmonal, infark miokard akut, kejang, kehilangan kesadaran.

ABSTRACT

Although typically patients with coronavirus disease-19 (COVID-19) have pulmonary symptoms atypical cases can occasionally present with extra-pulmonary symptoms. We report an interesting case of COVID-19 female patient presenting with combination of central nervous system disorder and acute myocardial infarct as initial manifestation. Multiorgan involvement in COVID-19 might lead to multiple atypical presentation which could be overlooked by the physician.

Keywords: COVID-19, extra-pulmonary manifestation, acute myocardial infarct, seizure, loss of consciousness.

INTRODUCTION

Coronavirus disease-19 (COVID-19) has rapidly emerged as global pandemic and public health emergency. As it is officially named severe acute respiratory syndrome coronavirus 2 (SARS-CoV-2) by the International Committee on Taxonomy of Viruses, clinical manifestation of COVID-19 is mostly characterized by respiratory symptoms.¹ However, several extrapulmonary symptoms have been reported as first clinical manifestation in COVID-19 patient.^{2,3} Here, we report a COVID-19 patient having combination of central nervous system

disorder and acute coronary syndrome as initial manifestations.

CASE ILLUSTRATION

A 41-year-old Indonesian female presented to our institution due to loss of consciousness after a generalized seizure episode lasting for minutes within an hour prior to admission. She experienced episodes of headache, chest discomfort, shortness of breath and fever since the day before admission. No cough, sore throat, anosmia, or gastrointestinal symptoms were noted. Past medical history was unremarkable

except hypertension for 1.5 year, treated with ramipril 5 mg/day. She did not smoke, drink alcohol, or use any illicit drug. She had just finished her menstruation 2 days prior to admission. She worked as an online-based motorcycle-taxi driver and had no history of travelling out of the city. On admission, the patient was comatose with initial blood pressure was 180/100 mmHg, heart rate was 110 beats/minute, respiratory rate of 28 times/minute and body temperature was 39°C. There was no cardiac murmur, no respiratory crackles or wheezes, and no rashes at general physical examination. Her pupil was isochor with positive light reflects bilaterally. Neck stiffness was absent. Laboratory examination showed anemia (hemoglobin 6.1 g/dL, hematocrit 21.7%), thrombocytosis (742,000/ μ L) and leukocytosis (36,900/ μ L; differential count showing 94% neutrophil and 3% lymphocyte). Peripheral blood smear demonstrated microcytic hypochromic anemia, leukocytosis with toxic granulation, neutrophilia, lymphocytopenia, and thrombocytosis with no morphology abnormality. Serum electrolyte were low for potassium, calcium, and magnesium (1.6 mmol/L, 0.88 mmol/L, and 1.3 mg/dl respectively). C-reactive protein was normal, IgM and IgG anti SARS-CoV-2 results were non-reactive. Urinary examination was unremarkable. Patient's serum troponin I level was elevated (1.43 ng/mL; normal value: 0.00-0.02 ng/mL). Electrocardiogram revealed sinus rhythm with giant T wave inversion at v2-4. (**Figure 1**) Chest X-ray showed no pulmonary abnormality and brain CT was normal with no sign of edema, hemorrhage, or space occupying lesion. A

provisional diagnosis of sepsis, encephalitis, non-ST elevation myocardial infarct was made. Patient was intubated and treated with continuous IV heparin, aspirin, clopidogrel, nitrate, bisoprolol, ramipril, statin, levofloxacin, ceftriaxone, dexamethasone, acyclovir, and correction of electrolyte. We also transfused packed red blood cells. Bed side echocardiography examination demonstrated hypokinetic at mid-apical anterior, anteroseptal, and diastolic dysfunction. Additional serum magnesium examination revealed hypomagnesemia (1.3 mg/dL) so that magnesium sulphate infusion was started. Gram stain of bronchial sputum showed Gram-negative bacilli and neither acid-fast bacilli nor potassium hydroxide 10% examinations was present. On day-3 of admission, the high-grade fever episodes were still persisted. Repeat laboratory showed hemoglobin 10.1 g/dL, hematocrit 34.4%, leucocyte 31,500/ μ L, thrombocytes 742,000/ μ L, and anti-HIV was non-reactive. We then decided to shift the antibiotic to meropenem. Lumbar fluid examination at day 4 of admission was positive for both Nonne and Pandy reaction with slight increase of glucose (100.3 mg/dL). Blood culture revealed no growth of microorganism and bronchial sputum culture yielded *Acinetobacter calcoaceticus*, susceptible to meropenem. Nonetheless, the patient's condition did not improve with continuous high-grade fever episodes until day-5 of admission. We then planned to perform tracheostomy. A repeat pre-operative rapid COVID-19 was unexpectedly reactive; therefore, we performed nasopharyngeal swab test for polymerase chain reaction (PCR) to detect the presence of SARS-

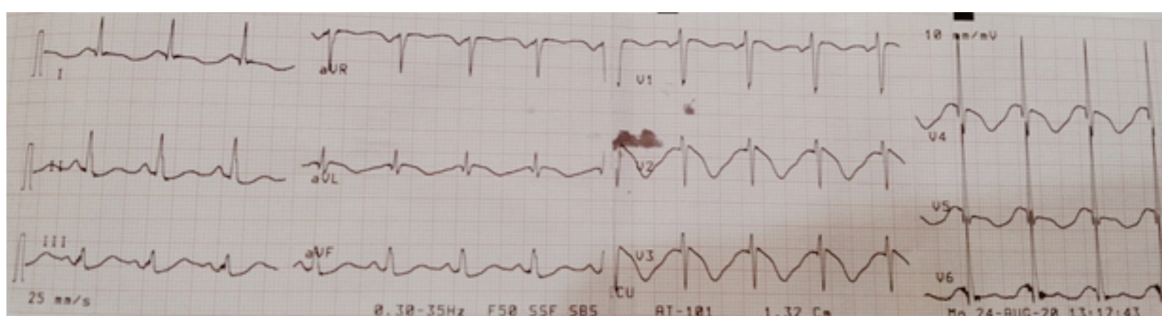


Figure 1. Electrocardiogram: giant T wave inversion at v2-4.

CoV-2 and transferred the patient to isolation room. Unfortunately, the patient was rapidly deteriorated and eventually succumbed in the following day while still awaiting the PCR swab examination result. Two days later, PCR swab examination revealed positive for COVID-19.

DISCUSSION

COVID-19 can manifest as various signs and symptoms, acting as great imitator. While most people are familiar with the hallmark respiratory symptoms of COVID-19—cough, fever, dyspnea, -COVID-19 might present with extra-pulmonary problems such as acute coronary syndrome, neurological illness, electrolyte abnormalities.⁴⁻⁶ Our case interestingly demonstrated an atypical combination of central neurological and cardiac symptoms with no respiratory symptom as presenting clinical symptoms. Of which, COVID-19 was initially overlooked. A review by Lai summarized prevalence of extra-pulmonary manifestations in patient with COVID-19, including acute cardiac injury manifestation (8-12%), impaired consciousness (7.5%), and seizure (0.5%).⁵ Moreover, less studies specifically reported extra-pulmonary symptoms as initial presentation of COVID-19 patient. A case series by Bangalore reported 10 of 18 confirmed COVID-19 patients with myocardial injury had ST-segment elevation as initial presentation to hospital in New York.⁷ To a lesser extent, central nervous system manifestation such as encephalitis, seizure have been reported in minority of cases.^{8,9} The exact pathophysiology behind these manifestations are still under thorough investigation. It is proposed that angiotensin-converting enzyme 2 (ACE2)-mediated direct viral toxicity, tissue injury, and dysregulation of immune responses underlie these features.^{10,11} Moreover, the leukocytosis in our case hid the presence of viral infection; normal initial CRP level and chest X-ray blunted clinical awareness of COVID-19. Thus, COVID-19 PCR examination was not performed initially during admission or lumbar fluid examination. Yet, our patient

had a high neutrophile to lymphocyte ratio, which is a risk factor for disease severity.¹² Our patient also developed electrolyte imbalance, which might be due to ACE2-mediated renal loss in COVID-19.¹³

Hypertension was the only comorbid in our patient. Several studies described the presence of hypertension in 15-30% of COVID-19 patients, which might associate with disease severity and mortality.^{14,15} In addition, our patient took ramipril as her maintenance drug. Although it was hypothesized that ACE inhibitor linked with increase of ACE2 expression and complication from COVID-19, recent evidence does not support this deleterious hypothesis and discontinuation of ACE inhibitor treatment.^{16,17} During family interview, neither her family nor neighbor were known to have history of COVID-19; however, her occupation might risk her for acquiring COVID-19 infection.

Furthermore, our case delivered some important messages. Cautious interpretation of laboratory result is needed in interpreting rapid antibody serology result. As described by Peeling et. al., IgM antibody of COVID-19 started to be detectable within 5 to 10 days after the onset of clinical symptoms and closely followed by IgG antibody.¹⁸ Initial non-reactive serology rapid antibody test and “normal” chest X-ray could not exclude SARS-CoV-2 infection. Clinical correlation and serial observation are essential in raising clinical suspicion and deciding to undergo PCR swab confirmatory examination. It is important that in the pandemic era, clinicians are aware of the possibility of COVID-19 even in the absence of respiratory symptoms. As shown in our case, COVID-19 patients could rapidly deteriorated and diagnosis was established after the patient died. Hence, unawareness resulted in delayed testing, diagnosis, treatment, and prevention of transmission.

CONCLUSION

This case underlined multi-system involvement of COVID-19 infection. It is necessary for clinician to early recognize

extra-pulmonary symptoms of COVID-19 infection since COVID-19 might act as great masquerader.

ACKNOWLEDGMENTS

The authors thank Eko B. Prasetyo, MD, Fonny M. Tedjo, MD, Debora Nurhadi, MD, Lukman Jauhari, MD, Ferry, MD, Ivy Jesslyn, MD, Siska Marianna, MD, Desy Trisnawati, MD, Antony Yaputra, MD for valuable contribution to this article

CONFLICT OF INTEREST

None

ETHICAL STATEMENT

Informed consent was obtained from patient's family prior to the publication of this case.

REFERENCES

1. Del Rio C, Malani PN. COVID-19—new insights on a rapidly changing epidemic. *JAMA*. 2020;323(14):1339-40.
2. Fischer Q, Darmon A, Ducrocq G, Feldman L. Case report of anterior ST-elevation myocardial infarction in a patient with coronavirus disease-2019. *Eur Heart J Case Reports*. 2020;4:1-5.
3. Sohal S, Mossammat MJ. COVID-19 Presenting with Seizures. *IDcases*. 2020(20):e00782.
4. Asadi-Pooya AA, Simani L. Central nervous system manifestations of COVID-19: A systematic review. *J Neurol Sci*. 2020(413):116832.
5. Lai C-C, Ko W-C, Lee P-I, Jean S-S, Hsueh P-R. Extra-respiratory manifestations of COVID-19. *Int J Antimicrob Agents*. 2020;56(2):106024.
6. Bansal M. Reviews: Cardiovascular disease and COVID-19. *Diabetes Metab Syndr*. 2020;14:247-50.
7. Bangalore S, Sharma A, Slotwiner A, et al. ST-segment elevation in patients with Covid-19—a case series. *NEJM*. 2020;382:2478-80.
8. Anand P, Al-Faraj A, Sader E, et al. Seizure as the presenting symptom of COVID-19: a retrospective case series. 2020;112:107335.
9. Moriguchi T, Harii N, Goto J, et al. A first case of meningitis/encephalitis associated with SARS-Coronavirus-2. *Int J Infect Dis*. 2020;94:55-8.
10. Gupta A, Madhavan MV, Sehgal K, et al. Extrapulmonary manifestations of COVID-19. *Nat Med*. 2020;26(7):1017-32.
11. Zheng KI, Feng G, Liu W-Y, Targher G, Byrne CD, Zheng M-H. Extrapulmonary complications of COVID-19: A multisystem disease? *J Med Virol*. 2020:1-13.
12. Kong M, Zhang H, Cao X, Mao X, Lu Z. Higher level of neutrophil-to-lymphocyte is associated with severe COVID-19. *Epidemiol Infect*. 2020;148:e139.
13. Lippi G, South AM, Henry BM. Electrolyte imbalances in patients with severe coronavirus disease 2019 (COVID-19). *Ann Clin Biochem*. 2020;57(3):262-5.
14. Lippi G, Wong J, Henry BM. Hypertension and its severity or mortality in Coronavirus Disease 2019 (COVID-19): A pooled analysis. *Arch Intern Med*. 2020;130(4):304-9.
15. Singh AK, Gupta R, Misra A. Comorbidities in COVID-19: Outcomes in hypertensive cohort and controversies with renin angiotensin system blockers. *Diabetes Metab Syndr*. 2020;14(4):283-7.
16. Fosbøl EL, Butt JH, Østergaard L, et al. Association of angiotensin-converting enzyme inhibitor or angiotensin receptor blocker use with COVID-19 diagnosis and mortality. *JAMA*. 2020;324(2):168-77.
17. Kreutz R, Algharably EAE-H, Azizi M, et al. Hypertension, the renin-angiotensin system, and the risk of lower respiratory tract infections and lung injury: implications for COVID-19: European Society of Hypertension COVID-19 Task Force Review of Evidence. *Cardiovasc Res*. 2020;116(10):1688-99.
18. Peeling RW, Wedderburn CJ, Garcia PJ, et al. Serology testing in the COVID-19 pandemic response. *Lancet Infect Dis*. 2020;20(9):e245-e9.