

## Cerebral Venous Sinus Thrombosis in Systemic Lupus Erythematosus

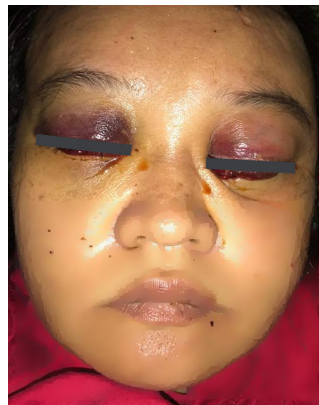*Guntur Darmawan<sup>1</sup>, Laniyati Hamijoyo<sup>1</sup>, Amaylia Oehadian<sup>1</sup>, Ria Bandiara<sup>1</sup>,  
Lisda Amalia<sup>2</sup>*

<sup>1</sup> Department of Internal Medicine, Faculty of Medicine, Padjadjaran University, Bandung, Indonesia.

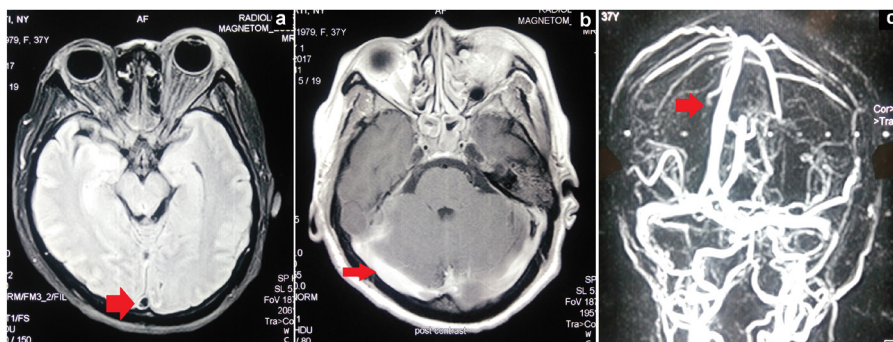
<sup>2</sup> Department of Neurology, Faculty of Medicine, Padjadjaran University, Bandung, Indonesia.

**Corresponding Author:**

Ria Bandiara, MD. PhD. Department of Internal Medicine, Faculty of Medicine, Padjadjaran University - Hasan Sadikin Hospital. Jl. Pasir Kaliki no. 190, Pasteur, Bandung, Indonesia. email: riabandi81@yahoo.co.uk.



**Figure 1.** Swelling and erythema at bilateral palpebral



**Figure 2.** Axial brain MRI showed empty delta sign (a), axial brain MRI showed enhancement of straight sinus (b) and MR venography showed thrombosis in the cavernous sinus (c)

A 38-year-old woman presented with general weakness and vaginal bleeding. One month prior, she had been diagnosed with Evans syndrome (haemolytic anemia with positive Coombs test and thrombocytopenia) and was given oral steroid as maintenance therapy. Her serology examination was negative for hepatitis B, hepatitis C, and human immunodeficiency virus (HIV). Her obstetrical history was marked by miscarriage in second pregnancy and preeclampsia in third pregnancy. She used hormonal contraceptives until 5 months prior to admission. On physical examination, she had anemic conjunctiva and no organomegaly. Blood tests were significant for anemia (3.4 g/dl) and thrombocytopenia (28,000/ $\mu$ l). Her vaginal bleeding had ceased, however her platelet continued decreasing to 12,000/ $\mu$ l during first several days of hospitalization despite receiving platelet transfusion. On the tenth hospital day, she suddenly complained of severe headache and blurred vision. She had bilateral edema and erythema of palpebral, chemosis, decreased in visual acuity, and reduced ocular motility. (**Figure 1**) Ear and nose examination were normal. Peripheral blood smear showed no blast. Prothrombine time (PT), INR, APTT tests were normal and D Dimer was slightly increased (3.3 mg/l; NV  $\leq$ 0.5 mg/l). Urine examination revealed proteinuria with 24 hour urine protein was 1,863 mg (NV < 150 mg/day). We assessed her as cavernous sinus thrombosis and treated her empirically with intravenous broad-spectrum antibiotics, morphine drip. Either digital subtraction angiography or anticoagulant was deferred due to low platelet. Further examination revealed positive for ANA, anti-SSA, and diagnosis of SLE was established. Anticardiolipin antibodies of IgG and IgM and anti-beta2 glycoprotein antibodies of IgM and IgG tests were non reactive. Methylprednisolone pulse therapy (1g/day) was given for 3 consecutive days, and then tapered to oral methylprednisolone. She additionally received azathioprine 50 mg tab BID. Meanwhile her clinical symptoms alleviated and platelet count was increased, brain MRI and MR venography finally performed suggesting cerebral venous sinus thrombosis. (**Figure 2**) She got additional oral anticoagulant rivaroxaban 15

mg tab BID and eventually discharged.

Cerebral venous sinus thrombosis may be the presenting symptoms or occur concomitantly within the onset of SLE.<sup>1-3</sup> Our patient had SLE, meeting 4 of the Systemic Lupus International Collaborating Clinic classification criteria (hemolytic anemia, thrombocytopenia, renal involvement, and positive for ANA test). Vasculitis due to endothelial cell injury mediated by immune-complex deposition is proposed to be the pathogenesis of CVST in SLE. Hypercoagulable state could be other etiology factor.<sup>1,4,5</sup> Antiphospholipid antibodies were absent in our case as reported in some cases, emphasizing vasculitis as the underlying mechanism.<sup>4,6</sup> Treatment of CVST in SLE consisting of anticoagulant, steroid, and immunosuppressant.<sup>4,7</sup> This case elicits intriguing problem: CVST and thrombocytopenia. Anticoagulant treatment is proposed as the cornerstone treatment for CVST, however it was deferred due to risk of bleeding in thrombocytopenia.<sup>1,8</sup> Steroid plays role in treatment of CVST in SLE, owing to its anti-inflammatory property. As shown in previous cases,<sup>4,7</sup> the patient had remarkable response to high dose steroid treatment and eventually got anticoagulant after her platelet had increased. In summary, prompt diagnosis and treatment of CVST are important for a favorable prognosis.

## ETHICAL STATEMENT

Informed consent was obtained from patient's family prior to the publication of this case and accompanying image.

## REFERENCES

1. Saposnik G, Barinagarrementeria F, Brown RD, et al. Diagnosis and management of cerebral venous thrombosis: A statement for healthcare professionals from the American Heart Association/American Stroke Association. *Stroke*. 2011;42:1158–92.
2. Ashjazadeh N, Haghighi AB, Poursadeghfard M, et al. Cerebral venous-sinus thrombosis: A case series analysis. *Iran J Med Sci*. 2011;36:178–82.
3. Saadatnia M, Fatehi F, Basiri K, et al. Cerebral venous sinus thrombosis risk factors. *Int J Stroke*. 2009;4: 111–23.
4. Wang L, Chen H, Zhang Y, et al. Clinical characteristics of cerebral venous sinus thrombosis in patients

- with systemic lupus erythematosus: A single-centre experience in China. *J Immunol Res*. 2015;1-7.
5. Faria R, Gonçalves J, Dias R. Neuropsychiatric systemic lupus erythematosus involvement: towards a tailored approach to our patients? *Rambam Maimonides Med J*. 2017;8:e0001.
  6. Nishida H, Wakida K, Sakurai T. Cerebral venous thrombosis as a complication of neuropsychiatric systemic lupus erythematosus. *Intern Med*. 2015;54:837–41.
  7. Lee MK, Kim JH, Kang HR, et al. Systemic lupus erythematosus complicated with cerebral venous sinus thrombosis : A report of two cases. *J Korean Med Sci*. 2001;16:351–4.
  8. Murthy K, Chefitz D. Cerebral venous sinus thrombosis: A case report with review of diagnosis and treatment strategies. *J Clin Case Reports*. 2014;4:1-3.