

Adrenal Myelolipoma, Cholelithiasis and Calcified Spleen: Retrospective Diagnosis of Sickle Cell Anemia Using a Novel Triad of Abdominal Imaging Findings

Sandeep G. Jakhere, Raju S. Kumbhar, Harshal V. Dhongade

Department of Radiology, BYL Nair Charitable Hospital and TN Medical College, Mumbai Central, Mumbai, India.

Correspondence mail:

Department of Radiology, BYL Nair Charitable Hospital and TN Medical College, Mumbai Central, Mumbai, India.
email: drsandeepjakhere@gmail.com.

ABSTRAK

Anemia sel sabit merupakan kelainan pada rantai globin yang diwariskan dengan prevalensi tinggi di semenanjung India. Proporsi yang bermakna dari pasien dengan anemia sel sabit muncul lambat dalam kehidupan dan berisiko menimbulkan sejumlah komplikasi misalnya sindroma dada akut dan episode nyeri hingga dicapai diagnosis pasti dan dimulainya pengobatan yang tepat. Kami melaporkan trias pencitraan abdomen baru, yang belum dilaporkan dalam kepustakaan hingga kini dan yang dapat menunjukkan diagnosis anemia sel sabit dengan teknik retrospektif. Dengan trias temuan abdomen ini, pasien perlu dicurigai menderita hemoglobinopati dan perlu dirujuk untuk pemeriksaan hematologic lebih lanjut. Meskipun pada kasus kami, pasien ini didiagnosis menderita anemia sel sabit berdasarkan morfologi sel darah merah yang abnormal dan elektroforesis haemoglobin, perlu diingat bahwa trias temuan ini dapat juga ditemukan pada hemoglobinopati lainnya yang mencetuskan kondisi anemia kronik.

Kata kunci: anemia sel sabit, mielolipoma adrenal, batu empedu, limpa terkalsifikasi.

ABSTRACT

Sickle cell anemia is an inherited abnormality of the globin chain with very high prevalence in the Indian subcontinent. A significant proportion of these patients present late in life and are at a risk of complications like acute chest syndrome and painful episodes till a definitive diagnosis is reached and appropriate treatment is started. We report a novel triad of abdominal imaging findings which is not reported in literature until now and which may suggest a diagnosis of sickle cell anemia in retrospect. Patients with this triad of abdominal findings should be suspected to have an underlying hemoglobinopathy and should be referred for further hematological workup. Although in our case the patient was diagnosed to have sickle cell anemia depending on the abnormal morphology of red cells and hemoglobin electrophoresis, it should be remembered that this triad of findings may be seen in other hemoglobinopathies which induce a state of chronic anemia.

Key words: sickle cell anemia, adrenal myelolipoma, gall stones, calcified spleen.

INTRODUCTION

Adrenal myelolipoma is a rare non functional benign tumor which is incidentally diagnosed in asymptomatic patients in the 4th and 5th decades.¹

It has a prevalence of approximately 0.08-0.4% on autopsy findings.² The co existence of adrenal myelolipomas and cholelithiasis is indeed very unusual and has rarely been documented. In a

recent article published in 2011 Dahiya et al.³ stated that this unusual association has been reported only twice prior to their publication^{4,5} We found another case report⁶ describing this unusual association taking the total count to four prior to our publication. However an extensive search for literature did not reveal any reports of association of a shrunken calcified spleen along with adrenal myelolipoma and gall stones and this is probably the first case report of this unusual triad of findings. We present a case of a 28 year old female who was retrospectively diagnosed to have sickle cell anemia based on this triad of findings on abdominal imaging.

CASE ILLUSTRATION

A 28 year old female presented with right hypochondriac pain for the past 6 months which was not associated with retrosternal burning pain or vomiting. On palpation there was mild tenderness in the right hypochondriac region and mild pallor was seen in the conjunctiva, otherwise, rest of the systemic examination was within normal limits. An abdominal ultrasound study revealed multiple gallstones ranging in size from 0.5 cm-1 cm. The gall bladder wall appeared normal and there was no evidence of any peri cholecystic fluid collection. A fairly large soft tissue mass was seen in the right supra renal region measuring approximately 6.9 cm X 5.5 cm in maximum dimensions. The mass was seen to be separate from the liver and the right kidney, however, the right adrenal gland could not be visualized separately. The mass appeared predominantly hyperechoic in echo texture with few hypoechoic areas within it. There was no calcification within the mass and Doppler evaluation did not reveal any significant vascularity within the mass. A neoplastic mass arising from the right adrenal gland was suspected and the patient was referred for CT scan of the abdomen. CT scan showed a soft tissue mass in the right supra renal region measuring approximately 7 cm x 5.8 cm [Figure 1, 4 (short arrow)]. The right adrenal gland could not be identified separately. The mass showed ill defined areas of soft tissue attenuation (25 HU) which showed mild enhancement on the post contrast scans. In addition few areas with

fat attenuation (-5 HU) were also seen within the mass. Based on these characteristic imaging findings, working diagnosis of right adrenal myelolipoma was made. In addition multiple hyper dense calculi were seen in the gallbladder without any radiological evidence of cholecystitis [Figure 2]. The spleen could not be visualized in the splenic fossa. A densely calcified mass was seen in the splenic fossa which was presumed to be a chronic infarcted calcified spleen [Figure 3, 4 (long arrow)].

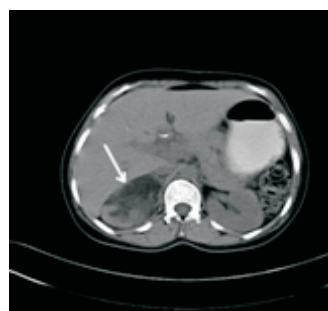


Figure 1. Axial plain CT scan image showing a mass in the right supra renal region containing low attenuation areas consistent with myelolipoma.

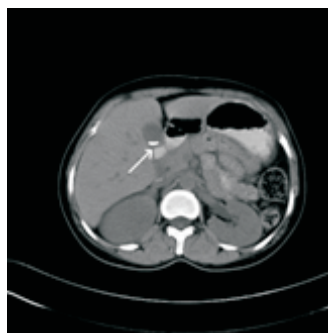


Figure 2. Axial plain CT scan image showing multiple hyper dense calculi in the gall bladder.

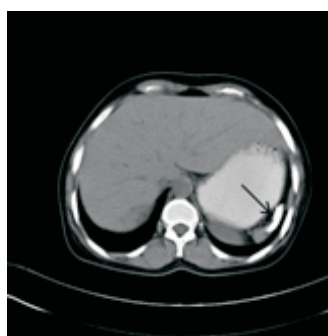

Figure 3. Axial plain CT scan image showing a calcified mass in the splenic fossa.

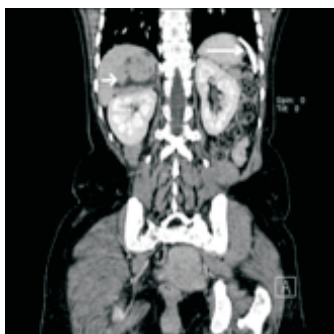

Figure 4. Coronal MPR image showing the supra renal mass (short arrow) and the calcified mass in the splenic fossa (long arrow). Note that the spleen is not visualized in the splenic fossa.

Blood examination revealed hemoglobin of 8.4 gm/dl and red blood cell count of 3.02×10^6 /microlitre. The mean corpuscular volume, MCH and MCHC were 81.7 fl, 27.8 pg and 34.0 gm/dl respectively. Few target cells and sickle cells were also seen. Hemoglobin electrophoresis revealed an Hb S of 86.4%, Hb A2 of 3.3% and Hb F of 6.5% thereby confirming a diagnosis of sickle cell anemia. At the time of submitting the case report for publication the patient is undergoing pre surgical workup for removal of the adrenal tumour.

DISCUSSION

Sickle cell anemia is an inherited abnormality of the beta globin chain due to substitution of valine for glutamic acid resulting in abnormal shaped (sickled) red blood cells (RBC). These deformed RBC's have increased propensity for microvascular occlusion leading to ischemia and infarction in various body organs. As the RBC's have abnormal shape, they are removed earlier from the blood circulation resulting in hemolytic anemia.

The highest frequency of sickle cell disease is found in the tropical regions; particularly sub Saharan Africa, India and Middle East.⁷ The prevalence of sickle cell disease in India has ranged from 9.4% to 22.2%⁸ in endemic areas with India alone accounting for 50% of cases all over the world.⁹ The association between adrenal myelolipoma and haemoglobinopathies including thalassemia,^{10,11} sickle cell anemia¹² and hereditary spherocytosis¹³ has been proposed earlier by a few authors although there might

definitely be more complex pathogenetic mechanisms underlying this entity.

Adrenal myelolipomas are rare benign tumors composed of adipose tissue and myeloid elements. The association of myelolipoma with obesity, hypertension and malignancies has been described earlier¹⁴ however an association with gallstones has been described in only 4 cases prior to our publication.³⁻⁶ A chronically infarcted calcified spleen along with adrenal myelolipoma and gallstones on computed tomography has not been reported till now to the best of our knowledge. Dahiya et al stated that the co occurrence of gall stones and adrenal myelolipomas may be an incidental finding or there may be a pathogenetic mechanism which may be yet unknown. Pleuripotent hematological stem cells are present in the embryonic mesonephros which subsequently differentiates to form the adrenal cortex. Metaplasia of these embryonic nests of stem cells may give rise to the myeloid elements within the adrenal. Occurrence of myelolipomas in association with hemoglobinopathies suggests that the myeloid elements in adrenal gland are under the influence of erythropoietin which is produced in abundance due to the chronic anemic state. Thus extra medullary hematopoiesis within the adrenal may contribute to the development of myelolipomas.¹⁰

Approximately 50% of adults and 20% children with sickle cell anemia patients have gallstones and 94% of patients undergo autosplenectomy by the age of 5 years.¹⁵ However the exact incidence of adrenal myelolipomas in patients with sickle cell anemia is not known with only a few case reports documented in literature. Most probably the stimulation of adrenal myeloid cells is a chronic process which occurs over a long period of time as in our patient who was not diagnosed with sickle cell anemia upto the age of 28 years. The late presentation and chronic anemia also explain the calcified spleen that must have undergone repeated infarctions over a long period of time ultimately resulting in a calcified avascular mass.

It is important to recognize this triad of findings on abdominal imaging and refer these patients for appropriate hematological workup. Approximately 61% of patients with sickle cell

anemia present by the end of the first year, 78% by the end of second year and 86% by the end of the third year. The remaining 14% present by the age of 10 although late presentation by the age of 20 years is also known.¹⁶ A sizeable number of patients present late in life and are at risk of complications until a definitive diagnosis is achieved and treatment is initiated. The mainstay of treatment of sickle cell anemia is hydroxyurea, an oral chemotherapeutic agent that acts by reducing the production of red cells containing a high concentration of sickle hemoglobin and favoring the production of red cells containing high fetal hemoglobin levels. A Multicenter Study of Hydroxyurea in Sickle Cell Anemia conclusively showed that, over 2.5 years, hydroxyurea diminished the morbidity of SCA in adults with frequent painful episodes by reducing the incidence of painful episodes and acute chest syndrome by nearly half.¹⁷

CONCLUSION

Young adults with sickle cell anemia are a vulnerable population with a high risk of mortality at the interface between pediatric and adult medical care. Quinn et al¹⁸ even argued for creating special clinics for adolescent and young adults with SCA, run jointly by pediatric and adult medical providers because young adults seem to be at high risk of death. It is of utmost importance that the diagnosis of SCA be made at the earliest and this novel triad of abdominal findings should alert the radiologist to refer the patient for further detailed hematological workup. Although in our case the patient was diagnosed to have sickle cell anemia depending on the abnormal morphology of red cells and hemoglobin electrophoresis, it should be remembered that this triad of findings may be seen in other hemoglobinopathies also which induce a state of chronic anemia.

REFERENCES

- Vick CW, Zeman RK, Mannes E, et al. Adrenal myelolipoma; CT and ultrasound findings. *Urol Radiol*. 1994;6:7-13.
- Lam KY. Lipomatous tumors of the adrenal gland. *J Urol Pathol*. 1995;3:95.
- Kalra R, Dahiya N, Singh G, Modi S, Godara R. Adrenal myelolipoma associated with cholelithiasis – a case report. *Int J Pharm Sci Res*. 2011;2(4):1031-3.
- Kar DK, Agarwal A, Mishra AK, et al. Adrenal myelolipoma associated with cholelithiasis. *Indian J Urol*. 2001;18:66-9.
- Solis Daun JO, Rodriguez Garcia R, Torres Trejo A, Alor Guzman M. Adrenal myelolipoma associated with lithiasic cholecystitis, hiatal hernia and esophagitis. *Rev Gastroenterol Mex*. 1999;64:143-5.
- Kunieda Y, Miyazaki T, Fujimoto N, Higuchi A, Suzuki T. A case of adrenal myelolipoma with colonic cancer and gallstones. *Gan No Rinsho*. 1990;36(8):949-54.
- Weatherall DJ, Clegg JB. Inherited haemoglobin disorder: an increasing global health problem. *Bull. World Health Org*. 2001;79(8):704-12.
- Awasthy N, Aggarwal KC, Goyal PC, et al. Sickle cell disease: Experience of a tertiary care center in a nonendemic area. *Ann Trop Med Publ Health*. 2008;1(1):1-4.
- Kate SL, Lingojar DP. Epidemiology of sickle-cell disorder in the state of Maharashtra. *Int J Human Genetics*. 2002;2(3):161-7.
- Au WY, Tam PC, Ma SK, Lam KY. Giant myelolipoma in a patient with thalassemia intermedia. *Am J Hematol*. 2000;65(3):265-6.
- Kelekis NL, Alexopoulou E, Broutzos EN, et al. Giant adrenal myelolipoma with minimal fat content in a patient with homozygous beta-thalassemia: appearance on MRI. *J Magn Reson Imaging*. 2003;18(5):608-11.
- Cina SJ, Gordon BM, Curry NS. Ectopic adrenal myelolipoma presenting as a splenic mass. *Arch Pathol Lab Med*. 1995;119(6):561-3.
- Sekido N, Kawai K, Takeshima H, et al. Adrenal myelolipoma associated with hereditary spherocytosis. *Int J Urol*. 1996;3(1):61-3.
- Ersoy E, Ozdoğan M, Demirağ A, et al. Giant adrenal myelolipoma associated with small bowel leiomyosarcoma: a case report. *Turk J Gastroenterol*. 2006;17(2):126-9.
- Lonergan GJ, Cline DB, Abbondanzo SL. Sickle cell anemia. *Radiographics*. 2001;21(4):971-94.
- Karnon J, Zeuner D, Ades AE, et al. The effects of neonatal screening for sickle cell disorders on lifetime treatment costs and early deaths avoided: a modelling approach. *J Public Health Med*. 2000;22(4):500-11.
- Charache S, Terrin ML, Moore RD, et al. Effect of hydroxyurea on the frequency of painful crises in sickle cell anemia. *N Engl J Med*. 1995;332:1317-22.
- Quinn CT, Rogers ZR, McCavit TL, Buchanan GR. Improved survival of children and adolescents with sickle cell disease. *Blood*. 2010;115(17):3447-52.