

Case Report

Evaluation of autologous adipose-derived mesenchymal stem cell therapy in a patient with acute ischemic cardiomyopathy

Masatatsu Mishima¹, Xiaolan Liu²

¹Miki Medical Corporation Sun Field Clinic, Time24 Building, Aomi, Koto-ku, Tokyo, Japan

²World Academy of Anti-aging and Regenerative Medicine, Imperial Tower, Tokyo, Japan

Abstract. Adipose-derived mesenchymal stem cells (AdMSC) is an innovative approach for the treatment of a range of diseases that are not responsive to standard therapies. Their promising role in tissue engineering and ability to modulate the immune system are attractive. AdMSC can differentiate into endothelial cells, myocytes, chondrocytes and osteoblasts. Our aim was to investigate safety and efficacy of intravenous autologous AdMSC in a patient with acute myocardial infarction. AdMSC treatment was associated with improved recovery of the left ventricular function (LVEF), electrocardiographic (ECG) findings and serum BNP level in this patient. AdMSC may be considered to be one of future therapeutic agents for diseases that cannot be cured by conventional therapeutic methods.

Keywords: Adipose-derived mesenchymal stem cells, autologous, myocardial infarction, cell therapy

Introduction

It has been reported that bone marrow-derived hematopoietic and mesenchymal stem cells are administered to the left ventricular endocardial site of myocardial infarction patients to restore left ventricular ejection fraction (LVEF) and myocardial infarction sites. [1-6]. It has also been shown that cardiac function has been improved by bone marrow-derived mesenchymal stem cells from hematopoietic cells administered via intracardial wall in myocardial infarction patients [7] or by intravenous administration [8]. This indicates that hematopoietic and mesenchymal stem cells promoted cardiac function improvement in myocardial infarction.

On the other hand, it has been reported that cardiac function is restored even when adipose-derived mesenchymal stem cells (AdMSC) are administered to the intracardial inner wall of a myocardial infarction patient in addition to bone marrow origin [9]. There are few reports on the treatment of myocardial infarction using AdMSC, and cell therapy by intravenous administration is not well known. Therefore, adipose tissues of patients with acute myocardial infarction were collected, stem cells were extracted and expanded, and intravenously administered to the same patient. As a result, the improvement of heart function was observed which is reported here.

Patient and Treatment

A 47-year-old male patient had chief complaint of sudden chest pain. He was admitted and hospitalized for

treatment of acute myocardial infarction. The patient's family history included his father with hypertension and heart disease, and nothing in particular from his mother. The patient had high blood pressure, dyslipidemia, obesity and alcohol consumption (3 cans of beer / week) but no smoking and diabetes mellitus. He was taking medicines, carvedilol and enalapril maleate.

The patient received cardiac catheterization and stent therapy followed by thrombolytic therapy using anti-thrombotic drugs (clopidogrel sulfate, and baby aspirin) and radical scavenger.

Adipose-derived Mesenchymal Stem Cells

The procedure for isolation and propagation of AdMSC had been reported in details in our previous study [10]. After informed consent and approval of institutional review board, the adipose tissue was collected from abdominal (peri-umbilical) area of the same patient. Stromal vascular fraction containing mesenchymal stem cells which were capable of differentiating into adipocytes, endothelial cells, bone cells or cardiomyocytes were prepared by treating the adipose tissue with collagenase and separation on concentrator (Cytori manufactured by Celution®). When this cell group is cultured in our proprietary culture medium, sf-DOT (developed by BioMimetics Sympathies Inc., Tokyo, Japan), cells other than mesenchymal stem cells die out, so that only AdMSC proliferate. This culture medium does not contain any animal-origin serum.

* Corresponding author: Masatatsu Mishima, MD, PhD
 (e-mail: m.mishima@sunfield-c.com).

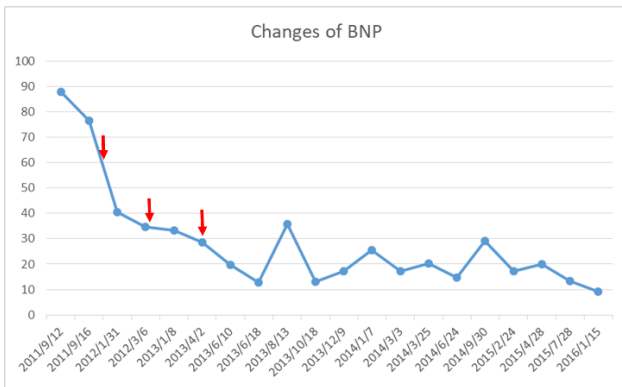


Figure 1. Changes in BNP values of myocardial infarction patients. Autologous AdMSC was administered at the time points indicated by red arrows. Intravenously administered 54 million (2011/11/30), 36.8 million (2013/03/07) and 32.8 million (2013/04/04) cells. The values of BMP continued to decrease after AdMSC administrations.

BNP (B-type natriuretic peptide) Test

B-type natriuretic peptide (BNP) is an excellent serum marker as a prognostic index for heart failure due to coronary artery injury. It can be easily measured in patient's serum [11-17]. Therefore, over 4 years after administration of AdMSC for treatment of myocardial infarction, the effect of AdMSC was examined mainly from the BNP concentration level.

Results

After emergency hospitalization, the patient was diagnosed as having acute myocardial infarction and received cardiac catheterization and stent therapy followed by thrombolytic therapy using anti-thrombotic drugs. The patient's serum BNP concentrations before and after AdMSC administrations at indicated time points are summarized in Fig. 1. The patient received AdMSC at the time points indicated by red arrows.

On September 12, 2011, the BNP value was 87.9 pg / ml. On November 30, 2011, 54 million AdMSC were administered intravenously. On September 12, 2012, cardiac function recovered to 98% as judged by electrocardiogram and echocardiography examinations. On March 7, 2013, 36.8 million AdMSC were intravenously administered again. Finally, on April 4, 2013, 32.8 million AdMSC were administered intravenously. On March 10, 2015, LVEF ejection fraction was 62% (echocardiogram examination), right heart load (electrocardiogram) and cardiac function had recovered to normal.

On November 30, 2011, the BNP value recovered to 40.6 pg / ml after the first administration of AdMSC, but such a mild BNP concentration continued until January 8, 2013. After the third AdMSC administration on June 10, 2013, the BNP value was recovered to an average value of 19.8 pg / ml, but thereafter it was mildly high concentration (BNP 20.4 - 35.7 pg / ml) until September 30, 2014. The BNP value was 9.1-19.9 pg / ml since February 24, 2015 and the reference value was 18.4 pg / ml for more than 1 year. The LVEF ejection rate was 62% (Figure 2, Table 1), right heart load (electrocardiogram) and other cardiac function test results were normal.

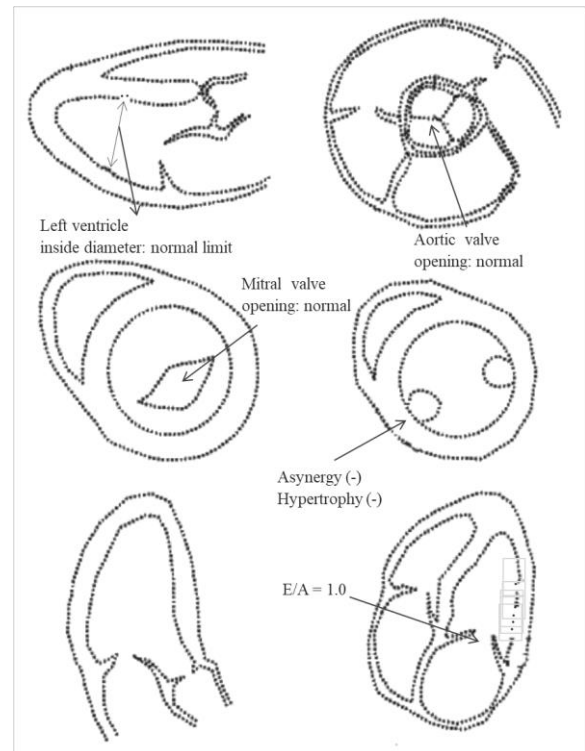


Figure 2. Echocardiography diagnosis on 10th March 2015: Left ventricle function: normal limit; right atrial load (-). The left ventricle lumen diameter is in the normal range, indicating that there is no left ventricular dysfunction maintenance and no right heart load

Discussion

An increase in BNP concentration in the blood is seen from the early stage of myocardial infarction, it is proportional to an increase in left ventricular diastolic pressure and decrease in cardiac output and is considered to be a better predictive index than LVEF [11-13]. The BNP value rises with the onset of myocardial infarction, peaks after about 20 hours and then declines [18]. However, there are reports that in severe cases bimodal rises again after 3 to 5 days [19].

In the reported patient, the BNP value was 87.9 pg / ml 4 days after onset, and the BNP value was 76.5 pg / ml even after 8 days. In the BNP high value group (BNP value of 80 pg / ml or more), the risk rate of myocardial infarction recurrence is reported to be 5 times as compared with the BNP low value group [14]. Based on these findings, we considered the risk of myocardial infarction recurrence high in our patient, and performed cell therapy using AdMSC.

AdMSC were administered intravenously 78 days after onset of myocardial infarction. This patient had a BNP value of 70 to 90 before administration and decreased to 40.6 pg / ml in 2 months after administration, but the BNP standard value 18.4 pg AdMSC were intravenously administered again because the condition of high concentration (33.3 to 34.7 pg / ml) continued for more than 1 year compared with / ml, and the cardiac function was not completely recovered. Initial AMSC administration, second and third cell therapies were made

TABLE 1
MEASURED VALUES BY ECHOCARDIOGRAPHY
EXAMINATION ON MARCH 10, 2015.

Measurement of Values	
Aortic diameter	32mm
Left atrium diameter	32mm
Interventricular septum thickness	10mm
Left ventricular posterior thickness	11mm
Left ventricular diastolic	55mm
Left ventricular end-systolic	37mm
Stroke volume	91mL
Left ventricular fractional shortening	34%
Ejection fraction	62%
IVC diameter	18/7mm

in the 13 and 14 months after the first treatment and the BNP value 19.8 pg / ml was recovered to the average value at 2 months after the third AMSC administration, but after 16 months it was mild. Although BNP value was 9.1 to 19.9 pg / ml for more than one year, from about 2 years after the third AMSCs administration, the BNP concentration standard value of 18.4, a value corresponding to 29 pg / ml was shown. The LVEF ejection fraction 62% (echocardiogram examination), right heart load (electrocardiogram) and cardiac function were also restored to normal. From these data, intravenous administration of AMSCs in myocardial infarction was shown to be an effective treatment.

According to the results of this study, BNP concentration or LVEF was not recovered to normal level by single administration of AdMSC. However, BNP concentration or LVEF recovered to normal level by re-administration of AdMSC. Cell therapy of bone marrow-derived or adipose tissue-derived mesenchymal stem cells is often based only on a single administration and it is thought that it will be a more effective treatment method by conducting re-administration of stem cells while looking for the BNP concentration to drop to normal limit. As an effect of mesenchymal stem cells administered to myocardial infarction patients, blood circulation improvement and infarct site reduction have been reported, and it is thought that AdMSC differentiated into vascular endothelial cells and cardiomyocytes [20-22]. However, in the experimental limb ischemia model, AdMSC are not found in the ischemic site, and there are reports that recovery of ischemia is due to endothelial cells and hepatocyte growth factor released from AdMSC. [23]. It is not clear whether improvement of cardiac function of this patient is due to differentiation of AdMSC administered intravenously into vascular endothelial cells or cardiomyocytes or by various growth factors from AdMSC. Also, it took 1 to 2 months from administration of AdMSC for BNP concentration to decrease. It is considered this

period to be the period necessary for the remodeling of blood vessels and myocardial walls of the ischemic part. Improvement of blood circulation at the site of myocardial infarction is an important condition for recovery of cardiac function. It has been reported that the administration of AdMSC improved circulation of the ischemic part in the model of limb ischemia experiment in nude mice [24, 25]. This indicates that AdMSC are effective not only for myocardial infarction but also for treatment of patients with cerebral infarction. In fact, although not AdMSC, good therapeutic effects have been reported when bone marrow-derived mesenchymal stem cells are administered to patients with cerebral infarction [26].

Cell therapy by stem cells is systemically administered by intravenous infusion or local injection of ischemic sites. The method used our patient was intravenous administration, and the stem cells were distributed to almost all tissues. Myocardial infarction is a risk factor for hypertension, hyperlipidemia, diabetes or coronary artery disease. AdMSC used in our study have been reported to have a wide range of therapeutic effects such as diabetes, heart disease, osteoarthritis, repair of soft tissue injury or anti-inflammatory effect [27, 28]. In addition, AdMSC have paracrine function related to vascular endothelial cells and hepatocytes growth factors or anti-apoptotic factors [21]. From these facts, it is shown that AdMSC are not only involved in the regeneration of cardiomyocytes and vascular endothelial cells in the site of myocardial infarction, but also on risk factors for myocardial infarction.

Fat tissue collection has significantly less patient burden than tissue collection from bone marrow and can easily proliferate. Besides, there is an advantage that 500 times more stem cells obtainable from adipose tissue than bone marrow [10, 29, 30].

As a treatment for myocardial infarction, coronary bypass surgery and thrombolytic therapy are known, but it is known that reperfusion injury (oxidative stress, inflammation, cardiomyocyte death occur [31, 32]. From the extensive therapeutic effects of AdMSC [21, 26, 27], it is also possible to protect myocardial walls from reperfusion injury.

There are reports on intravenous administration of autologous and allogeneic bone marrow derived mesenchymal stem cells in myocardial infarction patients [7, 8].

From these reports, it is said that the effect of allogeneic stem cells promoted the reduction of infarct site and improvement of cardiac function like autologous stem cells. In addition, heterogeneous immune responses were not observed in patients receiving mesenchymal stem cells derived from allogeneic bone marrow [7, 8]. This indicates that stem cell therapy using allogeneic stem cells, not autologous, is possible. It is important to be able to use adipose tissue-derived stem cells of healthy persons for treatment instead of patients in severe conditions. Stem cell therapy can be instantaneously administered to patients suffering from myocardial infarction or cerebral infarction or the like. This cell therapy is considered to be an effective treatment for serious patients with cardiovascular diseases.

Finally, cell therapy by mesenchymal stem cells has been reported to enhance immune competence and promote paracrine action of various growth factors or skin regeneration [27-29, 33, 34]. It is also involved in the cure and regeneration of arterial endothelial cell injury in diabetic lower limb ischemia [33]. These findings are thought to have caused "rejuvenation" by this cell therapy. Mesenchymal stem cells including AdMSC are considered to be one of the future therapeutic agents for diseases that cannot be cured by conventional or standard medical or surgical treatment.

Conflict of Interest

The authors declare no conflict of interest.

References

- Perin EC, HF, Dohmann HF, Borojevic R, et al. Transcatheter, autologous bone marrow cell transplantation for severe, chronic ischemic heart failure. *Circulation* 107:2294-2302, 2003.
- Perin EC, Silva GAY, Henry TD, et al. A randomized study of transcatheter injection of autologous bone marrow mononuclear cells and cell function analysis in ischemic heart failure (FOCUS-HF). *Am Heart J* 161:1078-1087, 2011.
- Tse HF, Thambar S, Kwong YL, et al. Prospective randomized trial of direct endomyocardial implantation of bone marrow cells for treatment of severe coronary artery disease (PROTECT-LAD trial). *Eur Heart J* 28:2998-3005, 2007.
- van Ramshorst J, Bax JJ, Beeres SL, et al. Intramyocardial bone marrow cell injection for chronic myocardial ischemia: a randomized controlled trial. *JAMA* 301:1997-2004, 2009.
- Tongers J, Losordo DW, Landmesser U. Stem and progenitor cell-based therapy in ischemic heart disease; promise, uncertainties and challenges. *Eur Heart J* 32:1197-1206, 2011.
- Gnecchi M, Danielli P, Cervio E. Mesenchymal stem cells therapy for heart disease. *Vascul Pharmacol* 57:48-55, 2012.
- Hare JM, Traverse JH, Henry TD, et al. A randomized double-blind, placebo-controlled, dose-escalation study of intravenous adult human mesenchymal stem cells (prochymal) after acute myocardial infarction. *J Am Coll Cardiol* 54:2277-2286, 2009.
- Hare JM, Fishman JE, Gerstenblith G, et al. Comparison of allogeneic vs autologous bone marrow-derived mesenchymal stem cells delivered by transcatheter injection in patients with ischemic cardiomyopathy: the POSEILON randomized trial. *JAMA* 308:2369-2379, 2012.
- Perin EC, Sanz-Ruiz R, Sánchez PL, et al., Adipose-derived regenerative cells in patients with ischemic cardiomyopathy: the PRECISE Trial. *Am Heart J* 168:88-95, 2014.
- Hirano A, Sano M, Urushihata N, Tanemura H, Oki K, Suzuki E. Assessment of safety and feasibility of human allogeneic adipose-derived mesenchymal stem cells in a pediatric patient. *Ped Res* 84:575-577, 2018.
- Redfors B, Chen S, Crowley A, et al. B-Type natriuretic peptide assessment in patients undergoing revascularization for left main coronary artery disease. *Circulation* 138:469-478, 2018.
- Zhang L, Tang F, Cai LP, et al. Research on the correlation of urine calcium integrin binding protein-1 and pro-BNP with ischemic heart failure. *Eur Rev Med Pharmacol Sci*. 2017; 21:4181-4185
- Lubien E, DeMaria A, Krishnaswamy P, et al. Utility of B-natriuretic peptide in detecting diastolic dysfunction: comparison with doppler velocity recordings. *Circulation* 105:595-601, 2002.
- Marrow DA, de Lemos JA, Sabatine MS, et al. Evaluation of B-type natriuretic peptide for risk assessment in unstable angina/non-ST-elevation myocardial infarction: B-type natriuretic peptide and prognosis in TACICS-TIMI 18. *J Am Coll Cardiol* 41:1264-1272, 2003.
- James SK, Lindbäck J, Tilly J, et al. Troponin and N-terminal pro-B-type natriuretic peptide predict mortality benefit from coronary revascularization in acute coronary syndromes: a GUSTO-IV sub-study. *J Am Coll Cardiol* 48:1146-1154, 2006.
- Heeschen C, Hamm CW, Mitrovic V, et al. N-terminal pro-B-type natriuretic peptide levels for dynamic risk stratification of patients with acute coronary syndromes. *Circulation* 110:3206-3212, 2004.
- Lindahl B, Lindbäck J, Jernberg T, et al. Serial analyses of N-terminal pro-B-type natriuretic peptide in patients with non-ST-segment elevation acute coronary syndromes: a fragmin and fast revascularisation during in stability in coronary artery disease (FRISK)-II substudy. *J Am Coll Cardiol* 45:533-541, 2005.
- Morita E, Yasue H, Yoshimura M, et al. Increased plasma levels of brain natriuretic peptide in patients with acute myocardial infarction. *Circulation* 88:82-91, 1993.
- Mizuno Y, Yasue H, Oshima S, et al. Effects of angiotensin-converting enzyme inhibitor on plasma B-type natriuretic peptide levels in patients with acute myocardial infarction. *J Card Fail* 3:287-293, 1997.
- Planat-Bénard V¹, Menard C, André M, et al. Spontaneous cardiomyocyte differentiation from adipose tissue stroma cells. *Circ Res* 94: 223-229, 2004.
- Suzuki E, Fujita D, Takahashi, et al. Adipose tissue-derived stem cells as a therapeutic tool for cardiovascular disease. *World J Cardiol* 7:454-465, 2015.
- Nagata H, Li M, Kobayashi E, et al. Cardiac adipose-derived stem cells exhibit high differentiation potential to cardiovascular cells in C57BL/6 mice. *Stem cells Transl Med* 5:141-151, 2016.
- Nakagami H, Maeda K, Morishita R, et al. Novel autologous cell therapy in ischemic limb disease through growth factor secretion by cultured adipose-derived stromal cells. *Arterioscler Thromb Vasc Biol* 25:2542-2547, 2005.
- Planat-Benard V, Silvestre JS, Cousin B, et al. Plasticity of human adipose lineage cells toward endothelial cells: physiological and therapeutic perspectives. *Circulation* 109: 656-663, 2004.
- Miranville A, Heeschen C, Sengenès C, et al. Improvement of postnatal neovascularization by human

adipose tissue-derived stem cells. *Circulation* 110: 349-355, 2004.

26. Zhang Y, Yu S, Tuazon JP, et al. Neuroprotective effects of human bone marrow mesenchymal stem cells against cerebral ischemia are mediated in part by an anti-apoptotic mechanism. *Neural Regen Res* 14:597-604, 2019.

27. Ikebe C, Suzuki K. Mesenchymal stem cells for regenerative therapy: optimization of cell preparation protocols. *Biomed Res Int* 2014:951512, 2014.

28. Minteen D, Mahra KG, Rubin JP. Adipose-derived mesenchymal stem cell: biology and potential applications. *Adv Biochem Eng Biothchnol* 129:59-91, 2013.

29. De Ugante DA, Morizono K, Elbarbary A, et al. Comparison of multi-lineage cells from human adipose tissue and bone marrow. *Cell tissues organs* 174:110-119, 2003.

30. Fraser JK, Schreiber R, Strem B, et al. Plasticity of human adipose stem cells toward endothelial cells and

cardiomyocytes. *Nat Clin Pract Cardiovasc Med*. 2006; 3 (suppl 1): S33-37.

31. Raedschelders K, Ansley DM, Chen DD. The cellular and molecular origin of reactive oxygen species generation during myocardial ischemia and reperfusion. *Pharmacol Therap* 133:230-255, 2012.

32. Song H, Cha MJ, Song BW, et al. Reactive oxygen species inhibit adhesion of mesenchymal stem cells implanted into ischemic myocardium via interference of focal adhesion complex stem cells. *Stem Cells* 28:555-563, 2012.

33. Duscher D, Barrera J, Wong VW, et al. Stem cells in wound healing: the future of regenerative medicine? A mini-review. *Gerontology*. 2016; 62:216-225, 2016.

34. Aso K, Tsuruhara A, Takagaki K, et al. Adipose-derived mesenchymal stem cells restore impaired mucosal immune responses in aged mice. *PLOS ONE*. 11:e0148185, 2016.