

ORIGINAL ARTICLE

The Accuracy of Plain Radiography in Detection of Traumatic Intrathoracic Injuries

Maryam Abedi Khorasgani¹, Ali Shahrami¹, Majid Shojaee¹, Hossein Alimohammadi¹, Afshin Amini¹,
Hamid Reza Hatamabadi^{2*}

1- Emergency Department, Imam Hossein Hospital, Shahid Beheshti University of Medical Sciences, Tehran, Iran.

2- Safety promotion and injury prevention research center, Shahid Beheshti University of Medical Sciences, Tehran, Iran.

*Corresponding Author: Hamidreza Hatamabadi, Department of Emergency Medicine, Imam Hossein Hospital, Shahid Madani Avenue, Tehran, Iran.
Tel: +989123861683; Email: hhatamabadi@yahoo.com.

Received: July 2015; Accepted: September 2015

Abstract

Introduction: Rapid diagnosis of traumatic intrathoracic injuries leads to improvement in patient management. This study was designed to evaluate the diagnostic value of chest radiography (CXR) in comparison to chest computed tomography (CT) scan in diagnosis of traumatic intrathoracic injuries. **Methods:** Participants of this prospective diagnostic accuracy study included multiple trauma patients over 15 years old with stable vital admitted to emergency department (ED) during one year. The correlation of CXR and CT scan findings in diagnosis of traumatic intrathoracic injuries was evaluated using SPSS 20. Screening characteristics of CXR were calculated with 95% CI. **Results:** 353 patients with the mean age of 35.2 ± 15.8 were evaluated (78.8% male). Age 16-30 years with 121 (34.2%), motorcycle riders with 104 (29.5%) cases and ISS < 12 with 185 (52.4%) had the highest frequency among patients. Generally, screening performance characteristics of chest in diagnosis of chest traumatic injuries were as follows: sensitivity 50.3 (95% CI: 44.8 – 55.5), specificity 98.9 (95% CI: 99.5 – 99.8), PPV 97.8 (95% CI: 91.5 – 99.6), NPV 66.4 (95% CI: 60.2 – 72.03), PLR 44.5 (95% CI: 11.3 175.3), and NLR 0.5 (95% CI: 0.4 – 0.6). Accuracy of CXR in diagnosis of traumatic intrathoracic injuries was 74.5 (95% CI: 69.6 – 78.9) and its area under the ROC curve was 74.6 (95% CI: 69.3 – 79.8). **Conclusion:** The screening performance characteristics of CXR in diagnosis of traumatic intrathoracic injuries were higher than 90% in all pathologies except pneumothorax (50.3%). It seems that this matter has a great impact on the general screening characteristics of the test (74.3% accuracy and 50.3% sensitivity). It seems that, plain CXR should be used as an initial screening tool more carefully. **Keywords:** X-Rays; radiography, thoracic; tomography, X-ray computed; diagnostic techniques and procedures; thoracic injuries

Cite this article as: Abedi Khorasgani M, Shahrami A, Shojaee M, Alimohammadi H, Amini A, Hatamabadi H. The accuracy of plain radiography in detection of traumatic intrathoracic injuries. *Emergency*. 2016;4(4):184-187

Introduction:

Trauma is considered one of the major causes of mortality and permanent disability and the 4th cause of death behind cardiovascular diseases, cancer, and stroke (1, 2). Based on the statistics reported by the Iranian legal medicine organization, trauma and its consequences are the most common cause of mortality in Iran, as 75.9% and 74.1% of deaths were trauma related in 2003 and 2004, respectively (3). Among injuries due to trauma, chest trauma is responsible for 25% of deaths due to trauma and 50% of trauma-related deaths (4, 5). Diagnostic and treatment approaches may vary depending on the equipment of the center and the physician's decision. Physical examination and chest radiography (CXR) are the first steps in diagnosis and

treatment of multiple trauma patients. Accuracy of the diagnoses are widely dependent on the type of injury, time of arrival, and the method of diagnosis used (6). During the past decade, imaging diagnostic methods have improved and therefore, accuracy of pulmonary contusion, hemothorax, and pneumothorax diagnosis has increased. Yet, these methods do not have high specificity in ruling out chest and abdominal injuries (6). Chest computed tomography (CT) scan as the gold standard, can diagnose pulmonary contusion, hemothorax, pneumothorax, and rib fracture with high sensitivity (7). Rapid diagnosis of pneumothorax in patients with traumatic injuries, has led to improvement in patient management. Sensitivity of CT scan compared to CXR, is 100% compared to 42% in this regard (8-11). Yet, CXR is



still considered a useful and non-expensive method providing valuable information in the initial evaluation of trauma patients (9, 12). Considering global and national statistics on trauma, especially chest trauma and its high prevalence in the youth population, this study was designed to evaluate the diagnostic value of CXR in comparison to chest CT scan in diagnosis of traumatic intrathoracic injuries.

Methods:

In the present prospective diagnostic accuracy study, the value of CXR for diagnosis of traumatic intrathoracic injuries was evaluated in comparison to CT scan. The participants of this study included multiple trauma patients admitted to emergency department (ED) of Imam Hossein Hospital, Tehran, Iran, during March 2014 to February 2015. Multiple trauma patients over 15 years old with stable vital signs and those who had requests for both plain CXR and CT scan of chest were enrolled. Exclusion criteria consisted of unstable vital signs, penetrating trauma, pregnancy, and not undergoing CXR or chest CT scan. Demographic data of the patients, trauma mechanism and severity of injury based on injury severity score (ISS), and CXR and CT scan findings regarding presence of hemothorax, pneumothorax, pulmonary contusion, and fracture of rib, spine, and sternum were recorded in a checklist. Finally, the correlation of CXR and CT scan findings in diagnosis of chest traumatic injuries was evaluated. Physical examination, history, and data gathering for all patients was done by an emergency medicine resident in charge of trauma unit. Since the accuracy of CXR interpretation has been proved to be high for emergency medicine specialists (13), interpretation of CXR was done by a senior emergency medicine resident who was blind to the patients' clinical conditions. Chest CT scans were also reported by a radiologist blind to the clinical condition of the patients. Based on the Helsinki Declaration, patient data were kept confidential. None of the patients underwent CXR outside the treatment process and CT scan indications were determined based on the advanced trauma life support (ATLS) guidelines or the decision of in charge surgeon. Chest CT scan

Table 1: Baseline characteristics of the studied patients

Variables	Frequency (%)
Age (years)	
16-30	121 (34.28)
31-45	99 (28.05)
46-60	83 (23.51)
> 61	50 (14.16)
Sex	
Male	278 (78.8)
Female	75 (21.2)
Trauma mechanism	
Car passenger	102 (28.9)
Motorcycle rider	104 (29.5)
Pedestrian	90 (25.5)
Bicycle rider	3 (0.8)
Car rollover	25 (7.1)
Crush	5 (1.4)
Falling from > 3m	24 (6.8)
Injury severity*	
< 12	185 (52.4)
≥ 12	168 (47.6)

* Based on injury severity score (ISS).

was considered the gold standard. All CXRs were performed as posterior-anterior while the patient was in upright position.

Statistical analysis:

Sample size was calculated to be 87 cases considering 65% sensitivity of CXR in diagnosis of intrathoracic injuries, 10% desired precision, and 95% confidence interval (CI). SPSS 20 was used to analyze data. Correlation of two studied imaging was calculated using Spearman's rank correlation coefficient. Quantitative variables were reported as mean and standard deviation (SD) and qualitative ones as frequency and percentage. Sensitivity, specificity, positive and negative predictive value (PPV and NPV) and positive and negative likelihood ratio (PLR and NLR) of CXR in comparison with CT scan were calculated with 95% CI. Finally, area under the receiver operating characteristic (ROC) curve of CXR was calculated.

Results:

353 patients with the mean age of 35.2 ± 15.8 were eval-

Table 2: Screening performance characteristics of Chest X-ray in detection of traumatic intra-thoracic injuries

Characteristics	Type of injury (95% Confidence Interval)		
	Pneumothorax	Hemothorax	Contusion
Sensitivity	45 (32.1-58.4)	99 (97.2-99.8)	98.9 (96.8-99.8)
Specificity	98.6 (96.5-99.6)	29.8 (17.3-44.9)	7.59 (2.84-15.8)
PPV ¹	89.8 (85.9-92.8)	90.2 (86.5-93.1)	88.8 (74.1-83)
NPV ²	87.1 (70.2-96.4)	82.4 (56.6-96.2)	66.7 (29.9-92.5)
PLR ³	1.7 (1.43-2.26)	1.4 (1.17-1.7)	1.07 (1-1.14)
NLR ⁴	0.03 (0.11-0.83)	0.03 (0.009-0.11)	0.14 (0.036-0.56)

1. Positive predictive value; 2. Negative predictive value; 3. Positive likelihood ratio; 4. Negative likelihood ratio.



Table 3: Screening performance characteristics of Chest X-ray in detection of traumatic thoracic fractures

Characteristics	Type of fracture (95% confidence interval)		
	Rib	Sternal	Vertebral
Sensitivity	98.9 (3.3-20.7)	99.7 (98.4-100)	100 (98.9-100)
Specificity	57 (45.3-68.1)	40 (5.2-85.3)	22.7 (7.8-45.4)
PPV1	88.9 (84.8-92.2)	99.1 (97.5-99.8)	95.1 (92.3-97.1)
NPV2	93.8 (82.8-98.7)	66.7 (9.4-99.2)	100 (47.8-100)
PLR3	2.3 (1.78-2.26)	1.6 (0.8-3.4)	1.29 (1.03-1.62)
NLR4	0.019 (0.006-0.06)	0.007 (0-0.06)	0 (0-0)

1. Positive predictive value; 2. Negative predictive value; 3. Positive likelihood ratio; 4. Negative likelihood ratio.

uated (78.8% male). Table 1 shows the baseline characteristics of the patients. Age 16-30 years with 121 (34.2%), motorcycle riders with 104 (29.5%) cases and ISS < 12 with 185 (52.4%) had the highest frequency among patients. There was a significant correlation between the findings of two studied modalities ($\rho = 0.68$; $p < 0.001$). Screening characteristics of plain CXR in diagnosis of various traumatic intrathoracic injuries and fractures are presented in tables 2 and 3, respectively. Generally, screening performance characteristics of chest in diagnosis of chest traumatic injuries were as follows: sensitivity 50.3 (95% CI: 44.8 – 55.5), specificity 98.9 (95% CI: 99.5 – 99.8), PPV 97.8 (95% CI: 91.5 – 99.6), NPV 66.4 (95% CI: 60.2 – 72.03), PLR 44.5 (95% CI: 11.3 175.3), and NLR 0.5 (95% CI: 0.4 – 0.6). Accuracy of CXR in diagnosis of traumatic intrathoracic injuries was 74.5 (95% CI: 69.6 – 78.9) and its area under the ROC curve was 74.6 (95% CI: 69.3 – 79.8) (figure 1).

Discussion:

Based on the findings of the present study, CXR has low sensitivity in diagnosing traumatic intrathoracic injuries compared to CT scan. While its specificity and PLR is high and close to that of CT scan. Carrying out physical examination and plain CXR are

considered as the first step in diagnosing traumatic chest injuries. El Wakeel et al. in the study of 100 blunt chest trauma patients showed the higher sensitivity of CT scan compared to CXR in detection of intrathoracic injuries (7). As shown in table 2 and 3, the screening characteristics of CXR are higher than 90% in all pathologies except pneumothorax. It seems that this matter has a great impact on the general screening characteristics of the test. The pneumothorax cases, which were missed with CXR and diagnosed by CT scan are frequent and named occult pneumothorax, which usually are benign in nature. In a study, Eckstein et al. estimated the sensitivity of CXR to be 42% in diagnosis of pneumothorax (10). Diagnosis of hemothorax in CXR is difficult due to different reasons such as: the patient not being able to sit up, poor quality of the radiography, and improper preparation before radiography (being in sitting or upright position for at least 15 minutes before radiography performance). In the present study, sensitivity and specificity of CXR in diagnosis of pulmonary contusion were estimated to be 98.9 and 7.59%, respectively. These measures were 40 and 100%, respectively in the Eckstein study (10). Chest CT scan as the gold standard can diagnose pulmonary contusion, hemothorax, pneumothorax, and rib fracture with high sensitivity (8-12). Despite the efficiency and high diagnostic value of CT scan in trauma patients, few evidence based indications exist for using this method for all patients. Therefore, using it as a routine screening method is still a matter of debate (10). Char-doli et al. believed that use of chest CT scan as an initial screening tool in trauma patients with stable hemodynamics can change the patient management and outcome (14). Although CT scan can be very useful for evaluation of chest trauma patients, especially those with lung parenchyma injuries, hemothorax, and pneumothorax, the nephrotoxicity due to contrast material, cumulative dose of radiation, and the high cost of CT scan are problems that cannot be overlooked (6). On the other hand, performing plain CXR and then CT scan to confirm the results doubles the problem. Therefore, a decision on whether all chest trauma patients with stable hemodynamics should undergo CT scan from the start cannot be made yet. It seems that making a decision based on a combination of physical examination, history, trauma mechanism, as well as imaging can be very helpful in this

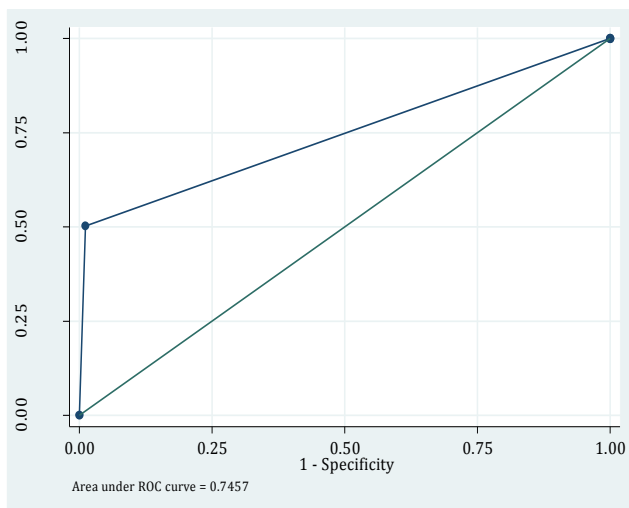


Figure 1: Receiver operating characteristics (ROC) curve of chest X-ray in comparison with computed tomography scan



regard. The new methods suggested for chest trauma evaluation, tend to use scoring systems and clinical decision rules to some extent (15, 16). It seems that routine use of CXR based on ATLS protocol for all multiple trauma patients is questionable. In this regard, new clinical decision rules similar to NEXUS (16) and TIRC (15) that have been designed for clinical triage of patients in need for chest imaging, can be implemented after validation studies.

Conclusion:

Based on the findings of the present study, the screening performance characteristics of CXR in diagnosis of traumatic intrathoracic injuries were higher than 90% in all pathologies except pneumothorax. It seems that this matter has a great impact on the general screening characteristics of the test (74.3% accuracy and 50.3% sensitivity). It seems that, plain CXR should be used as an initial screening tool for all the chest trauma patients more carefully.

Acknowledgment:

The authors would like to thank all the staff of Trauma Unit of Imam Hossein Hospital that helped carry out this study. This article is extracted from the thesis of Dr. Abedi Khorasgani to earn her specialist degree in emergency medicine, registered under the number 312 in the research and technology department of Shahid Beheshti University of Medical Sciences.

Conflict of interest:

None

Funding support:

None

Authors' contributions:

All authors passed four criteria for authorship contribution based on recommendations of the International Committee of Medical Journal Editors.

References:

1. Khaji A, Ghodsi SM, Eftekhari B, Karbakhsh M. Trauma research in Iran: a report of the Sina Trauma Data Bank. *Archives of Iranian medicine*. 2010;13(1):17-20.
2. Mayberry JC. Imaging in thoracic trauma: the trauma surgeon's perspective. *Journal of thoracic imaging*. 2000;15(2):76-86.
3. Brink M, Kool D, Dekker H, et al. Predictors of abnormal chest CT after blunt trauma: a critical appraisal of the literature. *Clinical radiology*. 2009;64(3):272-83.
4. Kaewlai R, Avery LL, Asrani AV, Novelline RA. Multidetector CT of Blunt Thoracic Trauma 1. *Radiographics*. 2008;28(6):1555-70.
5. Scaglione M, Pinto A, Pedrosa I, Sparano A, Romano L. Multidetector row computed tomography and blunt chest trauma. *European journal of radiology*. 2008;65(3):377-88.
6. Livingston DH, Shogan B, John P, Lavery RF. CT diagnosis of rib fractures and the prediction of acute respiratory failure. *Journal of Trauma and Acute Care Surgery*. 2008;64(4):905-11.
7. El Wakeel MA, Abdullah SM, El Khalek RSA. Role of computed tomography in detection of complications of blunt chest trauma. *Menoufia Medical Journal*. 2015;28(2):483.
8. Guerrero-López F, Vázquez-Mata G, Alcázar-Romero PP, Fernández-Mondéjar E, Aguayo-Hoyos E, Linde-Valverde CM. Evaluation of the utility of computed tomography in the initial assessment of the critical care patient with chest trauma. *Critical care medicine*. 2000;28(5):1370-5.
9. Renton J, Kincaid S, Ehrlich P. Should helical CT scanning of the thoracic cavity replace the conventional chest x-ray as a primary assessment tool in pediatric trauma? An efficacy and cost analysis. *Journal of pediatric surgery*. 2003;38(5):793-7.
10. Eckstein M, Henderson SO. *Thoracic Trauma in Rosen's Emergency Medicine*. Philadelphia, Mosby Elsevier. 2010.
11. Exadaktylos A, Benneker L, Jeger V, et al. Total-body digital X-ray in trauma: an experience report on the first operational full body scanner in Europe and its possible role in ATLS. *Injury*. 2008;39(5):525-9.
12. Traub M, Stevenson M, McEvoy S, et al. The use of chest computed tomography versus chest X-ray in patients with major blunt trauma. *Injury*. 2007;38(1):43-7.
13. Safari S, Baratloo A, Negida AS, Taheri MS, Hashemi B, Selkisari SH. Comparing the Interpretation of Traumatic Chest X-Ray by Emergency Medicine Specialists and Radiologists. *Archives of trauma research*. 2014;3(4).
14. Chardoli M, Hasan-Ghaliiae T, Akbari H, Rahimi-Movaghar V. Accuracy of chest radiography versus chest computed tomography in hemodynamically stable patients with blunt chest trauma. *Chinese Journal of Traumatology*. 2013;16(6):351-4.
15. Forouzanfar MM, Safari S, Niazazari M, et al. Clinical decision rule to prevent unnecessary chest X-ray in patients with blunt multiple traumas. *Emergency Medicine Australasia*. 2014;26(6):561-6.
16. Rodriguez RM, Anglin D, Langdorf MI, et al. NEXUS chest: validation of a decision instrument for selective chest imaging in blunt trauma. *JAMA surgery*. 2013;148(10):940-6.

