

## DOUBLE RENAL ARTERY IN HUMAN CADAVERS: A CASE REPORT

### *ARTÉRIA RENAL DUPLA EM CADÁVERES HUMANOS: RELATO DE CASO*

**Dayane Kelly SABEC-PEREIRA<sup>1</sup>; Talita de Melo CAMPOS<sup>2</sup>;  
Octavio Binvignat GUTIERREZ<sup>3</sup>; Fabiano Campos LIMA<sup>4</sup>; Ricardo de Mattos SANTA RITA<sup>4</sup>;  
Kleber Fernando PEREIRA<sup>4</sup>**

1. PhD Student. Human and Comparative Anatomy Laboratory, Federal University of Goiás, Jataí, Brazil; 2. Graduation Student. Human and Comparative Anatomy Laboratory, Federal University of Goiás, Jataí, Brazil; 3. Professor, PhD. Human and Comparative Anatomy Laboratory, Universidad de La Frontera-Chile; 4. Professor, PhD. Human and Comparative Anatomy Laboratory, Federal University of Goiás, Jataí, Brazil. kpereiraufg@gmail.com

**ABSTRACT:** Two renal arteries supply the human kidneys: one to the right kidney and another to the left kidney, both branches of the abdominal aortic. Renal artery duplication is an anatomical variation, which is a normal flexibility of the topography and morphology in body structures. Functionally, it does not impair the body, as the blood supply is vital to tissue survival. In this context, the case study has great importance, once knowing the variations of the renal vessels assist when structuring surgeries and radiological studies in humans. Variations in vascular anatomy are often found in humans. Several authors characterize it: the prevalence of multiple vessels occurs in approximately 20-50% of cases. This is an observational study; we aimed to describe the anatomical variations concerning the duplicity of the renal artery in human cadavers, focusing on possible implications to clinical and surgical procedures. We dissected and analyzed four urinary block systems in adult cadavers, male, with focus on the vascularization. In these, two right kidneys present double renal arteries. Thus, we can infer that this knowledge can be used to improve surgical interventions, such as transplants.

**KEYWORDS:** Kidney. Morphology. Double renal artery.

### INTRODUCTION

The human kidney is a paired organ located posterior to the visceral peritoneum. At its medial edge, there is a vertical fissure called the renal hilum, composed by ureter, renal artery and vein, constituting the renal pedicles (FERREIRA et al., 2014; DIÉGUEZ et al., 2016).

Bredel performed the first anatomical studies on renal vascular segmentation in 1901, confirming the findings from Hyrtl, in 1882. The first study of renal vascularization was conducted by Fue Berenger (1470-1530), and the acknowledgment of this anatomical data was credited to John Honter, in 1794 (SKANDALAKIS; McCLUSKY, 2006). These findings are of fundamental importance in the anatomical-clinical understanding of the anatomical variations of the urinary system.

According to the anatomical descriptions, each kidney is supplied by a single renal artery, originated in the abdominal aorta, between the 1st and 2nd lumbar levels (OZKAN et al., 2006). Renal artery duplicity can be defined as of normal flexibility in its topography and morphology, with no apparent functional changes (SANUDO; VAZQUEZ; PUERTA, 2003). This variation is, presumably, clinically silent, only being discovered

when surgical procedures are needed, by imaging procedures and/or autopsy.

Variations in vascular anatomy are often found in men and are characterized by several authors: the prevalence of multiple vessels occurs in 20-50% of cases (BORDEI; SAPTE; ILIESCU, 2004). However, some cases of renal artery variations are rare, as described by Isoda et al., (2002), where a supplementary artery from an opposing renal artery crosses the aorta with direction to the contralateral kidney. On that note, this case study presents big importance, because this information about the renal vessels variations helps structuring surgical and radiological studies (SEBEN et al., 2010; DIÉGUEZ et al., 2016).

The literature consulted reports that this knowledge is important in treatments and research of various diseases, such as: renal trauma, renal vascular hypertension, embolization of renal artery, and surgical methods such as: angioplasty or vascular reconstruction for congenital and acquired lesions, aneurysm, abdominal aortic surgery, conservative renal surgery or radical and kidney transplantation (PEREIRA-CORREIA et al., 2009). Due to the wide range of morphological and numerical variations present in the renal hilum; to the constant development of imaging techniques and transplantation, the interest of anatomists in such studies have been increasing (KUMAR, 2012).

These numerical variations, concerning the origin of the renal arteries in humans, are also important to kidney transplants and other diseases, as they can be compared to the normal morphology. In surgical and radiological procedures, the anatomical description of the renal vasculature is necessary to avoid errors concerning these variations (KHAMANARONG et al., 2004; MARTINEZ-MIER, et al., 2012).

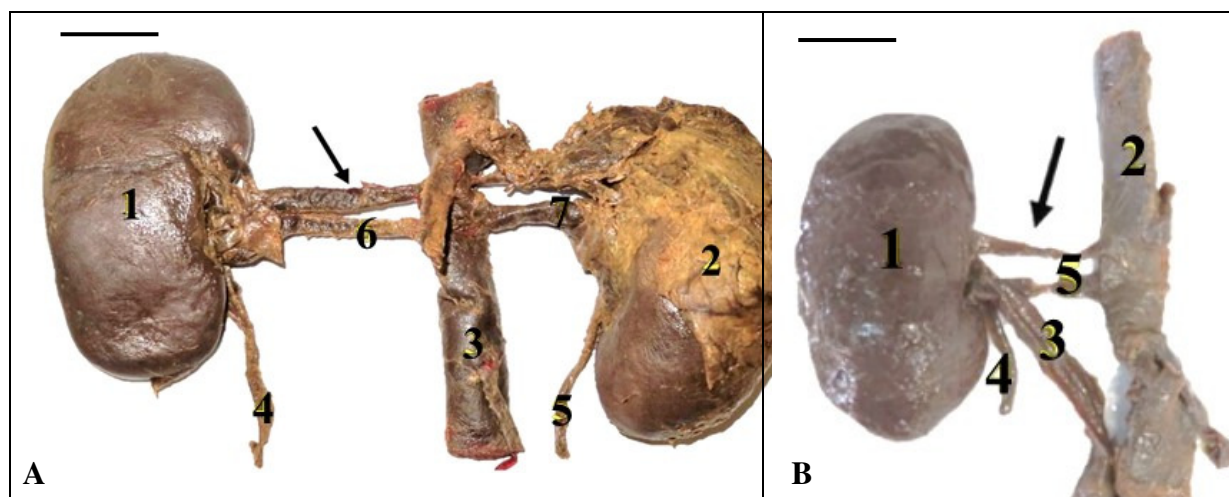
We aimed to report two cases of renal artery duplicity in human cadavers, focusing on clinical and surgical implications.

## CASE REPORT

To the present study, we used 04 urinary block systems, removed from adult human cadavers, from the collection of the Human and Comparative Anatomy Laboratory, of the Federal University of Goiás – Jataí. They were fixed and preserved in

glycerin. We dissected the renal blocks, which had already been removed from the cadavers, and identified both the renal hilum (an oval area in the middle of the medial border, where the renal artery arrives) and the renal vein (where lymphatic vessel and ureter arise). The renal arteries are branches of the abdominal aorta, allowing its partial removal. We measured the length, width and thickness of the kidneys and the length of the double arteries, from the abdominal aorta to the renal hilum, using precision calipers. We photographed the structures with the camera Canon Power-Shot SX270 HS.

We observed the presence of double renal artery in two right kidneys (Figures 1A and 1B). The dimensions of the right kidney on the first urine block were 9.4 cm long, 5.9 cm wide, 2.9 cm thick, and the length of the arteries were 4.1 cm. For the second block, the dimensions of the right kidney were 10.6 cm long, 5.0 cm wide, 3.2 cm thick, and the length of the arteries measuring 5.7 cm.



**Figure 1.** (A) Frontal view of the first kidney block, from an adult human cadaver, contemplating the kidney (1), abdominal aorta (2), renal vein (3), ureter (4), the right renal artery (5) and the double renal artery (arrow). (B) Frontal view of the second kidney block, from an adult human cadaver, contemplating the right kidney (1), left kidney (2), abdominal aorta (3), right ureter (4), left ureter (5), right renal artery (6), double renal artery (arrow) and the left renal artery (7). Scale 2,5 cm.

## DISCUSSION

An anatomical variation is defined by any difference in the morphology of human or animal body, without impairing the function, unlike malformations, which causes significant physiological damage, sometimes incompatible to life (SANUDO; VAZQUEZ; PUERTA, 2003). Moreover, anatomical variations may be related to predispositions of certain illnesses, found in clinical examination (BORDEI; SAPTE; ILIESCU, 2004).

The adult human kidney is around 11 to 13 cm long, 3 cm thick and 5 cm wide. It occupies,

longitudinally, the space between the 12th thoracic and the 3rd lumbar vertebrae. The right kidney is positioned nearly 1.5 cm lower than the left, due to the presence of the liver. The left kidney is slightly longer, thinner and closer to the median plane, compared to the right kidney. (NETO; BRITO; 2001; ROA; BARRAGÁN, 2011). The dimensions we observed corroborates these morphological patterns: the right kidney from the first block was 9.4 cm long, 5.9 cm wide and 2.9 cm thick; the right kidney from the second block was 10.6 cm long, 5.0 cm wide and 3.2 cm thick.

The length of the double renal arteries was measured from the abdominal aorta to the renal hilum. The right renal artery, from the first block, was 4.1 cm long; the one from the second block was 5.7 cm long. When the renal artery morphometry was analyzed, Diéguez et al. (2016) found that the right renal artery presented a greater length, with a mean of  $3.4 \pm 0.9$  cm, while the left renal artery had a mean of  $2.8 \pm 0.9$  cm. This morphometric data does not refer to anatomical variation, such as duplicity, only to the morphometry. To them, the morphometric parameters are of vital importance in the effective planning process of a kidney transplant surgery.

Complex renal vascularization remains a problem that can affect the prognosis of transplantation, increasing vascular complications. The various challenges in kidney transplant surgery result of anatomical variations, such as multiple renal arteries, which occur in 12-30% of the kidneys that were transplanted and observed by Martinez-Mier et al. 2012. The presence of renal double artery was investigated before in a study about renovascular hypertension, to see if its prevalence causes complications in patients (EBRI et al., 1990).

Some methods such as renal angiography can be obtained through multidetector computed tomography (MDCT), which is now considered a non-invasive, fast and very important tool in the study of vascular anatomy and its variations, such as renal artery duplicity. This method is basic to pre-surgical evaluations, mainly in interventions such as partial nephrectomy, laparoscopy and renal transplantation (STOISA et al., 2009).

The variations in the topography and flexibility of renal arteries are present in humans and animals. There are veterinary reports related to the duplication of the renal artery in donkeys (NETO, S.; NETO, J. P., 1995), american minks (WILAND; INDYKIEWICZ, 1999), dogs (OLIVEIRA; GUIMARAES, 2007; ALONSO; ABIDU-FIGUEIREDO, 2008), goats (ABIDU-FIGUEIREDO et al., 2009), cats (PESTANA et al., 2011) and rabbits (ALMEIDA et al., 2013).

Another common variant is the pre-hilar arterial bifurcation, which has fundamental

importance in renal donor patients because, for a surgical procedure, a minimum length of 2cm in the main renal artery is necessary before the bifurcation, to guarantee an adequate anastomosis. As previously described, anatomical variations of renal arteries are important in the preoperative assessment of patients undergoing nephrectomy for kidney donation, the technique of choice is laparoscopy and the risk of hemorrhage from vascular injury can be substantially reduced if there is prior knowledge about the preoperative radiological evaluation of renal angiography of the donor using non-invasive and effective multidetector computed tomography in the diagnosis (BORDEI; APTE; ILIESCU, 2004; STOISA et al., 2009). In addition, the angiotomography technique has been used to detect the quantity and route of renal arteries, replacing conventional arteriography in evaluation, vascular anatomy study and diagnosis of renal vascular pathologies (PALMIERI et al., 2011).

The presence of multiple renal arteries requires greater caution in surgical and radiological procedures, because its presence can result in modifications of the surgical procedures. If homeostatic controls of the renal arteries are necessary, they increase the complexity of the surgery, besides the high correlation with renal pathologies, compared to kidneys supplied by a single artery (FOX; YALIN, 1979; SAMPAIO; PASSOS, 1992; LÓPEZ et al., 2014). Still on the kidney transplantation topic, the rate of stenosis in multiple renal arteries is also higher. (BENEDETTI et al., 1995).

Given the importance and relevance of this anatomic arterial variation, its knowledge must be carried out in the execution of surgical, experimental and radiological procedures, because the existence of multiple arteries is an aggravating factor for the conduction of correct procedures.

## ACKNOWLEDGEMENTS

We thank Letícia Menezes de Freitas for her support.

---

**RESUMO:** Os rins são supridos por duas artérias renais, uma para o rim direito e outra para o rim esquerdo, ramos da aorta abdominal. A duplicidade de artéria renal é uma variação anatômica definida como uma flexibilidade normal na topografia e morfologia das estruturas do corpo, que em termos funcionais não há prejuízo do órgão, uma vez que a irrigação arterial do mesmo é um fator vital para a sobrevivência dos tecidos. Neste contexto, o estudo de caso tem grande importância, sendo que o conhecimento das variações dos vasos renais auxilia na estruturação da anatomia cirúrgica e em estudos radiológicos e clínicos para humanos. Às variações na anatomia vascular são frequentemente encontradas, no homem, é caracterizada por vários autores, com uma prevalência de vasos múltiplos que ocorre em cerca

de 20-50% dos casos. Este trabalho trata-se de um estudo observacional, cujo objetivo é descrever variações anatômicas de duplicidade da artéria renal em cadáveres humanos, com enfoque nas possibilidades de implicação clínico-cirúrgica desta variação anatômica. Foram dissecados e analisados 04 blocos de sistema urinário em cadáveres adultos, do sexo masculino, com enfoque na vascularização. Observou-se que destes blocos, dois rins direitos apresentavam artérias renais duplas. Sendo assim, podemos inferir que o conhecimento das variações anatômicas em humanos pode servir como subsídio para aprimoramento de intervenções cirúrgicas como em transplantes e cirurgias renais.

**PALAVRAS-CHAVE:** Rim. Morfologia. Dupla artéria renal.

---

## REFERENCES

- ABIDU-FIGUEIREDO, M.; ROSA, M. S.; PASSOS, N. C.; SILVA, B. X.; SCHERER, P. O. Artéria renal com dupla origem na porção abdominal da aorta em caprino. **Acta Veterinária Brasilica**, v. 3, n. 1, p. 38-42, 2009.
- ALMEIDA, B. B.; ARAÚJO-BARRETO, U. H.; COSTA, O. M.; ABIDU-FIGUEIREDO, M. Double renal artery in rabbit. **Bioscience Journal**, v. 29, n. 5, p. 1295-1299, 2013.
- ALONSO, L. S.; ABIDU-FIGUEIREDO, M. Artéria renal dupla originando da aorta em cão: relato de caso, **Semina: Ciências Agrárias**, v. 29, n. 1, p.185- 188, 2008. <https://doi.org/10.5433/1679-0359.2008v29n1p185>
- BENEDETTI, E.; TROPPEMAN, C.; GILLINGHAM, K.; SUTHERLAND, DE.; PAYNE, W. D.; DUNN, D. L.; MATAS, A. J.; NAJARIAN, J. S.; GRUSSNER, R. W. Short- and long-term outcomes of kidney transplants with multiple renal arteries. **Annals of surgery**, v. 221, n. 4, p. 406, 1995. <https://doi.org/10.1097/0000658-199504000-00012>
- BORDEI, P.; SAPTE, E.; ILIESCU, D. Double renal arteries originating from the aorta. **Surg Radiol Anat.** v. 26, n.6, p. 474-479, 2004. <https://doi.org/10.1007/s00276-004-0272-9>
- DIÉGUEZ, Y. F.; PEREZ, J. R. M.; GONZALEZ, R. G.; LOPEZ, Y. C.; PEREZ, I. C. P. Variantes anatómicas de la arteria renal. In: CONVENCION INTERNACIONAL VIRTUAL DE CIENCIAS MORFOLÓGICAS, 2016, La Habana, Anais... Cuba: Sociedad Cubana de Ciencias Morfológicas, 2016. p. 1-12.
- EBRI, B.; CABEZA, F.; ILARIO, J.; ROMERO, D. Doble sistema arterial renal, como causa de hipertension arterial. In: **REUNIÓN EXTRAORDINARIA DE LA SOCIEDAD DE MEDICINA INTERNA DE ARAGÓN, NAVARRA, LA RIOJA Y PAÍS VASCO**, 1990. Zaragoza, Anais... Espanha: Departamento de Medicina Interna, Hospital “Miguel Servet”, 1990. p. 61.
- FERREIRA, M. R. S.; SILVA, F. A.; REIS, R. S.; OLIVEIRA, R. A.; PEREIRA, N. T. L.; GALVÃO, A. P. O.; MAGALHÃES, C. P. Estudo das variações anatômicas em artérias e veias renais. In: CONGRESSO DE ANATOMIA, 26., 2014. Curitiba, Anais Eletrônicos... Curitiba: UFP, 2014.
- FOX, M.; YALIN, R. Renal transplantation with multiple arteries. **British Journal of Urology**, v. 51, n. 5, p. 333-336, 1979. <https://doi.org/10.1111/j.1464-410X.1979.tb02879.x>
- ISODA, H.; SAITOH, M.; ASAKURA, T.; AKAI, M.; ITAGAKI, Y.; HA-KAWA, S. K.; HARIMA, K.; SAWADA, S. An unusual arterial supply of the kidney from the opposite renal artery. **Computerized medical imaging and graphics**, v. 26, n. 5, p. 353-355, 2002. [https://doi.org/10.1016/S0895-6111\(02\)00021-6](https://doi.org/10.1016/S0895-6111(02)00021-6)
- KHAMANARONG, K.; PRACHANEY, P.; UTRARAVICHIAN, A.; TONG-UN, T.; SRIPAORAYA, K. Anatomy of renal arterial supply. **Clinical Anatomy**, v. 17, n. 4, p. 334-336, 2004. <https://doi.org/10.1002/ca.10236>

KUMAR, G. P. Bilateral Superior Accessory Renal Arteries - Its Embryological Basis and Surgical Importance – A Case Report. **Journal of Clinical Case Reports**, v. 2, n. 1, 2012. <https://doi.org/10.4172/2165-7920.1000e105>

LÓPEZ, V. C. M.; MÉNDEZ, P. R. C.; LABRADA, R. L.; MAGADÁN, C. E. F.; FERNÁNDEZ, G. T.; JIMÉNEZ, O. M. Variantes anatómicas de las arterias polares del riñón. **Revista Médica Electrónica**, v. 36, p. 720-728, 2014.

MARTÍNEZ-MIER, G.; LÓPEZ-MENDOZA, O.; MÉNDEZ-LÓPEZ, M. T.; BUDAR-FERNÁNDEZ, L. F.; ÁVILA-PARDO, S. F.; GONZÁLEZ-VELÁZQUEZ, F. Resultados del trasplante renal con arterias renales múltiples en Veracruz, México. **Nefrología (Madrid)**, v. 32, n. 6, p. 843-845, 2012.

OLIVEIRA, F. S.; GUIMARÃES, G. C. Duplicidade da artéria renal em cão. **Ciencia rural**, v. 37, n. 6, p. 1817-1819, 2007. <https://doi.org/10.1590/S0103-84782007000600051>

OZKAN, U.; ODUZKURT, L.; TERCAN, F.; KIZILKILIÇ, O.; KOÇ, Z.; KOCA, N. Renal artery origins and variations: angiographic evaluation of 855 consecutive patients. **Diagnostic and interventional Radiology**, v. 12, n. 4, p. 183, 2006.

PALMIERI, B. J.; PETROIANU, A.; SILVA, L. C.; ANDRADE, L. M.; ALBERTI, R. L. Estudo do padrão arterial de 200 pedículos renais por meio de angiotomografias. **Revista do Colégio Brasileiro de Cirurgiões**, v. 38, n. 2, p. 116-121, 2011. <https://doi.org/10.1590/S0100-69912011000200009>

NETO, M. P.; BRITO, F. **Urgências em Geriatria**. São Paulo: Atheneu, 2001.

PEREIRA-CORREIA, J. A.; VALENTIM, L. S.; CASTRO, K. F.; GASQUE, G. P.; ROSARIO, C. A. F.; PRINZ, R. A. D. Analysis of renal hilum extraparenchymal structures in Brazilian adult human cadavers. **European Journal of Anatomy**, v. 13, n. 3, p. 145-153, 2009.

PESTANA, F. M.; ROZA, M. S.; HERNANDEZ, J. M. F.; SILVA, B. X.; ABDIDU-FIGUEIREDO, M. Double renal artery in cat. **Semina: Ciências Agrárias**, v. 32, n. 1, p. 327-332, 2011. <https://doi.org/10.5433/1679-0359.2011v32n1p327>

ROA, C. O.; BARRAGÁN, J. M. M. Variaciones anatómicas de la arteria renal y sus implicaciones en la práctica clínica y quirúrgica. **Morfología**, v. 3, n. 3, p. 18-27, 2011.

SAMPAIO, F. J. B.; PASSOS, M. A. R. F. Renal arteries: anatomic study for surgical and radiological practice. **Surgical and Radiologic Anatomy**, v. 14, n. 2, p. 113-117, 1992. <https://doi.org/10.1007/BF01794885>

SANUDO, J.; VAZQUEZ, R.; PUERTA J. Meaning and clinical interest of the anatomical variations in the 21st century. **European Journal of Anatomy**, v. 7, n. 1, p. 1-3, 2003.

SEBBEN, G. A.; ROCHA, S. L.; QUIDIGNO, E. A.; CALIARI, E. A. S.; CALIARI, H. A. S. Variações das artérias renais: estudo anatômico em cadáveres. **Revista do Médico Residente**, v. 13, n. 4, p. 245-250, 2011.

NETO, E. J. S.; NETO, J. P. Número e distribuição dos elementos vasculares, arteriais e venosos, no hilo renal de jumentos nordestinos (*Asinus asinus*, Gray 1824, ex. Fritsch 1775). **Revista da FZVA**, v. 2, n. 1, p. 41-61, 1995.

SKANDALAKIS, J. E.; McCLUSKY, D. A. **Skandalakis' surgical anatomy**. Washington: McGraw-Hill, 2006.

STOISA, D.; GALIANO, F. E.; QUARANTA, A.; VILLAVICENCIO, R. L. Estudio vascular renal por TC multidetector de 64 canales. **Revista Argentina de Radiología**, v. 73, n. 1, p. 843-5, 2009.

WILAND, C.; INDYKIEWICZ, P. Multiple renal arteries (Aa. renales) in mink and dog. **Electronic Journal of Polish Agricultural Universities**, v. 2, n. 2, p. 12-17, 1999.