



RESEARCH ARTICLE

The Essential Pheromonal Elements of Preputial Glands of Castrated and Testosterone-Treated Mice

Merza H. Homady¹, Ali A. Majeed², Maysoon T. Al-Haideri³, Mustafa T. Younis⁴

¹Department of Biomedical Sciences, Cihan University-Erbil, Kurdistan Region-Iraq, ²Department of Pathological Analyses, Faculty of Sciences, Kufa University, Kufa, Iraq, ³Department of Physiotherapy, Cihan University-Erbil, Kurdistan Region, Iraq, ⁴Department of General Biology, Cihan University-Erbil, Kurdistan Region, Iraq

ABSTRACT

The present study investigated the effects of both castration and treatment of castrated subjects with 0.1 ml of 50 µg/kg/day of testosterone at 3 weeks of age for 6 weeks on the pheromonal and histological structure of male mice preputial gland. The preputial gland results from the control intact group showed that six essential pheromonal compounds are present, whereas the glandular structure revealed well-developed acini with basement membrane and connective tissue around most of them. These findings also showed that castration has deleterious effects on the essential pheromonal compounds which are reduced to two compounds only (the α -Farnesene and 1-Tetradecanol) as well as the histological sections from such subject appeared many atrophied vacuolated acini. On the other hand, the treatment of castrated animals with such dose of testosterone did not show any marked effects on the essential pheromonal compounds, but it was able to restore the activities of acinar development as showed by many hypertrophied alveoli.

Keywords: Testosterone, pheromones, histology, preputial, castration

INTRODUCTION

Chemical communications are important in the social lives of many species of mammals; several of these chemicals are referred to as pheromones.^[1,2] The term pheromone was created and described based on findings in insects, but whether the original definition can be applied to mammals which is still discussed.^[3] When mice are stressed, they emit a specific odor into the air; because this stress-related odor causes anxiety in the other mice, it is likely that some anxiogenic molecules are present in this odor.^[2,4]

Pheromones have been characterized to generate either signaling activity that results in a rapid change in motor activity by the recipient, which on detection rapidly initiate behavior such as aggression or fear^[5] or priming pheromones that trigger rather slower neuroendocrine or endocrine changes in the recipient.^[6,7] Pheromones are mainly found in the preputial glands and urine of male mice, according to numerous studies.^[8] It is very well known that many of the volatile plant compounds normally found in insect natural habitats alter the perception from their own pheromone when introduced separately as a background to pheromone. Olfactory communication is key for insects and rodents since it aids in the identification and location of critical resources including a food source, a mate, and threat.^[9-11] Chemical information exchanges are therefore not only crucial to insects or rodents but also to the functioning of the species network that makes

up a community. Once released into the atmosphere, these ecologically relevant signals and cues are carried by airflows, diluted, and mixed with other volatile organic compounds to form a complex and changing olfactory landscape.^[12,13]

The preputial glands are androgen-dependent organ; Testosterone is the most well-known androgen, which is derived from Dihydrotestosterone. Furthermore, the activity of the preputial glands is reliant on the Melanocortin 5-Receptor (MC5R), that is, one of the Melanocortin Receptors (MCRs) are a family of five G protein-coupled receptors (GPCRs; MC1R–MC5R) expressed in varied tissues, each of which serves a distinct physiological function.^[14,15] Because the preputial gland is a vital gland that plays an important role in the development of behavior-modifying “pheromones” in

Corresponding Author:

Merza H. Homady, Department of Biomedical Sciences, Cihan University-Erbil, Kurdistan Region-Iraq.
E-mail: merza.homady@cihanuniversity.edu.iq

Received: June 20, 2022

Accepted: July 18, 2022

Published: August 20, 2022

DOI: 10.24086/cuesj.v6n2y2022.pp36-40

Copyright © 2022 Merza H. Homady, Ali A. Majeed, Maysoon T. Al-Haideri, Mustafa T. Younis. This is an open-access article distributed under the Creative Commons Attribution License (CC BY-NC-ND 4.0).

mice, it is significantly influenced by a variety of hormones and medicinal herbs.

Up to our knowledge, there was no work that has done on gas chromatography and mass spectrometry (GC-MS) analysis the histological structure and major pheromonal molecules of this pheromone producing glands. The present research is aimed to investigate the effects of both castration and treatment of the castrated subjects with testosterone on the histological structure and pheromonal compounds of the preputial gland.

METHODOLOGY

Chemical (Hormone) Preparation

All preparations administration by injection was given as "oily solution." The oil vehicle used for these injections was a combination of one part of ethyl oleate (BHD, Poole, Dorset) to four parts of Arachis oil (Hopkin and Williams, Essex). Almond oil was contrasted with this preparation as there are suggestions that Arachis oil have estrogen action.^[16] Hormones were obtained in crystalline form as free alcohols from Sigma Ltd. (London). Preparation of a compound for injection consisted of weighing the required amount of steroid, dissolving it in ethanol (Analar grade from BDH, Poole, Dorset) and making the resultant solution up to a volume of 100 ml with oil vehicle. As 0.1 ml was generally injected, calculations were based on the quantity of material in this volume.

Preparation of testosterone solution: One tablet of testosterone (50 mg) (Testosterone-Austrian) was taken and followed by the same procedure mentioned above, to get a concentration of 50 µg/ml testosterone. Injections were performed using all – tuberculin, Lure filling syringe (Rocket, London) all syringes and other glass were cleaned before use in Decon 90. The needle was 23 × 1 gauge (Arnold R. Horwell Ltd. London). Hormonal solutions were usually injected daily for 42 days into the thigh muscle (alternating legs on consecutive days).

Experimental Design

Tuck Ordinary (TO) strain albino mice have been bred and kept in the animal house unit of Kufa University's Faculty of Sciences under controlled circumstances of 12 h light: 12 h darkness. The subjects were retained in plastic cages. Sawdust bedding was used, as well as food and water were provided on an ad libitum basis. Animals housed in groups of comparable age (3 weeks) were assigned to the categories listed below:

- Intact male mice received tap-water as a positive control, ($n = 7$)
- Castrated animals were given tap water as experimental control, ($n = 7$)
- Castrated subjects delivered daily with 0.1 ml of 50 µg/kg/day of testosterone from 3 weeks of age for 6 weeks.

Castration

Experimental mice were anesthesia before surgery with (500 mg ketamine + 20 mg 4/1 xylazine) for 15 min. The basic operation in these experiments was bilateral castration. After inducing general anesthesia with ketamine and Xylazine and

disinfecting the scrotum with 75% alcohol, a small midline incision was made, the spermatic vessels were tied with 4.0 silk sutures, and the testes were removed. The incision was then closed with 4.0 silk sutures. Mice were transferred on recovery to clean cages.

Assessment of Pheromones

Before extraction, the glands are thawed at room temperature and the yellowish secretion is gathered into a clear vial by squishing, then the secretion is collected and added 1.5 ml of dichloromethane into the vial, and after 24 h, the supernatant is removed and the remaining solution stored at 0°C until GC-MS analysis within 1 week.^[17] Conjunction of both GC-MS was used.

Histological Analysis

Mice were killed by the end of the experiment by over dose of ketamine and xylazine, and the preputial glands were used for histological investigation under light microscope. The histological methods used have been processed according to Bancroft.^[18]

RESULTS

Biochemical Analysis

The results of Table 1 showing the essential pheromonal compounds present in the preputial gland of intact control mice were six compounds, whereas these compounds are reduced in castrated animals to two only (α -Farnesene and 1-Tetradecanol). The treatment of castrated subjects with 0.1 ml of 50 µg/kg/day of testosterone appeared two essential compounds only (1-Tetradecanol acetate and 1-Hexadecanol).

Histology of the Preputial Glands

The intact control group's preputial gland was observed under the microscope and revealed normal structure [Figures 1 and 2]. The gland is covered with thick connective tissue capsule, from which trabeculae protrude into the interior, partitioning the parenchymatous tissues into lobes and lobules at varied stages of growth. Many acini have hypertrophied with healthy oval-shaped nuclei and numerous normal cytoplasmic organelles. The acini are bordered with basal cells that are more evident. The gland has a wide excretory duct which drains into the preputial cavity and has a broad lumen lined by stratified squamous epithelium.

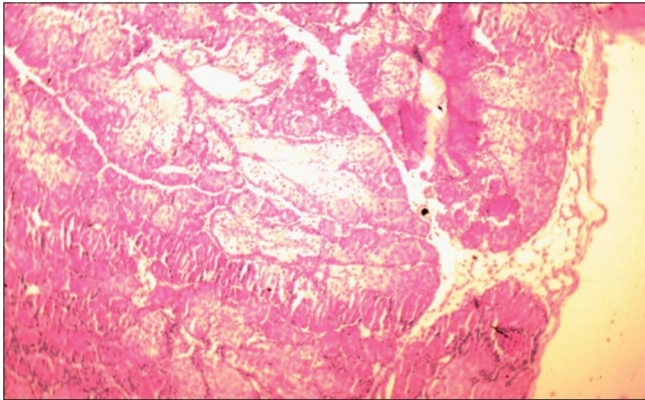
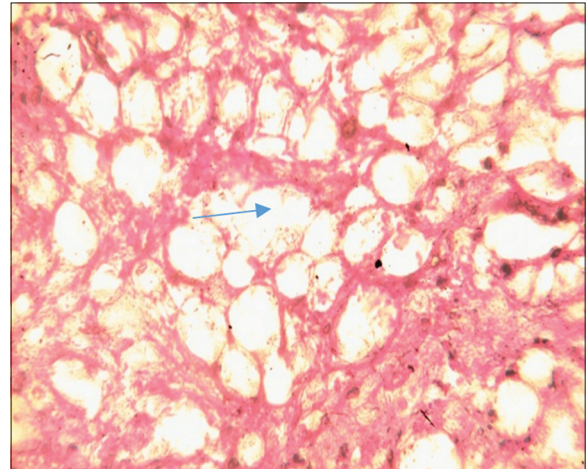
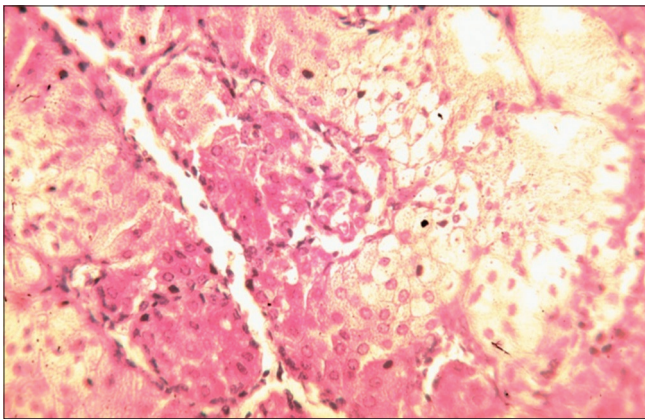
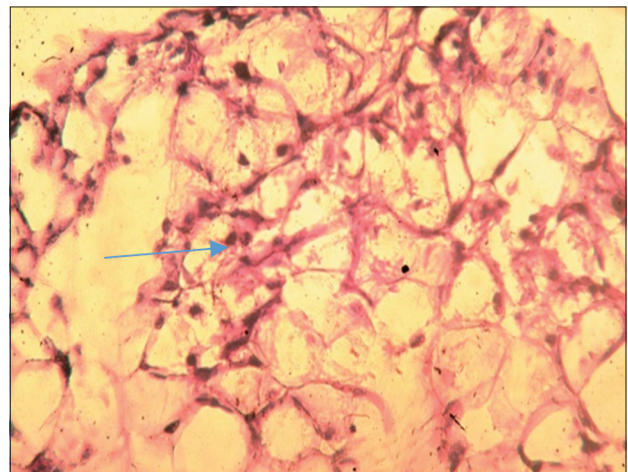
Sections of preputial glands from castrated group [Figures 3 and 4] showed atrophied acini and most of them are vacuolated with increased connective tissue capsule. In addition, the basal cells are fewer in number as compared to the control normal group. Testosterone treatment of castrated animals has dramatic effects on the gland structure. Such dose of testosterone was able to increase the extent of acinar development which is resulted in glandular hypertrophy with many acini at various stages of development. The parenchymatous acini were compact and many fused to form irregular masses [Figures 5 and 6].

DISCUSSION

The use of olfactory communication is wide-spread throughout the animal kingdom, as genetic, hormonal variations, social

Table 1: The essential pheromonal compounds present in the preputial glands of: intact control mice, castrated, and castrated treated with testosterone

Number of essential pheromones	Control (intact subjects)	Castrated subjects	Castrated treated with testosterone
1	-Farnesene β	-	-
2	(E)- α -Farnesene and α -Farnesene	α -Farnesene	-
3	1- Tetradecanol	1- Tetradecanol	1-Tetradecanol acetate
4	1-Hexadecanol	-	1-Hexadecanol
5	1-Hexadecanol, acetate	-	-
6	Tetradecanol, acetate	-	-

**Figure 1:** H&E-stained cross histological section of intact mouse's preputial glands, exposing the stroma, trabecular system, and capsule ($\times 100$)**Figure 3:** A cross histological section of castrated mice's preputial glands stained with H&E displays acini depletion and that most of them are vacuolated (arrow) ($\times 100$)**Figure 2:** The acini and basal cells are visible in a cross histological section of intact mice's preputial glands stained with H&E ($\times 400$)**Figure 4:** Transverse histological section of castrated mice's preputial glands stained with H&E exhibits atrophied acini (arrow) and fewer basal cells ($\times 400$)

imprinting, overall health, environmental factors, dietary changes, and other factors all appear to have a significant impact on how chemo signals are discharged and perceived in the sense of competition for reproductive potential.^[19] At present, a different researcher uses the term “pheromone” in the sense of mammals with much less apprehension. This can be attributed, at least in part, to (i) recent groundbreaking research identifying the ubiquity of receptor proteins found in olfactory neurons, (ii) a better understanding of the “chemically selective” vomeronasal organ, and (iii) the evidence that distinct behavioral and hormonal responses in mammals can also be caused by a single chemical substance

or a relatively simple synthetic mixture.^[20,21] It is much easier to understand pheromone – protein interactions with a various of smaller soluble binding proteins. A number of these proteins may be involved in what are known as perireceptor events.^[22] The main source of pheromones in the mice are preputial glands that are rich in wax esters, triglycerides, and

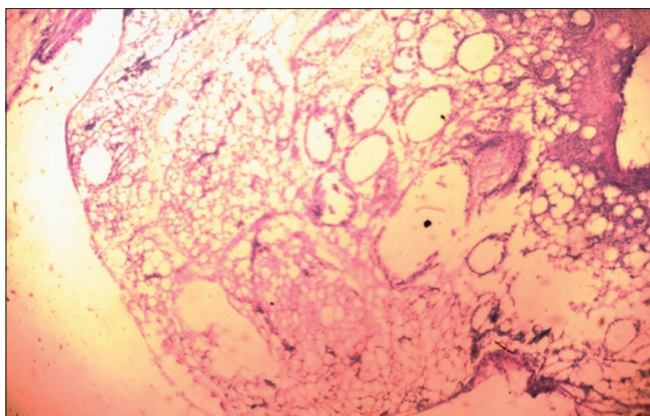


Figure 5: Cross-section of the preputial glands of castrated treated mice with testosterone, stained with H&E, demonstrating the restructuring of some gland regions ($\times 100$)

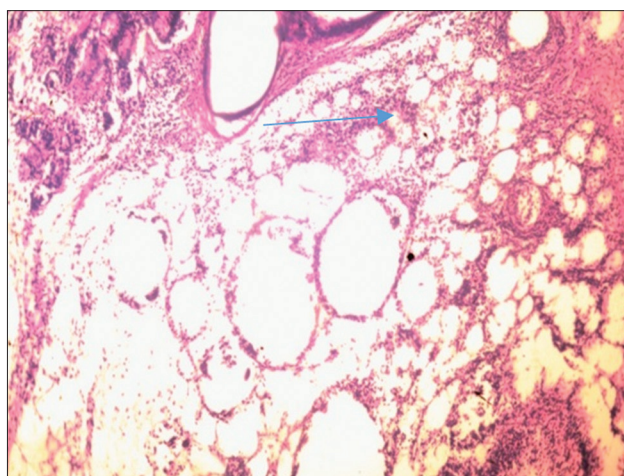


Figure 6: Section from castrated mice treated with testosterone having their preputial glands stained with H&E, showing a well-developed stroma with some hypertrophied acini (arrow) in the central part ($\times 400$)

alkyl-2,3-diacylglycerols and are believed to play a role in behavioral interactions through the release of pheromones.^[20] The MC5R gene is expressed in the central nervous system and in a variety of peripheral tissues, especially in the skin. The encoded protein is involved in different physiological processes, including lipid metabolism, exocrine function, and pro-inflammatory activity.^[23] MC5R belongs to a group of MCRs in the melanocortin system, and each one plays a major role in the body's physiological activities. When the MC5R gene was disrupted in transgenic mice, it disrupted their exocrine glands, resulting in a decrease in sebum production.^[24,25]

According to Morgan and Cone,^[26,27] the preputial gland of rodents expresses the MC5R and secretes pheromones that encourage aggressiveness. A pheromone signal that suppresses aggression is disinhibited by MC5R deficiency. GPCRs are essential for bringing various external signals into cells and controlling a number of physiological processes. MC5R deficiency produces a preputial defect that abolishes trophic responsiveness to melanocortins.^[28] It was noted that castration

markedly reduced preputial gland size and sebum content. Indeed, the preputial and other sex accessory organs of adult rodents seem largely dependent on continued androgenic stimulation for their differentiation and the preservation of their normal structure and function.^[29] In addition, castration in the present study has a depressed effect on the essential pheromone compounds which resulted two compounds only the (α -Farnesenes and 1-Tetradecanol) as compared with the normal control subjects.

These findings are in agreement with Zhang *et al.*^[30] of the identification of essential pheromonal compounds.

The histological sections from such subject appeared atrophied preputial acini with most of them which are vacuolated. These results explained the findings of Homady^[31] when he demonstrated that castration has harmful effects on the preputial glands of male mice. Reducing androgens by castration, hypophysectomy, or application of anti-androgenic compounds (such as oestrogen and flutamide) results in structural involution of mice, rat's sex – accessory organs, indicated by cellular atrophy, depressed size and organization of cellular organelles, disorganization and loss of granular endoplasmic reticulum, decreased numbers of free ribosomes and secretory granules, nuclear shrinkage, depleted mitochondria, loss of acid, and alkaline phosphatase activity and abolition of metabolic and functional activities.^[19,32]

The histochemical analysis of preputial glands from castrated mice treated with testosterone appeared two types of the essential pheromonal compounds (1-Hexadecanol and 1-tetradecanol acetate). These findings suggested that such dose of testosterone did not restore the essential compounds which can be attributed to dose effect. These findings are agreed with the findings of^[19,33] who demonstrated that castrated male mice treated with testosterone maintained the activity of this gland as well as sexual behavior of castrated mice. In the present findings, testosterone treatment was able to restore the preputial histology structure to limit extent which appears that it is a dose dependent. Actually, testosterone appears to be a precursor to a number of other steroids and many only exert its physiological and behavioral actions after metabolic conversions. These transformations may increase the variety of candidates for behavioral control with particular pathway having differing importance in different species enabling organisms with the ability to influence two or more targets relatively independently.^[34,35]

Up to our knowledge, there was no works were conducted using GC-MS on preputial glands of castrated or castrated treated subjects with testosterone and this study was intended to fill this gap.

CONCLUSION

In the current research, six combination of essential pheromones were identified in the normal intact subjects. Therefore, it seems that castration has a deleterious effect on both gland activity and essential pheromonal compounds, whereas treatment with testosterone has significant effects to restore preputial activities but did not able to restore the major essential compounds that may be contributed to the lowest dose of testosterone used.

REFERENCES

1. K. Fabianová, M. Martončíková, D. Fabian, J. Blaško and E. Račeková. Diverse effect of different odor stimuli on behavior and fos protein production in the olfactory system neurogenic region of adult rats. *Behavioural Brain Research*, vol. 265, pp. 38-48, 2014.
2. M. H. Homady, L. Alquraishi, M. H. Ubeid and A. S. M. Juma. Ultra structural studies of mouse liver in castrated subjects treated with grape juice. *International Journal of Clinical Case Reports and Reviews*, vol. 6, no. 3, pp. 1-5, 2021.
3. S. Dey, P. Chamero, J. K. Pru, M. S. Chien, X. Ibarra-Soria, K. R. S. D. W. Logan, H. Matsunami, J. J. Peluso and L. Stowers. Cyclic regulation of sensory perception by a female hormone alters behavior. *Cell*, vol. 161, no. 6, pp. 1334-1344, 2015.
4. P. R. Griffiths and P. A. Brennan. Roles for learning in mammalian chemosensory responses. *Hormones and Behavior*, vol. 68, pp. 91-102, 2015.
5. Y. C. Wei, S. R. Wang, Z. L. Jiao, W. Zhang, J. K. Lin, X. Y. Li, S. S. Li, X. Zhang and X. H. Xu. Medial preoptic area in mice is capable of mediating sexually dimorphic behaviors regardless of gender. *Nature Communications*, vol. 9, pp. 1-15, 2018.
6. R. Mozūraitis, V. Karalius, V. Būda and A. K. Borg-Karlon. Inter- and intraspecific activities of compounds derived from sex pheromone glands of currant borer, *Synanthedon tipuliformis* (Clerck) (Lepidoptera: Sesiidae). *Zeitschrift für Naturforschung C*, vol. 61, no. 3-4, pp. 278-284, 2006.
7. Y. Kiyokawa, T. Kikusui, Y. Takeuchi and Y. Mori. Alarm pheromones with different functions are released from different regions of the body surface of male rats. *Chemical Senses*, vol. 29, no. 1, pp. 35-40, 2004.
8. A. Majeed and M. Homady. Pheromonal components of intact male mice preputial gland in relation to flutamide effects. *Jacobs Journal of Anatomy*, vol. 3, pp. 1-9, 2016.
9. M. H. Homady. The influences of some medicinal plant extracts on the aggressivity and fertility of male mice. *Philippine Journal of Science*, vol. 130, pp. 119-126, 2001.
10. M. H. Homady, L. Alquraishi, S. S. Tanya and A. S. M. Juma. The intra gastric effects of grape juice on histological structure of liver tissue in castrated treated mice. *Journal of Human Anatomy*, vol. 4, pp. 1-6, 2020.
11. L. Conchou, P. Lucas, C. Meslin, M. Proffit, M. Staudt and M. Renou. Insect odorscapes: From plant volatiles to natural olfactory scenes. *Frontiers in Physiology*, vol. 10, p. 972, 2019.
12. C. Y. Lin, C. C. Hsu, M. T. Lin and S. H. Chen. Flutamide, an androgen receptor antagonist, improves heatstroke outcomes in mice. *European Journal of Pharmacology*, vol. 688, pp. 62-67, 2012.
13. M. H. Homady, L. Alquraishi and A. S. M. Juma. Ultrastructural studies of mouse liver in castrated subjects treated with grape juice. *International Journal of Clinical Case Reports and Reviews*, vol. 6, no. 3, pp. 1-6, 2021.
14. M. Novotny. Pheromones, binding proteins and receptor responses in rodents. *Biochemical Society Transactions*, vol. 31, no. Pt 1, pp. 117-122, 2003.
15. L. Conchou, P. Lucas, N. Deisig, E. Demondion and M. Renou. effects of multi-component backgrounds of volatile plant compounds on moth pheromone perception. *Insects*, vol. 12, pp. 409, 2021.
16. P. F. Brain. *Hormones and Aggression*. Vol. 2. California, Eden Press, 1979.
17. J. X. Zhang, X. P. Rao, L. Sun, C. H. Zhao and X. W. Qin. Putative chemical signals about sex, individuality, and genetic background in the preputial gland and urine of the house mouse (*Mus musculus*). *Chemical Senses*, vol. 32, no. 3, pp. 293-303, 2007.
18. N. Y. Al-Harbi, M. A. Hadi and F. A. Abbas. Effect of Flax Seeds (*Linum usitatissimum* L.) extract in male reproductive system of albino rat treated with cyproterone acetate. *Journal of Global Pharma Technology*, vol. 9, pp. 221-231, 2017.
19. M. H. Homady and A. Majeed. Histochemical and pheromonal components of mouse preputial gland in relation to F. hormonis treatment. *Research Journal of Pharmacy and Technology*, vol. 10, no. 12, pp. 4137-4141, 2017.
20. L. Stowers and T. F. Martinet. What is a pheromone? Mammalian pheromones reconsidered. *Neuron*, vol. 46, no. 5, pp. 699-702, 2005.
21. R. Tirindelli, M. Dibattista, S. Pifferi and A. Menini. From pheromones to behavior. *Physiological Reviews*, vol. 89, no. 3, pp. 921-956, 2009.
22. H. Breer, J. Fleischer and J. Strotmann. The sense of smell: Multiple olfactory subsystems. *Cellular and Molecular Life Sciences*, vol. 63, pp. 1465-1475, 2006.
23. D. J. Jun, K. Y. Na, W. Kim, D. Kwak, E. J. Kwon, J. H. Yoon, K. Yea, H. Lee, J. Kim, P. G. Suh, S. H. Ryu and K. T. Kim. Melanocortins induce interleukin 6 gene expression and secretion through melanocortin receptors 2 and 5 in 3T3-L1 adipocytes. *Journal of Molecular Endocrinology*, vol. 44, no. 4, p. 225-236, 2010.
24. S. Ramachandrapa, R. J. Gorrigan, A. J. L. Clark and L. Chan. The melanocortin receptors and their accessory proteins. *Frontiers in Endocrinology*, vol. 4, pp. 9, 2013.
25. W. Chen, M. A. Kelly, X. Opitz-Araya, R. E. Thomas, M. J. Low and R. D. Cone. Exocrine gland dysfunction in MC5-R-deficient mice: Evidence for coordinated regulation of exocrine gland function by melanocortin peptides. *Cell*, vol. 91, no. 6, pp. 789-798, 1997.
26. C. Morgan and R. D. Cone. Melanocortin-5 receptor deficiency in mice blocks a novel pathway influencing pheromone-induced aggression. *Behavior Genetics*, vol. 36, no. 2, pp. 291-300, 2006.
27. C. Morgan, R. E. Thomas, W. Ma, M. V. Novotny and R. D. Cone. Melanocortin-5 receptor deficiency reduces a pheromonal signal for aggression in male mice. *Chemical Senses*, vol. 29, no. 2, pp. 111-115, 2004.
28. M. E. Villar, P. Marchal, H. Viola and M. Giurfa. Redefining single-trial memories in the honeybee. *Cell Reports*, vol. 30, no. 8, pp. 2603-2613.e3, 2020.
29. M. H. Hamady. The preputial gland and its role in pheromone production in relation to some endocrine factors. *Journal of Stem Cell Biology and Transplantation*, vol. 1, p. 4, 2017.
30. J. X. Zhang, Y. J. Liu, J. H. Zhang and L. Sun. Dual role of preputial gland secretion and its major components in sex recognition of mice. *Physiology and Behavior*, vol. 95, no. 3, pp. 388-394, 2008.
31. M. H. Homady. Changes in the testicular and preputial structures of mice related to influences of Ferula hermonis extract. *Science*, vol. 1, no. 3, pp. 108-112, 2001.
32. G. Herrada and C. Dulac. A novel family of putative pheromone receptors in mammals with a topographically organized and sexually dimorphic distribution. *Cell*, vol. 90, no. 4, pp. 763-773, 1997.
33. M. Arteaga-Silva, M. Rodríguez-Dorantes, S. Baig and J. Morales-Montor. Effects of castration and hormone replacement on male sexual behavior and pattern of expression in the brain of sex-steroid receptors in BALB/c AnN mice. *Comparative Biochemistry and Physiology Part A: Molecular and Integrative Physiology*, vol. 147, no. 3, pp. 607-615, 2007.
34. M. H. Homady, T. S. Salih, M. M. Al-Jubori and M. D. Younus. Immunohistochemical and molecular studies of p53 and KRAS protein and their relations to colorectal carcinoma. *Cihan University-Erbil Scientific Journal*, vol. 5, no. 1, pp. 28-33, 2021.
35. S. Achiraman, D. S. Ganesh, S. Kannan, S. Kamalakkannan, N. Nirmala and G. Archunan. Response of male mice to odours of female mice in different stages of oestrous cycle: Self-grooming behaviour and the effect of castration. *Indian Journal of Experimental Biology*, vol. 52, no. 1, pp. 30-35, 2014.