

The response of periodontal ligament collagen fibres and the thickness of inserting periodontal ligament fibre bundles at cementum pressure sites of fixed orthodontic appliances

Noengki Prameswari

Laboratory of Orthodontics
Faculty of Dentistry Hang Tuah University
Surabaya - Indonesia

ABSTRACT

Previous research has indicated that there were several reactions in cellular activity and periodontal ligament collagen fibre as a response after orthodontic force application. Cementum has function to give attachment to collagen fibres of the periodontal ligament, maintaining the integrity of the root, helping to maintain the tooth in its functional position in the mouth, and being involved in tooth repair and regeneration so in the orthodontic tooth movement can induce changes in the cementum. The aim of this research is to investigate that fixed orthodontic appliance can change the amount of periodontal ligament collagen fibre and the thickness of inserting periodontal ligament fibre bundles at pressure site of cementum. This experimental study was held in laboratory with post test only control group design. Twenty two (22) premolar sample from 11 patient were divided into 2 groups. K group as control group (without treatment) and P group as treatment group (with using fixed orthodontic appliance). The amount of periodontal ligament collagen fibre and thickness of inserting periodontal ligament fibre bundles was examined by light microscopy and measured by image tool program. In the summary, there are increasing amount of periodontal ligament collagen fibre and the thickness of inserting periodontal ligament fibre bundles at cementum pressure sites as a normal response to remodeling and regenerating to orthodontic appliance and have function for strengthen adhering tooth cementum to the periodontal ligament.

Key words: fixed orthodontic appliance, collagen, cementum

Correspondence: Noengki Prameswari, c/o: Bagian Ortodonsia, Fakultas Kedokteran Gigi Universitas Hang Tuah. Jln. Arif Rahman Hakim 150 Surabaya 60111, Indonesia. Email: noengki_prameswari@yahoo.com

INTRODUCTION

The use of orthodontics appliances has a principal to give continually pressure, until the tooth movement happens. It involves bone remodeling process, whereas resorption happens on the moved side, and apposition with a new bone at the opposite side. The pressure which is given to the teeth cause a pressure area and tension area at the teeth. On the fixed appliance, there is a light continuously forces and produced bodily movement. There are some changes on tooth movement in using fixed appliance, such as pain, cellular changes on the periodontal ligament, undermining resorption at the alveolar bone, and a changes on a root of teeth, including the cementum.¹

After the treatment of orthodontics appliance is completed, relapse of teeth that move back to the beginning position can happen. The possibility of relapse, 40% came from the previous tooth movement.² The teeth relapse process can occurs over 4–6 months period, and also can occurs until 1 year after the orthodontics appliance is removed.¹ Mechanism of relapsing itself is not clearly yet. Factors that involve to unstable orthodontic treatment result are: the gingival and periodontal tissues are affected by orthodontic tooth movement and require time for reorganization when the appliance are removed, changes

produced by growth may alter the orthodontic treatment result, the teeth may be in an inherently unstable position after the treatment. Experiences held on the mouse molar relapse teeth show that fastly remodeling occur on the periodontal ligament and around alveolar bone, and hyalinization process and mineralization occurs on the pressure sites that can be resorpt by osteoclas, macrophage-like cells and fibroblast-like cells.³ So, it is important to know about root structure in functional position, ligament periodontal, bone, cellular response, extra cellular matrix that bind with cementum and changes in response to the orthodontics movement.

There are many researches that has been done to human related with cellular changing, because of the force orthodontics appliance, but there are still much things that not clearly yet, especially about the changes of cell quantity on the root during the treatment using orthodontics apparatus. So it needs an advanced research. In experiment using proliferating cell nuclear antigen (PCNA), during the use of orthodontics appliances, obtained on the tension areas, cell proliferation on the periodontal ligament reduce at the 3rd day until the 28th day, whereas on the pressure area at the bone surface area, cell proliferation increase at the 3rd day until the 10th day, and then reduce until 28th day, and cells that found at bone surface is the multinucleated

osteoclast, at the periodontal ligament is fibroblast, osteoblast, and cementoblast precursor cell. Beside that, the increasing of cell apoptosis either at pressure area and tension area are founded.⁴ At the other research results there are some picnotic nuclei which is found at the periodontal ligament with the shrinkage signs and chromatin margination along the nucleus of membrane that it is a signs of necrosis.⁵ The research did to the maxillary first incisor, resulted that mechanics stresses that give to apical root during the movement of teeth cause the increase of the apical cementum thickness.⁶

At the other research found any collagen synthesis that increase at the periodontal ligament pressure sites compared at the tension area that showing a resorption area and remodeling that works very active to the pressure area followed by loosening of the hyalinization.^{7,8}

One of the tooth structure that responsive to the force orthodontics appliance is cementum. Primary function of cementum is giving adhering to the collagen fibre from periodontal ligament. Beside it, cementum keeps the integrity of the tooth root, helps keeping the position of functional tooth in mouth, and help either to repair and regeneration of tooth.

As the cellular process implication to the orthodontics treatment is the amount change of periodontal ligament collagen fibre and thickness of inserting periodontal ligament fibre bundles. This research using fixed orthodontics appliances that is used to the premolar subject that have extraction indication on the orthodontic treatment and after that examined on the pressure site of cementum, so that can knowing amount change of periodontal ligament collagen fibre and the thickness of inserting periodontal ligament fibre bundles.

Biology of cementum

Cementum is the thin layer of calcified tissue covering the dentine of the root. Cementum contains on a wet-weight basis 65% inorganic material, 23% organic material and 12% water. Cementum varies in thickness at different level of the root. It is the thickest at the root apex and in the interradicular areas of multirrooted teeth, and the thinnest cervically. The thickness cervically is 10–15 µm, and apically 50–200 µm. Cementum is a vascular and has no innervation.⁹

The various types of cementum encountered may be classified in three different ways : the presence or absence of cells, the nature and origin of the organic matrix and combination of both. Cellular cementum contains cells (cementocytes); acellular cementum does not. Acellular cementum covers the root adjacent to the dentine, whereas cellular cementum is found mainly in the apical area and overlying the acellular cementum.⁹

Acellular cementum consists of the first layer of cementum deposited at dentinocementum junction and also called primary cementum. It is formed at a slow rate and contains no embedded cementocytes. Acellular cementum appears relatively structure less. In the outer region of the

radicular dentine, the granular layer of Tomes can be seen and outside this hyaline layer of Hopewell-Smith. A dark line may be discerned between the hyaline layer and the acellular cementum; this may be related to the afibrillar cementum that is patchily present at this position. Cellular cementum or secondary cementum consists of the last layers of cementum, mainly in the apical one-third of the root. Cellular cementum is formed at a faster rate than acellular, and thus many embedded cementocytes are found within it. At its periphery are the cementoblasts in the periodontal ligament, which allow for the future production of more cellular cementum if needed.^{9,10}

Cementum derives its organic matrix from two sources: from the inserting Sharpey's fibres of the periodontal ligament, and from the cementoblasts. Classification of cementum is decided according to the nature and origin of the fibrous matrix. When derived from the periodontal ligament, the fibres are referred to as the extrinsic fibres. These Sharpey's fibres continue into the cementum in the same direction as principal fibres of the ligament (perpendicular or oblique to the root surface). When derived from cementoblast, the fibres are referred to as intrinsic fibres. These run parallel to the root surface and approximately at right angles to the extrinsic fibres. Where both extrinsic and intrinsic fibres are present, the tissue may termed mixed fibre cementum.⁹

The organic matrix of cementum is composed primarily of collagen. The principle collagen in cementum is type I with lesser amounts of types III, V, and VI. Sharpey's fibres, which represent a major volume feature of cementum comprise most mostly type I, with type III apparently coating type I collagen in these fibres. Cementum contains two major non-collagenous proteins, bone sialoprotein (BSP) and osteopontin (OPN).^{11,12}

Organic matrix and inserting periodontal ligament fibre bundle

Three cementum types differing in the presence of cells and collagen fibres are distinguished in humans. Acellular extrinsic fibre cementum/periodontal ligament collagen fibre/periodontal ligament collagen fibre which serves the primary attachment function, covers cervical and middle portions of the roots, and it is usually confined to the coronal half of the root. It consists of a dense fringe of collagenous fibres implanted into dentinal matrix and perpendicular to the root surface. For this type of cementum all the collagen is derived as Sharpey's fibres from the periodontal ligament (the ground substance itself may be produced by the cementoblasts. The fibres are generally well mineralized.^{9,11,12}

Cellular intrinsic fibre cementum is composed only of intrinsic fibres running parallel to the root surface. The absence of Sharpey's fibres mean intrinsic fibre cementum has no role in tooth attachment. It may be found in patches in the apical region. It may be a temporary phase, with extrinsic fibres subsequently gaining a reattachment, or may represent a permanent region without attaching fibres.⁹

In mixed-fibre cementum, the collagen fibres of the organic matrix are derived from both extrinsic fibres (from the periodontal ligament) and intrinsic fibres (from cementoblast). The extrinsic and intrinsic fibres can be readily distinguished.⁹

The extrinsic fibres seen in ground sections may have unmineralised cores and called as inserting periodontal ligament fibre bundles. With total internal reflection of transmitted light, giving the appearance of thin black lines. That inserting periodontal ligament fibres bundle have an ovoid or round bundles about 5–7 µm in diameter.⁹ Fixed orthodontic appliance and the response of cementum and matrix cementum to orthodontic movement

Orthodontic treatment is based on the principle that force application to a tooth causes remodeling of the periodontal ligament and the bone surrounding the root, which will finally result in displacement of that tooth. Sandstedt reported already in 1904 on bone resorption on the 'pressure' side and bone deposition on the 'tension' side after force application to a tooth. It is necessary to consider the biologic control mechanisms that lead from the stimulus of sustained forced application to the response of orthodontic tooth movement. Two possible control elements, biologic electricity and pressure-tension in the Periodontal Ligament (PDL) that affect blood flow, are contrasted in the two major theories of orthodontic tooth movement. The bioelectric theory relates tooth movement at least in part to changes in bone metabolism controlled by the electric signals that are produced when alveolar bone flexes and bends. The pressure-tension theory relates tooth movement to cellular change produced by chemical messengers, traditionally thought to be generated by alterations in blood flow through the PDL. Pressure and tension within the PDL, by reducing (pressure) or increasing (tension) the diameter of blood vessels in the ligament space, could certainly affect blood flow. The two theories are neither incompatible nor mutually exclusive. From a contemporary perspective, it appears that both mechanisms may play a part in the biologic control of tooth movement.¹

Alterations in the periodontal tissue during orthodontic tooth movement specifically affect the alveolar bone, periodontal ligament, and root surface of cementum orthodontic. Orthodontic force initiation stimulates the remodeling of alveolar bone, which result in tooth movement. Before this remodeling, initial changes in response to a local compression of the periodontal ligament and affect to the cementum, which have attachment to collagen fibres of the periodontal ligament.^{2,7}

The response of cementum to the orthodontic movement is less readily resorbed, a feature is unknown but it may be related to differences in physicochemical or biological properties between bone and cementum, the properties of the precementum, the increased density of Sharpey's fibres particularly in acellular cementum, and the proximity of epithelial cell rests to the root surface.⁹

Although cementum is less susceptible to resorption than bone under the same pressure (with orthodontics forces), most roots of permanent teeth still show small localized areas of resorption. The resorption is carried out by multinucleated odontoclasts. Resorption deficiencies may be filled by deposition of mineralized tissue. A line known as reversal line may be seen separating the repair tissue from the normal underlying dental tissues. In this section, odontoclasts have resorbed through the thin layer of acellular cementum.^{7,9}

Changes also occur in the matrix of cementum. In the pressure sites at 14 days, the course of the collagenous fibres was completely disturbed. The process of removal of hyalinized tissue and revascularization had begun, new collagenous fibres had been formed. In the tension areas at 14 days Sharpey's fibres, consisting of type I collagen were embedded in the osteoid and in cementum. Collagenous fibres appeared to be stretched although the width of the periodontal ligament was hardly larger than normal.^{2,7}

Repair is occurring and a thin layer of formative cells (cementoblasts) have deposited a thin layer of matrix (precementum) in the deficiency. The repair tissue resembles cellular cementum. The formative cells have a similar ultra structure to cementoblasts; its crystals are smaller; and calcify globules are present, suggesting that mineralization is not proceeding evenly.^{2,9}

MATERIAL AND METHODS

Patients and orthodontic treatment of study group

Researches was done at Department of Orthodontics, Dr Ramelan Hospital Surabaya for patient's research, Laboratory of Pathology Anatomy of Dr Sutomo Hospital to make a histology section, and Laboratory of Histology and Anatomy of Medical School Airlangga University Surabaya to make photomicroscopics and measurement calculation using image tool program.

Twenty two (22) maxillary first premolar with suitable indication to extract because an orthodontics reason from 11 patients (age 16–20, females), attending the Department of Orthodontic Dr Ramelan Hospital Surabaya, East Java, Indonesia were used as subjects. Patients with carries and periodontitis will not use as a subject. All patients were given an enough explanation about the purpose and benefit of research, and asked for their willingness with signing an informed consent as a agreement.¹³

Subjects were divided into 2 groups. Right maxillary first premolar for each patient under treatment using fixed orthodontic appliance with 0.012 inch Nitinol arch wire is placed in an 0.018 bracket with adjusting first ordered bends out step in the horizontal plane of space using angled utility arch pliers so that first premolar were retracted to bucal served as the test teeth (treatment group) and contra lateral first premolar as a control group (without treatment). After 10 days, the tooth were extracted. The extract procedure by using local anesthetics technique on bucal fold of first

premolar teeth and removal the teeth by luksation at bucal-palatal direction. Teeth that extracted must be intact a whole of root structure, so that cementum can be seen fully. Teeth that extracted yet kept in 10% buffer formalin solution.

Histological procedure

After 7 days the teeth were kept in 10% buffer formalin solution, then do the decalcification so that the hard tissue loss their calcium. First, decalcify sections in large quantities of 5% aqueous solution of nitric acid for 1 to 4 days with changing the solution daily. Then, washing in running water for 24 hours. After that, neutralizing in 10% formalin to which an excess of calcium or magnesium carbonate has been added, dehydrate, and clear.^{14,15}

After that, cut sagittally specimen on bucal-palatal direction with thin section in the middle and prepare the preparation of section (Figure 1). The specimens were embedded in paraffin with a conventional technique. Section, 4 to 5 μm thick, were stained with Malory Acid.^{14,15}

Histology slides were examined by light microscoph Nikon SKT. S-123355 that is completed with digital camera viewing 400 \times enlargement. Then, needed to decide part of section to measure. Measured part is a half from apical to cervical cementum pressure area and cementum tension area at the other side per unit viewing area microscoph and then take a photograph. The measurement do with two observer

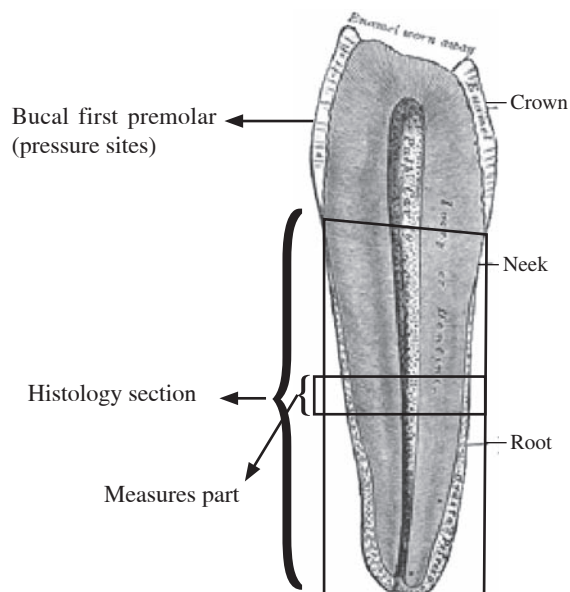


Figure 1. Sagittal section of first premolar at middle bucal-palatal direction.

for counting amount of periodontal ligament collagen fibre, and thickness of inserting periodontal ligament fibre bundle per unit viewing area (Figure 2).




Figure 2. Light micrograph of periodontal ligament collagen fibre and inserting periodontal ligament fibre bundles ($\times 400$).

Table 1. Mean and Standard Deviation data of amount of periodontal ligament collagen fibre and (amount fibre per unit viewing area), and thickness of inserting periodontal ligament fibre bundles (micron)

Dependent Variable	Group			
	Control		Treatment	
	\bar{X}	SD	\bar{X}	SD
Amount of periodontal ligament collagen fibre and (amount fibre per unit viewing area)	20.8182	3.7635	24.3636	2.3779
Thickness of inserting periodontal ligament fibre bundles (micron)	6.0418	1.0746	8.9773	1.4380

RESULT

This experiment is investigating amount of periodontal ligament collagen fibre and the thickness of inserting periodontal ligament fibre bundles as a effect of orthodontic appliance. Data is observed from light micrograph photo of periodontal ligament collagen fibre and inserting periodontal ligament fibre bundles.

Descriptive analysis test shows that mean data of amount of periodontal ligament collagen fibre and the thickness of inserting periodontal ligament fibre bundles is increased. Mean of treatment group have amount periodontal ligament collagen fibre 24.3636 compare with control group 20.8182 and thickness of inserting periodontal ligament fibre bundles 8.9773 compare with control group 6.0418.

Manova test shows that amount of periodontal ligament collagen fibre and the thickness of inserting periodontal ligament fibre bundles is increased significantly difference compare with control group (sig 0.01; $p < 0.05$) as a effect orthodontic appliance.

DISCUSSION

Cementum prime function is to give attachment to collagen fibres of the periodontal ligament, is a highly responsive mineralized tissue, maintaining the integrity of the root, helping to maintain the tooth in its functional position in the mouth, and being involved in the tooth repair and regeneration.⁹ Cementum is the site where soft tissue attachment has to be re-established and cementum matrix is a rich source of many growth factors which influence the activities of periodontal cell.¹² Cementum is unique tissue to respond orthodontic movement. Cementum is less readily resorbed, a feature that is important for permitting orthodontic tooth movement and may be related to density of Sharpey's fibres, properties of precementum, and physicochemical/ biological bone.^{9,16}

Sample are taken in 10 days after tooth retracted because tooth movement happened after 7 days tooth retracted.¹ In Mabuchi,⁴ experiment, the difference cellular proliferation during the use of orthodontics appliances happened at 3rd day until 10th day, obtained on the tension areas, cell proliferation on the periodontal ligament reduce at the 3rd day until the 28th day, whereas on the pressure area at the bone surface area, cell proliferation increase at the 3rd until the 10th day, and then reduce until 28th day. Cells changing as a normal response to remodeling and regenerating to orthodontic movement that found is the multinucleated osteoclast, fibroblast, osteoblast, and cementoblast precursor cell.^{6,7}

During tooth retracted, angiogenesis, collagen synthesis and periodontal ligament collagen fibre component become active. In the pressure site there are cell changes involves migration, adhesion, proliferation, and differentiation of several cell type. All these activities are triggered when polypeptide mediators bind to their cell-surface receptor

and when integrins bind to periodontal ligament collagen fibre component.¹²

In this experiment, amount of periodontal ligament collagen fibre, and thickness of inserting periodontal ligament fibre bundle were examined as a respond indicator of periodontal ligament collagen fibre activity at the cementum pressure sites to the orthodontic appliances. In this experiment, after orthodontic appliance, the amount of periodontal ligament collagen fibre and the thickness of inserting periodontal ligament fibre bundles is increased. Periodontal ligament collagen fibre and inserting periodontal ligament fibre bundle are produced by fibroblast, one of cells can change during orthodontic appliances. Measurement can not be done direct to the fibroblast because of difficulty of seeing fibroblast at the malory acid staning. In the orthodontic appliance, in the cementum pressure site, there are up regulation activity of cell like osteoclasts, fibroblasts, osteoblasts and osteocytes precursor.^{2,6,17} One important function of fibroblasts is to increase periodontal ligament collagen synthesis as a cellular respond of homeostasis mechanism to tooth retracted. Collagen that is produced giving adhering between cementum and periodontal ligament and keep the integrity of the teeth root, help keep the position of functional teeth in mouth to the mechanical stress such as orthodontic movement.^{2,17} Remodeling collagen in the periodontal ligament during orthodontic movement have half lives 2 days.¹¹

Increasing amount of periodontal ligament collagen fibre, and thickness of inserting periodontal ligament fibre bundle in the pressure site related to increasing periodontal ligament collagen fibre synthesis. Periodontal ligament collagen fibre determines the three-dimensional cell architecture and transmits and translates external mechanical and tensional forces to appropriate response signals. Adhesion to periodontal ligament collagen fibre is essential for cell cycle. Periodontal ligament collagen fibre also regulates gene expression of growth factors, growth factor receptors, and other protein, and determines the outcome of a cell's response to growth factors. Growth factors that regulate periodontal ligament collagen fibre function is platelet-derived growth factor (PDGF), which mitogenic to fibroblasts. Other growth factors: transforming growth factor- β (TGF- β) and connective tissue growth factor (CTGF) activate collagen synthesis.^{12,18}

Increasing the amount change of periodontal ligament collagen fibre and thickness of inserting periodontal ligament fibre bundles related to mechanosensitive process in regulating cell's volume because of mechanical stress such as orthodontic appliance.^{1,2,7,19} As a response to the mechanical force, cells bind to periodontal ligament collagen fibre through integrin, and the binding initiates a cascade of signaling reaction. Signaling reactions activated include tyrosine phosphorylation of focal adhesion kinase (FAK) and other signaling proteins, activation of mitogen-activated protein kinase (MAP kinase) cascade, expression of c-fos, and elevation of certain cyclin levels.

Signaling pathways induced by extra cellular matrix components cooperate with those activated by growth factors in mediating their biological function, and both integrin-and growth-factor-induced-signals are necessary for expression of G1 cyclins and cell cycle progression from G0/G1 to S-phase. Cyclin regulation is important for cell division.^{12,20,21,22}

Inserting periodontal ligament fibre bundles is a inserting bundle fibre from periodontal ligament to the cementum. The thickness of inserting periodontal ligament fibre bundles is important for strengthen tooth cementum in responding mechanical force with periodontal ligament.⁹ Theory of Inserting periodontal ligament fibre bundles is not knowing clearly yet. The thickness of inserting periodontal ligament fibre bundles is increase related to respond of mechanical stress orthodontic appliance. This function require active participation of integrins.^{12,20,21,22}

One theory about inserting periodontal ligament collagen fibre is derived from periodontal ligament collagen fibre which change because of mechanical pressure from orthodontic appliance. Mechanical pressure from orthodontic appliance induce cell migration and adhesion that need integrins function. In integrin expression, proteolysis is necessary for cell migration during tissue remodeling. Proteolysis need matrix metalloproteinase (MMPs) activity. Activated inflammatory cells produce matrix metalloproteinase (MMPs) than can degrade collagen and leads new transformation and composition adapted depending on the functional requirements of the tissue such as inserting periodontal ligament collagen fibre.^{11,12,23}

In the summary, there are many changes to response mechanical force of orthodontic appliance. Increasing amount of periodontal ligament collagen fibre and the thickness of inserting periodontal ligament fibre bundles at cementum pressure sites is a normal response to remodeling and regenerating to orthodontic appliance and have function for strengthen adhering tooth cementum to the periodontal ligament, keeping integrity of the tooth, and helping to maintain the tooth in its functional position in the mouth.

ACKNOWLEDGEMENT

This research was supported by a Penelitian Dosen Muda grant from DIKTI, Depdiknas, Indonesia.

REFERENCES

1. Proffit W. Contemporary orthodontics. 2nd ed. St Louis: Mosby Year Book, Inc; 1993. p. 266–339.
2. Pillon J. Orthodontic forces and tooth movement: Orthodontic forces and relapse, an experimental study in beagle dogs. Thesis. Medical Sciences of the University of Nijmegen. Available from www.orthodontics.nl/research/PHD_Thesis/jjgm-pilon.htm. Accessed January 13, 2005.
3. Yoshida Y, Sasaki T. Cellular roles in relapse processes of experimentally-moved rat molars. *Journal Electron Microscopy* 1999; 48(2): 147–57.
4. Mabuchi R, Matsuzaka K, Shimono M. Cell proliferation and cell death in periodontal ligaments during orthodontic tooth movement. *Journal Periodontal Res* 2002; 37:118–24.
5. Hatai T, Yokozeki M. Apoptosis of periodontal ligament cells induced by mechanical stress during tooth movement. *Oral Disease* 2001; 17:287–90.
6. Shaw A, Sameshima G, Vu H. Mechanical stress generated by orthodontic forces on apical root cementum: a finite element model. *Orthodontics & Craniofacial Research* 2004; 7(2):98.
7. Bishara S. Textbook of orthodontics. Philadelphia: WB Saunders Company; 2001. p. 468–72.
8. Buman A, Carvalho R, Schwarzer C, Yen E. Collagen synthesis from human periodontal ligament cells following orthodontic tooth movement. *The European Journal of Orthodontics* 1997; 19(1):29–37.
9. Berkovitz B, Holland G, Moxham B. Oral anatomy histology and embryology. 3rd ed. St Louis: Mosby; 2002. p. 168–77.
10. Nanci A. Ten cate's oral histology development, structure and function. 6th ed. St Louis: Mosby; 2003. p. 191–209.
11. Waddington R, Embery G. Proteoglycans and orthodontic tooth movement. *Journal of Orthodontics. British Orthodontic Society* 2001; 28:281–90.
12. Grzesik W, Narayanan A. Cementum and periodontal wound healing and regeneration. *Critical Review Oral Biology and Medicine* 2002; 13(6):474–84.
13. Pudjirahardjo W, Poernomo H, Machfoed H. Metode penelitian dan statistik terapan. Surabaya: Airlangga University Press; 1993. p. 57–8.
14. Suntoro H. Metode pewarnaan (histologi dan histokimia). Penerbit Bharatara Karya Aksara; 1983. p. 30–303
15. Suidiana I. Teknik praktis untuk jaringan sel. Negara: CV Dharma Sandi; 1993. p. 2–35.
16. Diekwisch T. Developmental biology of cementum. *International Journal Developmental Biology* 2001; 45:695–706.
17. Bartold M, Narayanan S. Periodontal connective tissues. Chicago: Quintessence Publishing Co, Inc; 1988. p. 173–92.
18. Smith A. Vitality of the dentin-pulp complex in health and disease: Growth factors as key mediators. *Journal of Dental Education* 2003; 67(6):678–87.
19. Foster T. A textbook of orthodontics. 3rd ed. Oxford: Blackwell Scientific Publications Limited; 1997. p. 240–1.
20. Schwartz M, Assoia R. Integrin and cell proliferation. *Journal of Cell Science* 2001; 114:2553–60.
21. Setyawan S. Mechanotransduction-integrins and cellular responses. Makalah Seminar Ikatan Ahli Ilmu Faal Indonesia cabang Surabaya pada 22 Agustus 2005. p. 1–5.
22. Shyy J, Chien S. Role of integrin in endothelial mechanosensing of shear stress. *Circulation Research* 2002; 7(2):769–75.
23. Kerrigan J, Mansell J, Sandy J. Matrix turnover. *Journal of Orthodontic* 2000; 27(3):227–33.