

## Histological changes during orthodontic tooth movement due to hyperbaric oxygen therapy

Arya Brahmanta,<sup>1</sup> Soetjipto,<sup>2</sup> and IB Narmada<sup>3</sup>

<sup>1</sup>Departemen of Orthodontic, Faculty of Dentistry, Universitas Hang Tuah

<sup>2</sup>Departemen Biochemistry, Faculty of Medicine, Universitas Airlangga

<sup>3</sup>Departemen of Orthodontic, Faculty of Dental Medicine, Universitas Airlangga  
Surabaya - Indonesia

### ABSTRACT

**Background:** Mechanical force of orthodontics causes changes in periodontal ligament vascularization and blood flow, resulting in biochemical and cellular changes as well as changes in the contour of the alveolar bone and in the thickness of the periodontal ligaments. Hyperbaric oxygen (HBO) therapy is one of many solutions stimulating the growth of new blood vessels and increasing tissue oxygenation. Thus, HBO plays a role in recovery of periodontal ligament and osteoblasts. **Purpose:** This study aimed to determine the effects of HBO therapy for seven days on periodontal ligament size and osteoblast number in the tension site during bone remodeling in tooth movement. **Method:** The study was true experimental laboratories with completely randomized control group post test only design. Twenty-four males guinea pigs were randomly divided into three groups. K0 was the control group without any treatment, K1 was the group given a mechanical orthodontic pressure, and K2 was the group treated with the addition of hyperbaric oxygen therapy. The maxillary incisors were moved distally by elastic separator. After HBO therapy on day 7, all of the groups were sacrificed, and then periodontal ligament size and osteoblast number were analyzed by one-way Anova and LSD statistical tests. **Result:** The results showed significant differences in the size of the periodontal ligament and the number of osteoblasts in the tension site among the groups ( $p < 0.05$ ). **Conclusion:** HBO therapy at 2.4 ATA for 7 days is effective in recovery of periodontal ligament and increased osteoblast number during bone remodeling in tension area of orthodontic tooth movement.

**Keywords:** periodontal ligament; osteoblast; tooth movement; hyperbaric oxygen; bone remodeling

**Correspondence:** Arya Brahmanta, Department of Orthodontic, Faculty of Dentistry, Universitas Hang Tuah. Jl. Arif Rahman Hakim 150 Surabaya, Indonesia. E-mail: arya.brahmanta@hangtuah.ac.id, Phone: 031-5945864, Fax: 031-591219.

### INTRODUCTION

Orthodontic tooth movement is indicated by remodeling changes in dental and paradental tissues, including periodontal ligament, alveolar bone, dental pulp and gingiva. Periodontal ligament (PDL) is a connective tissue that attaches tooth to the alveolar bone, it plays a crucial role in the adaptation process of teeth to physiological forces as well as to orthodontic forces.<sup>1</sup> These forces induced by strains would alter PDL vascularity and blood flow.<sup>2</sup>

During orthodontic tooth movement, the periodontal vasculature is severely impaired by chronic inflammation or excessive mechanical force. This leads to a hypoxic microenvironment of the periodontal cells and enhances

the expression of various cytokines and growth factors that may regulate angiogenesis and alveolar bone remodeling.<sup>3</sup> Orthodontic forces are known to occlude periodontal ligament vessels on the pressure side of the dental root, decreasing the blood perfusion of the tissue.<sup>4</sup>

In other words, orthodontic tooth movement is stimulated by the force exerted on the periodontal tissue that affect the remodeling of the alveolar bone as a result. When a force greater than capillary blood pressure applied to a tooth, hyaline zone might occur in the direction of the force. This hyaline zone, free of cells, is a necrotic area created by osteoclast activity originated from the tension site. In the tension site, osteoblasts are produced during bone apposition process.<sup>5</sup> During orthodontic tooth movement,

therefore, osteoblasts in the tension side are generated from osteoprogenitor cells, which reside within the PDL.<sup>6</sup>

The bone remodeling is characterized by activation, resorption, reversal, and formation, in both tension and compression tooth sites during orthodontic tooth movement.<sup>2,7</sup> Orthodontic force application induces several biological process leading to resorption in the pressure sites and apposition in the tension site. Histological changing occur for 5 days followed by its reversal in next 5 to 7 days and a late wave of bone formation between 7 and 14 days.<sup>8</sup>

Hyperbaric oxygen (HBO) therapy increases the amount of oxygen dissolved in blood (oxygen tension) which can then increase the amount of oxygen delivered to hypoxic tissues reducing the effects of hypoxia. Vascular endothelial growth factor (VEGF) has been identified as one of the primary growth factors responsible for neovascularization during wound healing and embryonic development. Oxygen tension is a key regulator of VEGF expression in vitro and in vivo.<sup>9</sup> HBO therapy is the inhalation of 100% oxygen inside a hyperbaric chamber pressurized to greater than 1 atmosphere absolute (ATA; 760 mm Hg).

HBO therapy, consequently, is potential because it stimulates the growth of new blood vessels and results in a substantial increase in tissue oxygenation that can enhance wound healing. HBO therapy can also promote collagen and adenosinetriphosphate (ATP) synthesis, capillary ingrowth, and osteoblastic and osteoclastic activities. The stimulation of osteogenesis by HBO has been reported applied in animal experiments and clinical treatments. Oxygen tension has a triggerinrole in bone remodeling. Increased oxygen tension causes cellular differentiation to osseous tissue, whereas decreased oxygen tension results in cartilage formation. There is a parallelism between the increasing of oxygen tension and the increasing of osteoblast and osteoclast activities.<sup>10</sup> This study aimed to evaluate periodontal ligament size and osteoblast number in the tension site due to 2.4 ATA hyperbaric oxygen therapy during bone remodeling in tooth movement.

## MATERIALS AND METHODS

The study was true experimental laboratories with completely randomized control group post test only design. Ethical permission was obtained from ethics and scientific research committee of experimental animal use in Faculty of Dental Medicine, Universitas Airlangga. Twenty-four male guinea pigs (*Cavia cobaya*) aged three to four months and weighed 300-400 grams. The guinea pigs, fed with a standard pellet diet and tap water ad libitum, were randomly divided into three equal groups. The materials used were 100% pure oxygen in hyperbaric animal chamber, 10% ketamine injection as anesthetic drug, a dose of 0.1-0.2 ml/kg for *acepromazine* 0.5 ml, 10% buffered formalin, Betadine solution, and cotton.

The procedure of this study was began with acclimatization of animals for 48 hours. Guinea pigs were divided into three groups, namely (K0) as the control group, (K1) as the orthodontic group and (K2) as the HBO group. An orthodontic force triggering orthodontic tooth movement on the maxilla by using elastic separator was administered to groups K1 and K2. The force (reciprocal) was measured with a gauge during the experiment. In Group K2, treated with orthodontic force day for 14 days and then with daily HBO therapy at 2.4 ATA for 90 minutes in 7 days, from day 8 to day 14. HBO therapy was conducted by using a veterinary hyperbaric chamber model.

The guinea pigs were monitored during the experiment, and all of the groups were sacrificed on the fourteenth day of the experiment. The maxillary teeth were dissected and placed in 10% buffered formalin. Afterwards, histological section were prepared with HE, and then observed by using a microscope. The photos were taken to measure the number of osteoblasts seen on the microscope with an enlargement 400x. Meanwhile, the size of the periodontal ligament on 1/3 apical in the tension site was observed with an enlargement 40x. Each histological section was observed and calculated as many as three times in the field of view.

The data were statistically measured by using Statistical Package for the Social Science (SPSS) version 20 program. The statistically significant differences among the HBO group, the orthodontic group and the control group were determined and evaluated by using one way Anova and LSD tests ( $p < 0.05$ ).

## RESULTS

The data obtained showed that there were differences of the periodontal ligament size in the tension site in each group. In the control group, the mean was 6.886 mm, the mean of the orthodontic group was 11.563 mm, and the mean of the HBO group was 5.030 mm (Table 1). The data also showed that the number of osteoblasts increased in all of those treatment groups. The highest number found in the group treated with HBO 14.571 (cell/field of view). Meanwhile, in the control group, the mean was 13.142, and in the orthodontic group the mean was 4.833 (Table 2).

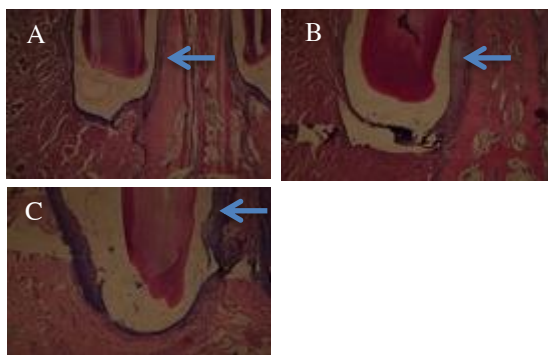
The statistical hypothesis was conducted with a standard analytic significance of 95 percent ( $P = 0.05$ ) by using SPSS. The statistical results showed that there were significant differences among all of the groups. The statistical results of one way Anova test and LSD test showed that there were significant differences of the periodontal ligament size in the tension site (Figure 1) between the orthodontic group and the HBO group ( $p < 0.005$ ). The periodontal ligament size in the tension site of treatment group decreased with 1.856, thickness decreases, approaching normal size to control group (Figure 2).

**Table 1.** The size of periodontal ligament observed in the control, orthodontic and HBO groups (mm)

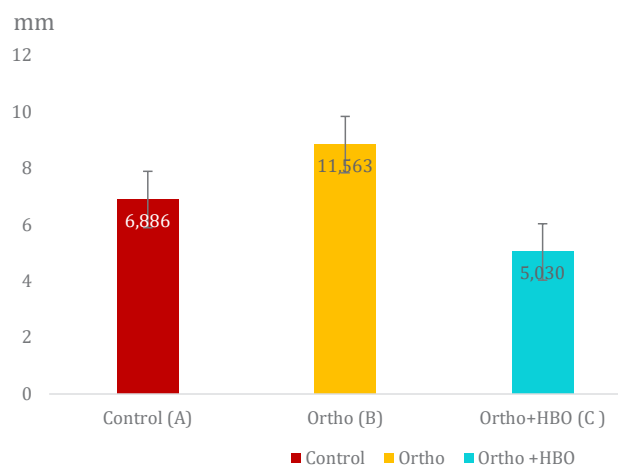
| Groups            | Mean ± SD      |
|-------------------|----------------|
| Control           | 6.886 ± 2.572  |
| Orthodontic       | 11.563 ± 8.831 |
| Orthodontic + HBO | 5.030 ± 3.411  |

**Table 2.** The number of Osteoblasts found in the control, orthodontic and HBO groups (cell/field of view)

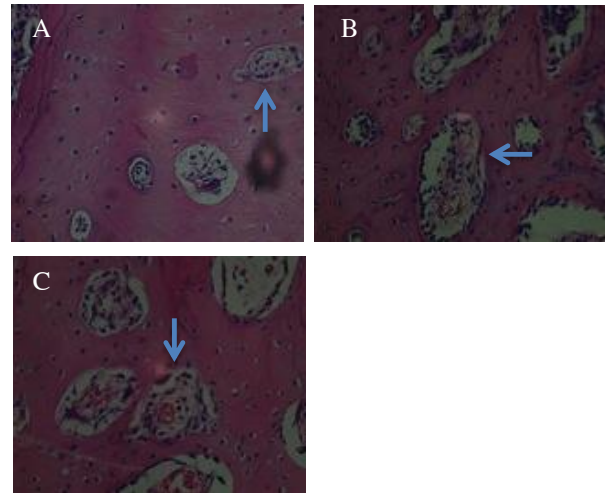
| Groups           | Mean ± SD      |
|------------------|----------------|
| Control          | 13.142 ± 5.573 |
| Orthodontic      | 4.833 ± 1.602  |
| Orthodontic +HBO | 14.571 ± 6.320 |



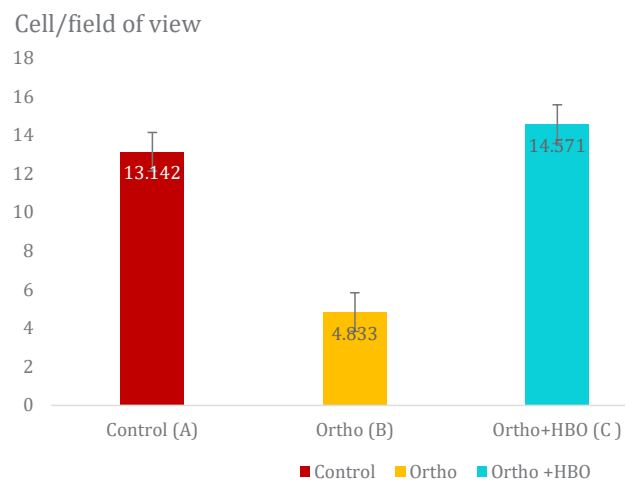
**Figure 1.** Histological section of ligament periodontal in the control group (A), in the orthodontic group (B), and in the Orthodontic + HBO group (C) with magnification 40x.



**Figure 2.** The size of ligament periodontal observed in the control group (A), in the orthodontic group (B), and in the Orthodontic + HBO group (C).



**Figure 3.** Histological section of Osteoblasts in the control group (A), in the orthodontic group (B), and in the orthodontic + HBO group (C) with magnification 400x.



**Figure 4.** The number of osteoblasts in the tension site of the control group (A), in the orthodontic group (B), and in the Orthodontic + HBO group (C).

There were also significant differences of the number of osteoblasts among all of the groups (Figure 3). The number of Osteoblast in the tension site increase with 9.74 mm, compared to K0 group (Figure 4).

**DISCUSSION**

The results showed that Group K2 given the orthodontic force + therapy at 2.4 ATA for 90 minutes in 7 days had wider periodontal ligament size in the tension site than Group K0 as the control group and Group K1 as the orthodontic group.

HBO therapy, involving the administration of 100% oxygen at atmospheric pressures greater than 1 ATA, has been proposed as an adjunctive therapy to improve the outcomes of patients suffering from bone fractures, osteoradionecrosis, and distraction osteogenesis, as well as of patients with bone grafts and dental implants.<sup>11</sup> HBO therapy can increase hemoglobin saturation with oxygen from 97% to 100%, and HBO can also increase plasma saturation with oxygen. When breathing 100% oxygen, the arterial oxygen tension is raised 6 fold when under 1 ATA, 14 fold under 2 ATA, and 22 fold under 3 ATA. It can raise tissue oxygen tension to a maximum of 500 mmHg at 3 ATA, and can also increase oxygen delivery to up to 60 ml per liter of blood. This condition is enough for the basic metabolic tissue needs of reparative tissues in the human body without hemoglobin contribution. This represents the main path of the mechanism of HBO action.<sup>12</sup>

HBO therapy has been known as a process depended on oxygen to influence cellular proliferation positively. According to Broussard *et al.*, fibroblasts cannot proliferate in tissue cultures in the absence of oxygen.<sup>10,12</sup> Thus, HBO may promote angiogenesis, which is vital for bone healing. HBO therapy might increase expression of VEGF, which is one of the key factors that stimulates angiogenesis.<sup>9</sup>

HBO therapy can increase nodules bone formation and activity in alkaline phosphatase osteoblast. The surface of alkaline phosphatase is a protein that can participate in proliferation of regulations, migration, and cell differentiation of osteoblast.<sup>10</sup> In conclusion, periodontal ligament size thickness decreases, approaching normal size and osteoblast number were increased during tooth movement in the tension site due to the provision of HBO therapy 2.4 ATA for 90 minutes in 7 days.

## REFERENCES

- Alfaqeeh SA, Anil S. Lactate dehydrogenase activity in gingival crevicular fluid as a marker in orthodontic tooth movement. *Open Dent J* 2011; 5: 1059.
- Alghamdi Moh YM. The effect of hyperbaric therapy on bone distant from sites of surgery. Thesis. Toronto: Department of Dentistry University of Toronto; 2011.
- Bildt MM, Bloemen M, Kuijpers-Jagtman AM, Von den Hoff JW. Matrix metal- loproteinase inhibitors reduce collagen gel contraction and  $\alpha$ -smooth muscle actin expression by periodontal ligament cells. *J Periodontal Res* 2009; 44(2): 266–74.
- Wu D, Malda J, Crawford R, Xiao Y. Effects of hyperbaric oxygen on proliferation and differentiation of osteoblasts from human alveolar bone. *Connect Tissue Res* 2007; 48(4): 206-13.
- Flavio U, Zhana K, John B, Ravindra N, Christopher O, David R, Sunil W. Early effects of orthodontic forces on osteoblast differentiation in a novel mouse organ culture model. *Angle Orthodontist* 2011; 81(2): 284–91.
- Gokce S, Bengi O, Akin E, Karacay S, Sagdic D, Kurcu M, Gocke HS. Effects of hyperbaric oxygen during experimental tooth movement. *Angle Orthod* 2007; 78(2): 306-8.
- Kaya FA, Hamamci N, Basaran G, Dogru M, Yildirim TT. TNF- $\alpha$ , IL-1 and IL-8 levels in tooth early leveling movement orthodontic treatment. *Journal of International Dental and Medical Research* 2010; 3: 116-21.
- Khrisnan V, Davidovitch Z. Cellular, molecular and tissue-level reaction to orthodontic force. *Am J Orthod Dentofacial Orthop* 2006; 129(4): 469.e1-32.
- Niklas A, Proff P, Gosau M, Römer P. The role of hypoxia in orthodontic tooth movement. *Int J Dent* 2013; 2013: 841840.
- Wise GE, King GJ. Mechanisms of tooth eruption and orthodontic tooth movement. *J Dent Res* 2008; 87(5): 414-34.
- Wu Y, Cao H, Yang Y, Zhou Y, Gu Y, Zhao X, Zhang Y, Zhao Z, Zhang L, Yin J. Effects of vascular endothelial cells on osteogenic differentiation of noncontact co-cultured periodontal ligament stem cells under hypoxia. *J Periodontal Res* 2013; 48(1): 52-65.
- Fok TCO, Jan A, Peel SAF, Evans AW, Clokie CML, Sándor GKB. Hyperbaric oxygen results in increased vascular endothelial growth factor (VEGF) protein expression in rabbit calvarial critical-sized defects. *Oral Surg Oral Med Oral Pathol Oral Radiol Endod* 2008; 105(4): 417-22.