

## Efficacy of topical hydrogel *Epigallocatechin-3-gallate* against neutrophil cells in perforated dental pulp

Kun Ismiyatin, Ari Subiyanto, Michelle Suhartono, Paramita Tanjung Sari, Olivia Vivian Widjaja and Ria Puspita Sari  
Department of Conservative Dentistry,  
Faculty of Dental Medicine, Universitas Airlangga  
Surabaya – Indonesia

### ABSTRACT

**Background:** One cause of pulpitis is mechanical trauma such as pulp perforation. The emergency treatment of pulpitis in a clinic uses eugenol. Eugenol in a high concentration causes cytotoxicity, which causes local necrosis and inhibits the recovery process, while in lower doses it can cause oral mucosal hypersensitivity. Due to these side effects, it is worth considering other biocompatible materials with minimal side effects, such as epigallocatechin-3-gallate (EGCG), which is found in green tea. As a polyphenol, EGCG has a radical scavenging ability, which has an effect on reducing the number of neutrophils. The application of EGCG is expected to reduce neutrophils on the second day after injury so the rehabilitation process is completed more quickly and ongoing inflammation and pulp necrosis is prevented. **Purpose:** To analyse the efficacy of topical hydrogel EGCG in reducing the number of neutrophils after 48 hours in the perforated dental pulp of Wistar rats. **Methods:** 20 Wistar rats were divided equally into four groups, which were designated control (C) and treatment groups (T1, T2, T3). The upper first molar teeth of each rat were perforated and then T1, T2, and T3 were given 60 ppm, 90 ppm and 120 ppm hydrogel EGCG respectively. On the second day, the rats were sacrificed. HPA preparations were made to calculate the number of neutrophils in each group. Data was analysed using Kolmogorov–Smirnov, Levene's, one-way ANOVA and Tukey HSD test ( $p < 0.05$ ). **Results:** There were significant differences between T2 and T3 compared with C and T1 ( $p < 0.05$ ), but no significant differences in the comparison of T1 with C and of T2 with T3 ( $p > 0.05$ ). **Conclusion:** 90 ppm hydrogel EGCG is effective in reducing the number of neutrophils in the perforated dental pulp of Wistar rats.

**Keywords:** epigallocatechin-3-gallate (EGCG); inflammation; neutrophil; pulp perforation

**Correspondence:** Kun Ismiyatin, Department of Conservative Dentistry, Faculty of Dental Medicine, Universitas Airlangga, Jl. Mayjen. Prof. Dr. Moestopo 47, Surabaya 60132, Indonesia. Email: kun-is@fkg.unair.ac.id

### INTRODUCTION

According to the Indonesian Health Profile of 2010, pulpitis was seventh out of the top ten causes of outpatient care in hospitals in Indonesia and dental pulp treatment had the highest rate compared to other dental treatments.<sup>1</sup> According to the American Association of Endodontics (AAE) 2013, reversible pulpitis is a dental pulp inflammation that should be resolved and the pulp return to normal following appropriate management of the etiology. One of the treatments is excavation of the infected tissue, which can cause mechanical trauma such as iatrogenic errors. Pulpal perforation due to iatrogenic

errors occurs in approximately 2–12% of teeth receiving endodontic treatment.<sup>2,3</sup> Inflammation that continues to be chronic can cause failure in the tissue and this can lead to pulp necrosis.<sup>4</sup> Neutrophils are the first immune cells that arrive to lesions<sup>5</sup> and will undergo apoptosis after 1–2 days.<sup>6</sup> If neutrophils remain in injured tissue then the transition of proinflammatory M1 phenotype macrophages (classically activated macrophages) to reparative M2 phenotype macrophages (alternatively activated macrophages) will be inhibited, resulting in the slowing of the tissue-repair process by the reparative M2. At the site of infection or injury, neutrophil cells recognise and phagocyte microbes, then kill pathogens

through cytotoxic damage. This method instigates the production of reactive oxygen species (ROS) as well as the release of antimicrobial peptides.<sup>7</sup> Emergency treatment of pulpitis currently uses eugenol with concentrations of up to 74.3%.<sup>8</sup> Eugenol can have cytotoxic effects and also adversely affects fibroblast cells and osteoblasts, which causes local necrosis and inhibits the healing process. While at lower doses, eugenol can cause hypersensitivity reactions in the oral mucosa, inducing contact stomatitis and contact dermatitis.<sup>9</sup>

In view of these side effects, it is important to consider the use of other biocompatible materials with minimal side effects, such as the epigallocatechin-3-gallate (EGCG) in green tea. EGCG is the most concentrated polyphenol in green tea, which makes up around 50–80% of the total catechins.<sup>10</sup> As a polyphenol, the structure of EGCG has eight -OH groups.<sup>11</sup> With more -OH groups, EGCG is expected to be more effective in reacting with and binding to ROS compared to eugenol, causing a more effective radical scavenging. The more effective radical scavenging is expected to lead to a faster decrease in the number of neutrophils that move toward the affected tissue, meaning the inflammatory and healing processes can be completed more quickly. EGCG has been shown to affect several cellular mechanisms, including inflammation. EGCG in cells inhibits neutrophil migration through endothelial cells and decreases the number of oxidative stress markers.<sup>12</sup> In the pulpal inflammation of a rat tooth, topical 0.01% and 0.1% EGCG were shown to inhibit pain distribution.<sup>13</sup> As a polyphenol, EGCG has a radical scavenging ability to clear ROS, either directly by reacting with ROS or indirectly by regulating the pathways that control the clearance of ROS and enzymes.<sup>14</sup> The study was carried out with the consideration that pure EGCG is toxic to gingival fibroblast cells at a concentration of 150  $\mu$ M, which is equal to 68.7 ppm.<sup>15</sup>

In general, hydrogels are used as a drug delivery system because of their ability to regulate drug release, protect drug contents from the outside environment<sup>16</sup> and effectively disperse.<sup>17</sup> In dental pulp regeneration therapy, hydrogel preparations can induce the release of fibroblast growth factor-2 (FGF-2) gradually and continuously.<sup>18</sup> The most commonly used gel base in hydrogel preparations is polyethylene glycol (PEG).<sup>16</sup> PEG is a hydrophilic polymer with low toxicity, immunogenicity and antigenicity but with excellent biocompatibility. The basic property of PEG is hydrophilic, which makes PEG the best choice of polymer for the hydrogel base.<sup>19</sup> The good biocompatibility of PEG leads to a better maintenance of cell viability.<sup>20</sup> Until now, there has been no research conducted to examine the concentration of topical hydrogel EGCG that is effective in reducing the number of neutrophil cells as acute inflammatory cells in the dental pulps which are given lesions until perforated. This study was conducted to examine the effect of 60 ppm, 90 ppm, and 120 ppm hydrogel EGCG application on the number of neutrophil cells in a tooth cavity that has been perforated.

## MATERIALS AND METHODS

Ethical clearance was approved by the Ethical Eligibility Committee of the Dentistry Faculty, Universitas Airlangga (Number: 412/HRECC.FODM/VI/2019). This study was laboratory in vivo experimental research with posttest-only control group design that used 20 healthy male Wistar rats (*Rattus norvegicus*), approximately 3 months old and weighing 200–300 grams, as animal subjects. The subjects were divided equally into four groups ( $n=5$ ): a control group (C) that received cavity preparation but no EGCG application and three treatment groups that received cavity preparation and topical application of 60 ppm (T1), 90 ppm (T2) and 120 ppm (T3) hydrogel EGCG respectively.

PEG hydrogel was produced by mixing 80% PEG 400 (Schuchardt OHG, Germany) with 20% PEG 4000 (Sigma-Aldrich, St. Louis, USA).<sup>15</sup> EGCG hydrogel was produced by mixing EGCG (Xi' An Rongsheng Biotechnology Co., Ltd., Shaanxi, China. Batch number: 190702) with 80% PEG 400 and 20% PEG 4000.

Before cavity preparation, Wistar rats were anaesthetised using a 0.2 cc intra-muscular injection of a mixture of ketamine (Kepro B.V., Deventer, Holland) and Xyla<sup>®</sup> xylazine base (PT Tekad Mandiri, Bandung, Indonesia) with a 1:1 ratio. Preparation was performed on the occlusal surface of the upper right first molar tooth using a 0.8 mm diameter round bur (Edenta<sup>®</sup>, Edenta Corp., Switzerland) at low speed until it reached the pulp.<sup>21</sup> The depth of preparation was as large as the bur head. Perforation of the pulp chamber was performed using a 0.8 mm diameter round bur (Edenta<sup>®</sup>, Edenta Corp., Switzerland). To dry the cavity and confirm the presence of bleeding, which is a sign of pulp perforation, a fine paper point (Inline<sup>®</sup>, B.M. Dentale S.a.s., Torno, Italy) was used. Waterone<sup>™</sup> saline (PT Jayamas Medica Industri, Indonesia) was used to clean up the bleeding.

EGCG hydrogel was measured using a micropipette (Acura<sup>®</sup> Manual 825, Socorex Isba SA, Switzerland) then applied using a microbrush (TPC<sup>®</sup>, TPC Advances Tech. Inc., USA) to the base of the cavity of the upper right first molar tooth in the treatment groups that had been prepared. 60 ppm, 90 ppm and 120 ppm of EGCG hydrogel were applied respectively to the T1, T2 and T3 groups. After the application, the cavities were filled with glass ionomer cement (GIC) (Fuji 9, GC Corp, Tokyo, Japan).

The Wistar rats were sacrificed 2x24 hours after completion of the treatment in order to obtain analysis specimens by surgically removing the upper right first molar tooth along with the jaw. The maxillae were then fixed with 10% buffered formalin (Polysciences, Polysciences Inc., USA) and decalcified using 10% ethylen diamine tetraacetic acid (EDTA) (RPI, RPI Corp., USA) at pH 7.4 with the solution being replaced every three days during 30 days of immersion at room temperature. The samples were taken from the dental pulp of the teeth. The specimens were dehydrated by soaking in stratified alcohol followed by

the purifying material. Next, the specimens were placed into xylol-paraffin (1:1), followed by pure paraffin I, pure paraffin II and pure paraffin III for 60 minutes each. Pure paraffin was poured into the box, up to the brim, without any air bubbles inside the paraffin block. The specimen was then inserted into the paraffin block using pointed tweezers. The tissue position was arranged so that when the block was cut it would provide longitudinal pieces. After the paraffin block hardened, a 6  $\mu$ m thick paraffin slice was cut to be painted with hematoxylin eosin (HE) staining.

Observation of the number of neutrophils in each specimen was carried out using a light microscope (Olympic, USA) under 400x magnification and then a photo preparation was made. Calculation of the number of neutrophil cells was carried out in the area under the cavity preparation with eight different fields of view and counting was performed manually through photos with the help of ocular micrometer (graticule). The results were divided into eight, according to the number of fields of view, to obtain the average number of neutrophil counts for each sample in each group. Total calculation of the average for

each sample in each group was then divided by the number of samples in each group to obtain the average number of neutrophils in each group. The averages and the standard deviation of the study were calculated. All the data obtained was analysed with the Statistical Package for the Social Sciences (SPSS) version 20 (IBM, New York, USA), using the Kolmogorov-Smirnov test to find out whether the data was normally distributed. After confirming that the data was normally distributed, Levene's test was used to evaluate homogeneity. A one-way ANOVA was then carried out, followed by a Tukey HSD test to determine significant differences between groups. Significant differences were considered to be present in  $p < 0.05$ .

## RESULTS

The data in Table 1 shows the mean and the standard deviation (SD) of neutrophil cells in the control and treatment groups. The expression of neutrophil cells can be seen in Figure 1. The results of normality and homogeneity

**Table 1.** The mean number ( $\bar{x}$ ) and standard deviation (SD) of neutrophil cells in each control and treatment group.

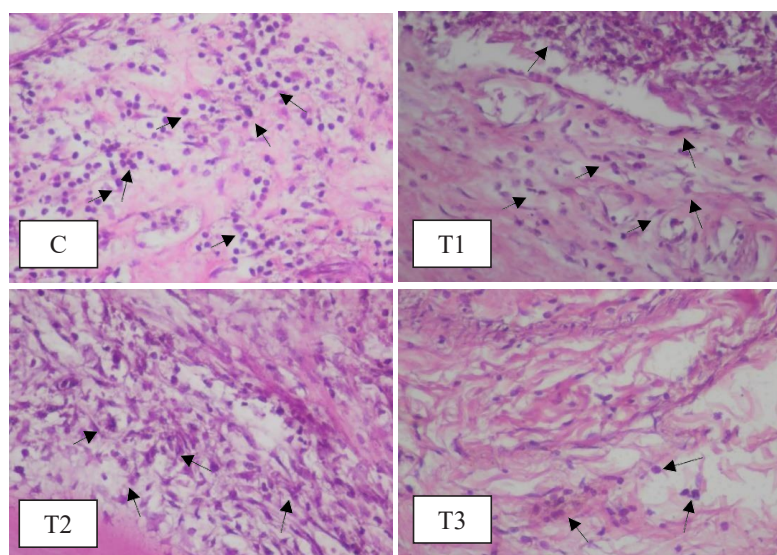
Groups	n	Mean and SD ( $\bar{x} \pm$ SD)
C	5	11 $\pm$ 1
T1	5	11 $\pm$ 1.225
T2	5	7.2 $\pm$ 0.837
T3	5	6.2 $\pm$ 0.837

Notes: n= number of samples; C= given injury but not given any treatment; T1= treated with 60 ppm hydrogel EGCG; T2= treated with 90 ppm hydrogel EGCG; T3= treated with 120 ppm hydrogel EGCG.

**Table 2.** Tukey HSD test results of neutrophil cells between groups.

	C	T1	T2	T3
C		1.000	0.000*	0.000*
T1			0.000*	0.000*
T2				0.406
T3				

Notes: \*= significantly different; C= given injury but not given any treatment; T1= treated with 60 ppm hydrogel EGCG; T2= treated with 90 ppm hydrogel EGCG; T3= treated with 120 ppm hydrogel EGCG.



**Figure 1.** Expression of neutrophil cells in HPA preparation with 400x magnification. The black arrows indicate positive expressions. C group was given injury but not given any treatment, T1 group was treated with 60 ppm hydrogel EGCG, T2 group was treated with 90 ppm hydrogel EGCG and T3 group was treated with 120 ppm hydrogel EGCG.

tests showed that the data was normally distributed and homogeneous so that it fulfilled the requirements for parametric tests using one-way ANOVA. The one-way ANOVA test results showed that there were significant differences in the number of neutrophils between groups ( $p < 0.05$ ). The Tukey HSD test (Table 2) was then carried out to investigate significant differences between groups and it showed that there was no significant difference ( $p > 0.05$ ) in the decrease of neutrophil cells between C group and T1 group. The neutrophil cells were significantly lower ( $p < 0.05$ ) in groups T2 and T3 than in the groups C and T1, but there was no significant difference ( $p > 0.05$ ) in the decrease of neutrophil cells between T2 group and T3 group.

## DISCUSSION

In the inflammatory process, nitric oxide (NO) triggers the formation of reactive radical species through chemical reactions with oxygen. In the first 48 hours, NO mainly has a role in vasodilation, antimicrobial activity, antiplatelet aggregation activity and in the induction of vascular permeability.<sup>22</sup> NO can cause vasodilation so that inflammatory cells, including neutrophils as acute inflammatory cells, migrate towards injury.<sup>23,24</sup>

EGCG extract, which was used in this study, is a polyphenol that acts as a radical scavenger. NO, which is a free radical, also binds to the -OH groups of EGCG. Furthermore, EGCG as an anti-inflammatory inhibits the activation of nuclear factor- $\kappa$ B (NF- $\kappa$ B) and activator protein-1 (AP-1), thereby reducing inducible nitric oxide synthesis (iNOS) expression. The application of EGCG in lesions also has the effect of inhibiting the production of iNOS, which is induced by interleukin- $1\beta$  (IL- $1\beta$ ) and interferon- $\gamma$  (IFN- $\gamma$ ), and decreasing mRNA iNOS and protein iNOS, causing a decrease in NO expression in blood vessels.<sup>25</sup> A previous study showed that various cells could express IL-6 and IL-8, both of which are believed to participate in tissue injury related to inflammation or neutrophils.<sup>26</sup> This results in vasoconstriction of blood vessels, which in turn results in capillary permeability decrease, so that the migration of neutrophil cells into the affected tissue is inhibited and the number of neutrophil cells that reach the affected tissue is reduced, causing the acute phase of inflammation to end more quickly. Modulation of the decrease in neutrophil cells facilitates the safe clearance of neutrophils from lesions, which is through macrophage cells, which happens within a few days, with minimal damage to tissue. This is beneficial because the mobilisation and ongoing activity of neutrophils can trigger chronic pathological responses.<sup>12</sup> It was found that administration of EGCG extract can reduce the number of neutrophil cells in the dental pulp of Wistar rats that have perforated tooth cavities. When compared to the control group, significant reduction in neutrophils was found in

the group that was given 90 ppm hydrogel EGCG and the group that was given 120 ppm hydrogel EGCG.

Significant differences between the number of neutrophils in the control group and the groups that were given 90 ppm and 120 ppm hydrogel EGCG showed that there was a decrease in the number of neutrophil cells toward the lesion in the groups that were given 90 ppm and 120 ppm hydrogel EGCG. The results of this study are in line with the previous study that stated that EGCG with higher concentrations has a greater antioxidant activity than EGCG with lower concentrations. In that study, the comparison was between 100 ppm EGCG and 50 ppm EGCG in the form of emulsion.<sup>27</sup> A decrease in the number of neutrophil cells present at an injury can lead to an increase in neutrophil apoptosis, which can shorten the inflammatory process and minimise tissue damage.<sup>28</sup> However, the group that was given 60 ppm hydrogel EGCG did not experience a significant decrease in neutrophils compared to the control group, which suggests that 60 ppm hydrogel EGCG was not concentrated enough to effectively perform radical scavenging activities.

If the number of hydroxyl groups increases, the radical scavenging will become stronger.<sup>11</sup> Therefore, there was a significant decrease in the number of neutrophil cells in the group given 90 ppm and the group given 120 ppm hydrogel EGCG compared to the control group. There was no significant decrease in neutrophils in the group that was given 120 ppm hydrogel EGCG compared to the group that was given 90 ppm hydrogel EGCG. But an insignificant difference between the groups that were given 90 ppm and 120 ppm hydrogel EGCG was shown by the number of neutrophils in the same amount. This shows that hydrogel EGCG at a concentration of 90 ppm is effective in reducing the number of neutrophil cells in the perforated dental pulp of Wistar rats and increasing the number of neutrophils is almost the same as 120 ppm hydrogel EGCG. This is possibly related to the EGCG saturated concentration binding to PEG<sup>29</sup> and the self-oxidation properties of EGCG. In the mixture of EGCG with PEG, sediment is produced due to the bond between EGCG and the polymer that produces colloids and aggregates. Colloids increase the difficulty in formulation and reduce the efficacy of polyphenols.<sup>30</sup> Several studies have shown that high concentrations of EGCG can cause self-oxidation and function as pro-oxidants by producing hydroxyl radicals, hydrogen peroxide and quinonoid intermediates, which cause cytotoxicity. The study by Chen *et al.*<sup>31</sup> found that catechol-quinone produced by self-oxidation of EGCG and EGC can crosslink with erythrocyte membrane proteins as a crosslinking link, thus leading to membrane protein aggregates; the galloyl group is an important group of catechins that have a pro-oxidative effect. Furthermore, in physiological concentrations (1–2  $\mu$ M to 10  $\mu$ M), EGCG can produce a small number of reactive oxygen species to activate several signalling pathways and generate appropriate cellular protection mechanisms, thus

presenting an antioxidant effect.<sup>32</sup> The biological effects of EGCG are likely to be related to its metabolic product.<sup>33</sup> The pro-oxidant effect of EGCG can result in neutrophil infiltration.<sup>34</sup>

This study proves that the application of EGCG on the dental pulp in the perforated tooth cavity of Wistar rats can cause a decrease in the number of neutrophil cells on the second day after the administration to a mechanical trauma lesion. However, the limitation of this study is that it was conducted on Wistar rats. Further studies need to be done before clinical application can be conducted.

## REFERENCES

- Kementerian Kesehatan Republik Indonesia. Profil Kesehatan Indonesia 2010. Jakarta: Kementerian Kesehatan Republik Indonesia; 2011. p. 1–220.
- Tesis I, Fuss Z. Diagnosis and treatment of accidental root perforations. *Endod Top*. 2006; 13(1): 95–107.
- Widjiastuti I, Subiyanto A, Ningtyas EK, Popyandra R, Kurniawan MG, Retnaningsih FD. Propolis extract as pulp capping material enhances odontoblast-like cell thickness and type I collagen expression (in vivo). *Dent J (Majalah Kedokt Gigi)*. 2020; 53(1): 1–5.
- Garg N, Garg A. Textbook of endodontics. New Delhi: Jaypee Brothers Medical Publishers; 2010. p. 59–60.
- Greenlee-Wacker MC. Clearance of apoptotic neutrophils and resolution of inflammation. *Immunol Rev*. 2016; 273(1): 357–70.
- Kristanti S, Hendrianingtyas M. Hubungan neutrophils/lymphocytes ratio dan c-reactive protein pada infeksi neonatal. *J Nutr Heal*. 2017; 5(3): 187–94.
- Mayadas TN, Cullere X, Lowell CA. The multifaceted functions of neutrophils. *Annu Rev Pathol Mech Dis*. 2014; 9(1): 181–218.
- Bendre RS, Rajput JD, Bagul SD, Karandikar PS. Outlooks on medicinal properties of eugenol and its synthetic derivatives. *Nat Prod Chem Res*. 2016; 4(3): 1–6.
- Deshpande A, Verma S, Macwan C. Allergic reaction associated with the use of eugenol containing dental cement in a young child. *Austin J Dent*. 2014; 1(2): 1–3.
- Dewi K. Pengaruh ekstrak teh hijau (*Camellia Sinensis* var. *Assamica*) terhadap penurunan berat badan, kadar trigliserida dan kolesterol total pada tikus jantan galur Wistar. *J Kedokt Maranatha*. 2008; 7(2): 1–11.
- Singh BN, Shankar S, Srivastava RK. Green tea catechin, epigallocatechin-3-gallate (EGCG): Mechanisms, perspectives and clinical applications. *Biochem Pharmacol*. 2011; 82(12): 1807–21.
- Donà M, Dell'Aica I, Calabrese F, Benelli R, Morini M, Albini A, Garbisa S. Neutrophil restraint by green tea: Inhibition of inflammation, associated angiogenesis, and pulmonary fibrosis. *J Immunol*. 2003; 170(8): 4335–41.
- Ismiyatin K, Soetoyo A, Wahlujo S, Safitri I. Therapeutic efficacy of topical epigallocatechin-gallate as a new therapeutic strategy for inhibition of pain conduction on rat models with acute pulpal inflammation. In: International Medical Device and Technology Conference. Johor Bahru: Universiti Teknologi Malaysia; 2017. p. 107–10.
- Shay J, Elbaz HA, Lee I, Zielske SP, Malek MH, Hüttemann M. Molecular mechanisms and therapeutic effects of (-)-epicatechin and other polyphenols in cancer, inflammation, diabetes, and neurodegeneration. *Oxid Med Cell Longev*. 2015; 2015: 1–13.
- Weisburg JH, Weissman DB, Sedaghat T, Babich H. In vitro cytotoxicity of epigallocatechin gallate and tea extracts to cancerous and normal cells from the human oral cavity. *Pharmacol Toxicol*. 2004; 95(4): 191–200.
- Ismiyatin K, Wahlujo S, Purwanto DA, Rahayu RP, Soetoyo A, Mukono IS. Effect of topical epigallocatechin-gallate on lipopolysaccharide-induced pulpal inflammation in rat models. *Iran Endod J*. 2018; 13(4): 528–33.
- Setiawan I, Lindawati NY, Amalia B. Formulasi dan uji antiinflamasi sediaan hidrogel ekstrak jahe merah. *Media Farm Indones*. 2018; 13(1): 1330–4.
- Silna EA, Krishnakumar K, Nair SK, Narayanan A V, Dineshkumar B. hydrogels in topical drug delivery - a review. *Int J Innov Drug Discov*. 2016; 6(2): 87–93.
- Srivastava A, Yadav T, Sharma S, Nayak A, Kumari A, Mishra N. Polymers in drug delivery. *J Biosci Med*. 2016; 4: 69–84.
- Zavisova V, Koneracka M, Kovac J, Kubovcikova M, Antal I, Kopcansky P, Bednarikova M, Muckova M. The cytotoxicity of iron oxide nanoparticles with different modifications evaluated in vitro. *J Magn Magn Mater*. 2015; 380: 85–9.
- Sabir A, Tabbu CR, Agustiono P, Sosroseno W. Histological analysis of rat dental pulp tissue capped with propolis. *J Oral Sci*. 2005; 47(3): 135–8.
- Broughton G, Janis JE, Attinger CE. The basic science of wound healing. *Plast Reconstr Surg*. 2006; 117(7 Suppl): 12S-34S.
- Enggardipta RA, Haniastuti T, Handajani J. Efek eugenol terhadap jumlah sel inflamasi pada gigi molar tikus Sprague Dawley. *Maj Kedokt Gigi Indones*. 2016; 2(2): 66–73.
- Dwiandhono I, Effendy R, Kunarti S. The thickness of odontoblast-like cell layer after induced by propolis extract and calcium hydroxide. *Dent J (Majalah Kedokt Gigi)*. 2016; 49(1): 17–21.
- Han MK. Epigallocatechin gallate, a constituent of green tea, suppresses cytokine-induced pancreatic  $\beta$ -cell damage. *Exp Mol Med*. 2003; 35(2): 136–9.
- Erdemir EO, Hendek MK, Keceli HG, Apan TZ. Crevicular fluid levels of interleukin-8, interleukin-17 and soluble intercellular adhesion molecule-1 after regenerative periodontal therapy. *Eur J Dent*. 2015; 9(1): 60–5.
- Liu TT, Yang TS. Effects of water-soluble natural antioxidants on photosensitized oxidation of conjugated linoleic acid in an oil-in-water emulsion system. *J Food Sci*. 2008; 73(4): C256–61.
- McCracken JM, Allen LAH. Regulation of human neutrophil apoptosis and lifespan in health and disease. *J Cell Death*. 2014; 7(1): 15–23.
- Peter B, Farkas E, Forgacs E, Saftics A, Kovacs B, Kurunczi S, Szekacs I, Csampai A, Bosze S, Horvath R. Green tea polyphenol tailors cell adhesivity of RGD displaying surfaces: multicomponent models monitored optically. *Sci Rep*. 2017; 7: 1–16.
- Cao Y, Teng J, Selbo J. Amorphous solid dispersion of epigallocatechin gallate for enhanced physical stability and controlled release. *Pharmaceuticals*. 2017; 10(4): 1–17.
- Chen R, Wang JB, Zhang XQ, Ren J, Zeng CM. Green tea polyphenol epigallocatechin-3-gallate (EGCG) induced intermolecular cross-linking of membrane proteins. *Arch Biochem Biophys*. 2011; 507(2): 343–9.
- Yang H, Guo J, Deng D, Chen Z, Huang C. Effect of adjunctive application of epigallocatechin-3-gallate and ethanol-wet bonding on adhesive-dentin bonds. *J Dent*. 2016; 44: 44–9.
- Chu C, Deng J, Man Y, Qu Y. Green tea extracts epigallocatechin-3-gallate for different treatments. *Biomed Res Int*. 2017; 2017: 1–9.
- Goodin MG, Bray BJ, Rosengren RJ. Sex- and strain-dependent effects of epigallocatechin gallate (EGCG) and epicatechin gallate (ECG) in the mouse. *Food Chem Toxicol*. 2006; 44(9): 1496–504.