

## Comparison of maxillary sinus on radiograph among males and females

Rona Aulianisa<sup>1</sup>, Rini Widyaningrum<sup>2</sup>, Isti Rahayu Suryani<sup>2</sup>, Rurie Ratna Shantiningsih<sup>2</sup> and Munakhir Mudjosemedi<sup>2</sup>

<sup>1</sup>Faculty of Dentistry, Universitas Gadjah Mada, Yogyakarta, Indonesia

<sup>2</sup>Department of Dentomaxillofacial Radiology, Faculty of Dentistry, Universitas Gadjah Mada, Yogyakarta, Indonesia

### ABSTRACT

**Background:** An obstacle in forensic odontology is an incomplete body caused by post-mortem damage. The problem can be solved by using lateral cephalometric radiographs for victim identification. Sex determination can be performed on the maxillary sinus, which is the largest among the paranasal sinuses. **Purpose:** This study aims to analyse the maxillary sinuses' width and height on lateral cephalometric radiographs among male and female subjects. **Methods:** The study samples were 60 lateral cephalometric radiographs (30 males and 30 females) between the ages of 20 and 40, with complete permanent dentition (or third molar absence). The height and the width of maxillary sinus measurement were performed using measurement tools of EzDent-i Vatech Software. **Results:** The average width of the maxillary sinus on males was  $40.60 \pm 1.56$  mm, and the height was  $35.02 \pm 2.09$  mm, while the width and the height on females were  $36.93 \pm 1.30$  mm and  $29.72 \pm 1.76$  mm, respectively. The independent t-test reveals a significant difference ( $p < 0.05$ ) between males and females, both in the maxillary sinus's width and height on the lateral cephalometric radiograph. **Conclusion:** The maxillary sinus in males is larger than in females, it opening up possibilities for disaster victim identification.

**Keywords:** cephalometric; maxillary sinus; sex estimation; width; height

Correspondence: Rona Aulianisa, Faculty of Dentistry, Universitas Gadjah Mada. Jl. Denta 1, Sekip Utara, Yogyakarta 55281, Indonesia. Email: rona.a@mail.ugm.ac.id

### INTRODUCTION

Indonesia is a country most vulnerable to natural disasters and is at risk from numerous mortality-related hazards.<sup>1</sup> Disaster victim identification in human-made and natural disasters requires ante-mortem and post-mortem medical record comparisons. Dental records play an essential part in the identification of bodies.<sup>2,3</sup> One of the pressing issues in body identification is sex estimation, which can be achieved using either morphological or metric methodologies of the maxillary sinus. The bones for sex estimation, especially the pelvis and cranium, are particularly valuable when the body has been incinerated or has decayed. Research and reports show the maxillary sinus remains unaffected even after burns and significant injuries.<sup>4</sup> The maxillary sinus is also the largest sinus of the paranasal sinus and, therefore, easy to analyse.<sup>4,5</sup>

The maxillary sinus can be analysed using 2D and 3D radiographs.<sup>6</sup> Lateral cephalometric radiograph is one of

the 2D radiographs showing the maxillofacial complex such as teeth, soft tissue, the relation of maxilla and mandible, and another part of the cranium comprising the maxillary sinus.<sup>7,8</sup> This radiograph is commonly used in assessing, planning, and evaluating orthodontic treatments. It is also used in growth analysis, morphological analysis, and treatment analysis of orthognathic surgeries.<sup>8</sup> For sex determination, the maxillary sinus's combined width and height can be used when the entire skeleton is unavailable. Sex determination are generally based on findings of dimorphism between males and females in most human bones. Previous studies reveal the maxillary sinus is larger in males than in females in the current human population.<sup>2,4,9</sup> The purpose of this study was to analyse the difference in the maxillary sinus' width and height between male and female subjects using a lateral cephalometric radiograph in the Prof. Soedomo Dental Hospital of Universitas Gadjah Mada, Yogyakarta, Indonesia.

## MATERIALS AND METHODS

The Ethics Committee approved the protocol for this study [Faculty of Dentistry Universitas Gadjah Mada (Ref. 00332/KKEP/FGK-UGM/EC/2020)]. The study sample comprised 60 lateral cephalometric radiographs collected from 30 males and 30 females 20–40 years old. Only lateral cephalometric radiographs from patients with complete permanent dentition were included in this study. However, the samples from patients with missing the third molar were also included. All samples were diagnostically acceptable and presented images of the completely formed maxillary sinus in adequate contrast and density, especially on the facial surface of the maxilla, infraorbital bone, and alveolar process of the maxilla. The quality assessment was conducted by a trained observer and calibrations were made under a radiologist. The radiographic image's features of the maxillary sinus bearing pathologies or abnormalities were excluded. Samples were obtained from the department of dentomaxillofacial radiology in Prof. Soedomo Dental Hospital, Universitas Gadjah Mada, Yogyakarta, Indonesia. All were generated using Vatech Pax-i PCH-2500 (Korea), 90 kV, 10 mA.

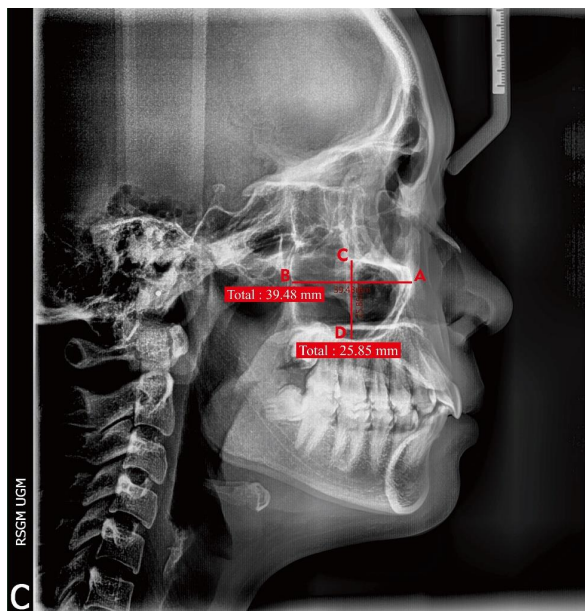
The measurements of the maxillary sinus were performed on these radiographs using EzDent-i Vatech Software (Figure 1) by utilising the grid feature available on the software. First, the width of the maxillary sinus was measured using measurement tools by drawing a horizontal line from the anterior wall of the maxillary sinus (most anterior point of the facial surface of the maxillary bone, point A in Figure 1) parallel with the horizontal plane to the posterior wall of the maxillary sinus (infratemporal surface

of the maxillary bone, point B in Figure 1). Subsequently, the height of the maxillary sinus was drawn as a vertical line perpendicular to the centre of the horizontal line. It was drawn from the cranial wall of the maxillary sinus (infraorbital bone, point C in Figure 1) to the caudal wall of the maxillary sinus (alveolar and palatine processes of the maxillary bone, point D in Figure 1). The reliability of the measurement using lateral cephalometric radiograph depends on the position of the head; hence the radiograph with the standardised head position was taken to minimise the measurement error in this study.

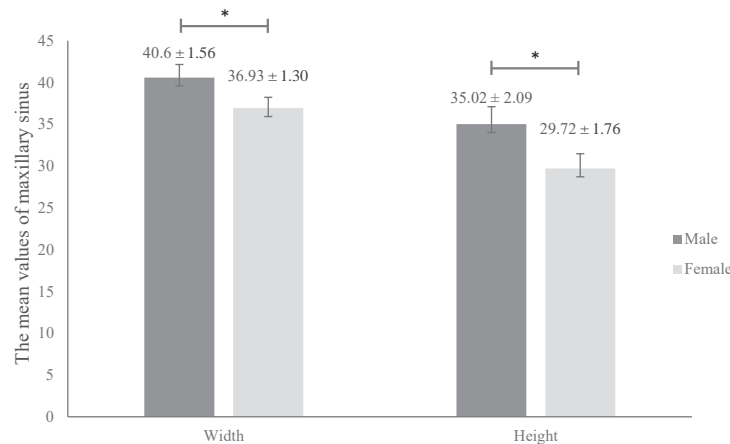
Twelve radiographs, consisting of six male subjects and six female subjects (20% of the sample), were selected at random and remeasured to determine intra- and inter-observer reliability. One observer served as the primary, and the reliability of the intra-observer was calculated between measures conducted one week apart. The reference observer with the most experience then served as another observer, and inter-observer reliability was assessed. Intra- and inter-observer reliability were recorded and calculated by using Cronbach's alpha correlation. The independent sample t-test was used to compare the maxillary sinus measurements between the two groups.

## RESULTS

In the male and female groups, the mean value for the maxillary sinus width was  $40.60 \pm 1.56$  mm and  $36.93 \pm 1.30$  mm, respectively. The male group's mean value for maxillary sinus height was  $35.02 \pm 2.09$  mm, whereas the mean height in the female group was  $29.72 \pm 1.76$  mm. The



**Figure 1.** Measurement of the width and the height of the maxillary sinus on the lateral cephalometric radiograph. The width of the maxillary sinus was measured on the horizontal line from the anterior wall (A) to the posterior wall of the maxillary sinus (B). The height of the maxillary sinus was drawn as a vertical line from the cranial wall (C) to the caudal wall of the maxillary sinus (D).



**Figure 2.** The comparison of maxillary sinus measurement between male and female groups. The data represent the mean ± SD values of the width and the height of the maxillary sinus. \* $p < 0.05$ , based on an independent sample t-test.

normality test shows the significant value of the maxillary sinus width and height, both male and female, as 0.200 ( $> 0.05$ ) and the data were normally distributed. Compared with females, the independent sample t-test showed a statistically significant ( $p < 0.05$ ) larger dimension in males (Figure 2). Based on the Cronbach's alpha correlation, the inter- and intra-observer reliability in this study showed an extremely high correlation (0.998 for maxillary sinus width and 0.995 for maxillary sinus height).

## DISCUSSION

Sex identification from the remains of human skeletons is one of the most important and difficult forensic procedures. Sex determination accuracy has been reported to be 80–90% from the long bones only, 90–95% from both the skull and the long bones, 95% from the pelvis only or the pelvis and the long bones, 98% from both the pelvis and the skull, and 100% from a skeleton. Various methods have been demonstrated for sex identification, such as DNA analysis, fingerprints, lip grooves, palatal rugae, and morphometric analysis of maxillary sinus.<sup>2,4,10</sup>

The largest paranasal sinus is the maxillary sinus, which can be observed in various shapes and sizes. The maxillary sinus also makes a major contribution to the formation of facial contours.<sup>11</sup> Variations are affected by age and sex. Result of the study reveals the width and height of the maxillary sinus in males are significantly different from those in females. Most studies demonstrate that maxillary sinuses in males are larger than those in women. These have been found in the Indian and Brazilian populations.<sup>2,12,13</sup> The result of this study was in accordance with previous studies, despite being carried out in a distinct population.

The maxillary sinus is formed by the lateral wall of the nasal cavity, the infratemporal surface of the maxilla, the facial surface of the maxilla, orbit floor, the palatine process, and the alveolar of the maxilla.<sup>11</sup> The maxillary sinus begins to develop and continue with its enlargement

after the eruption of deciduous teeth at ten weeks in utero. The maxillary sinus grows most rapidly between one to eight years old. Sinus pneumatization ceases with the completion of permanent teeth eruption by the age of 20 years. The analysis of maxillary sinus is not at all reliable when performed in prepubertal populations, and subjects included in the present study were therefore over the age of 20.<sup>12</sup>

The maxillary sinus can be assessed using both 2D and 3D radiographs. Lateral cephalometric radiograph shows a lateral view of the cranium, which provides diagnostic information for the skeletal, dental and soft tissues anatomic landmarks.<sup>4</sup> Recent literature mentions that 3D radiography, such as computed tomography and cone-beam computed tomography, provides excellent images; thus, they are more suitable as the gold standard in evaluating paranasal sinuses and craniofacial bones. These techniques are highly effective and able to provide high-definition images as well as three-dimensional information. However, they need a high radiation dosage resulting in a high cost, thus limiting accessibility and its application in the field of forensic medicine and forensic dentistry.<sup>13,14</sup>

A lateral cephalometric radiograph can be used for morphometric analysis of the maxillary sinus. It can be done using a manual or digital tracing method. The manual tracing or conventional tracing method uses tools such as sliding callipers or graded rulers. However, along with the rapid development of computer radiography, the manual tracing method has been replaced by digital tracing methods. In this study, digital tracing was used because it provides many advantages such as being more effective, efficient, easier to use and reducing personal errors in forensic analysis.<sup>15</sup>

Results reveal that the maxillary sinus in males ( $n=30$ ) were larger than in females ( $n=30$ ) on lateral cephalometric radiograph using EzDent-i Vatech Software. The software was used as a digital tracing facility connected and integrated with the X-ray machine used in the research. The width and height of the maxillary sinus in males showed

an average size of  $40.60 \pm 1.56$  mm and  $35.02 \pm 2.09$  mm, respectively, while the measurements in females were  $36.93 \pm 1.30$  mm and  $29.72 \pm 1.76$  mm, respectively (Figure 2). A previous study<sup>2</sup> conducted on 50 subjects (25 males and 25 females) in the Indian population described the mean width of male and female maxillary sinuses as 38 mm and 37.3 mm, respectively. In addition, the mean height of male and female maxillary sinuses was 30.4 mm and 28.5 mm, respectively. The maxillary sinus in males has been reported to be larger than in females. Unlike our findings, however, the difference between the two sexes was not significant.<sup>2</sup> Another previous study<sup>9</sup> comprising 80 Iranian subjects, consist of 40 males and 40 females, describe the mean width of male and female maxillary sinuses as 40.31 mm and 37.31 mm, respectively. Meanwhile, the mean height of male and female maxillary sinuses among Iranian subjects were 40.48 mm and 38.7 mm, respectively. According to the previous study, it is statistically significant, the maxillary sinus in males has been larger than in females, defining the difference between the two groups.<sup>9</sup>

The previous study<sup>16</sup> conducted on CT scan radiographs show the mean width (anteroposterior) of male and female maxillary sinuses was  $42.60 \pm 3.79$  mm and  $36.00 \pm 4.09$  mm, respectively. The mean height (superoinferior) of male and female maxillary sinuses was  $38.21 \pm 5.77$  mm and  $33.34 \pm 6.57$  mm, respectively.<sup>16</sup> It can be concluded that in males, the maxillary sinuses are larger than females, and the difference was statistically significant, as assessed in both 2D<sup>9</sup> and 3D radiographs.<sup>16</sup>

The differences between the values obtained in the several studies can be attributed to inclusion criteria, sample size, applied measurement methods, reference points, and differences in the types of radiographs assessed.<sup>9,12,16</sup> They can also be explained by the different developmental patterns of the neurocranium and viscerocranium, which are closely linked to functional tissue in a human and are affected by numerous internal and external factors.<sup>17</sup>

The internal factors include genetics, the pneumatization process of sinuses and the size of the skeleton may possibly influence the maxillary sinus. A previous study<sup>18</sup> found the skeleton's external facial measurement (palatal length, bimaxillary width, and facial length) was positively and significantly correlated with the maxillary sinus volume.<sup>18</sup> It is known males and females have significant differences in growth patterns during a pubertal growth spurt.<sup>17</sup> The duration of the pubertal spurt was longer, and the growth velocity was greater for males than for females.<sup>19</sup> In our study, the internal factor was uncontrolled because the samples were obtained from the database in our dental hospital.

The external factors during adulthood may influence the changes in maxillary sinus size, morphologic pattern, and anatomy, mainly due to the loss of teeth. A fully edentulous maxilla shows an increase in maxillary sinus volume in relation to decreased function and less bone stress that subsequently induce atrophy and degrade the surface of the maxillary sinus.<sup>20</sup> It also increased osteoclastic activity,

simultaneously with maxillary resorption, hence resulting in maxillary sinus expansion.<sup>21</sup> Teeth loss also decreases the volume and the surface of the maxillary sinus. This can be caused by the loss of minerals in the bone matrix in all directions of the maxillary sinus wall, which contracts the maxillary sinus and subsequently decreases the maxillary sinus volume.<sup>20,21</sup>

The difference in the means of maxillary sinus between males and females in our study can be used further to compare the ante-mortem and post-mortem data in forensic cases. When other methods are inconclusive, maxillary sinus in lateral cephalometric radiograph can be used for sex determination. The difference between the left or right maxillary sinuses of the same person were statistically not significant. It has been stated that while the cranium and other bones may be severely disfigured in victims who are incinerated, the maxillary sinus remains intact.<sup>9</sup>

The lateral cephalometric radiograph is one of the simplest radiographs generally used for assessment and evaluation in orthodontic treatments. Nevertheless, it has some application limitations in the forensic area because of the difficulty of placing the remains of bodies in a static position due to rigour mortis and lack of equipment in forensic laboratories.<sup>4,9</sup> The superimposition of the right and left maxillary sinus on lateral cephalometric radiograph may also affect the accuracy of the measurements.<sup>9</sup>

However, the sample in this study was obtained only from patients in Prof. Soedomo Dental Hospital. Hence, they cannot be considered a genuinely representative sample of the population to generalise the result of this study to Javanese and Indonesian peoples. Besides the fact that Indonesia is in a natural disaster-prone area and one of the most ethnically diverse societies, further studies in larger or specific ethnic populations are needed to collect data for sex estimation.

In conclusion, the maxillary sinus's width and height in males are larger than in females. The present study results suggest that maxillary sinus assessment on lateral cephalometric radiograph can be used for sex determination. Further studies can be developed with a larger number of samples to determine a discriminant function analysis to facilitate forensic analysis. Such studies are crucial to support disaster victim identification.

---

## ACKNOWLEDGEMENT

This study is part of an undergraduate thesis conducted by the first author. The authors would like to thank Rellyca Sola Gracea for her assistance during the study.

## REFERENCES

1. Yofrido FM, Harjana LT. Social-fairness perception in natural disaster, learn from Lombok: A phenomenological report. *Indones J Anesthesiol Reanim.* 2019; 1(1): 1–7.
2. Khaitan T, Kabiraj A, Ginjupally U, Jain R. Cephalometric analysis for gender determination using maxillary sinus index: a

- novel dimension in personal identification. *Int J Dent.* 2017; 2017: 1–4.
3. Interpol. Disaster victim identification. Interpol National Central Bureau. 2011. p. 1–31.
  4. Sidhu R, Chandra S, Devi P, Taneja N, Sah K, Kaur N. Forensic importance of maxillary sinus in gender determination: A morphometric analysis from Western Uttar Pradesh, India. *Eur J Gen Dent.* 2014; 3(1): 53.
  5. Spradley MK, Jantz RL. Sex estimation in forensic anthropology: skull versus postcranial elements. *J Forensic Sci.* 2011; 56(2): 289–96.
  6. Gómez O, Ibáñez O, Valsecchi A, Córdón O, Kahana T. 3D-2D silhouette-based image registration for comparative radiography-based forensic identification. *Pattern Recognit.* 2018; 83: 469–80.
  7. Badam RK, Manjunath M, Rani M. Determination of sex by discriminant function analysis of lateral radiographic cephalometry. Kailasam S, editor. *J Indian Acad Oral Med Radiol.* 2011; 23(3): 179–83.
  8. White SC, Pharoah MJ. *Oral radiology: principles and interpretation.* 7th ed. St. Louis: Mosby; 2013. p. 9, 16,17, 18, 41, 43.
  9. Abasi P, Ghodousi A, Ghafari R, Abbasi S. Comparison of accuracy of the maxillary sinus area and dimensions for sex estimation lateral cephalograms of Iranian samples. *J Forensic Radiol Imaging.* 2019; 17(June): 18–22.
  10. Nagare SP, Chaudhari RS, Birangane RS, Parkarwar PC. Sex determination in forensic identification, a review. *J Forensic Dent Sci.* 2019; 10(2): 61–6.
  11. Iwanaga J, Wilson C, Lachkar S, Tomaszewski KA, Walocha JA, Tubbs RS. Clinical anatomy of the maxillary sinus: application to sinus floor augmentation. *Anat Cell Biol.* 2019; 52(1): 17–24.
  12. Leao de Queiroz C, Terada ASSD, Dezem TU, Gomes de Araújo L, Galo R, Oliveira-Santos C, Alves da Silva RH. Sex determination of adult human maxillary sinuses on panoramic radiographs. *Acta Stomatol Croat.* 2016; 50(3): 215–21.
  13. Bangi BB, Ginjupally U, Nadendla LK, Vadla B. 3D evaluation of maxillary sinus using computed tomography: a sexual dimorphic study. *Int J Dent.* 2017; 2017: 9017078.
  14. Putri DR, Imanto M, Irianto MG. Identifikasi jenis kelamin menggunakan sinus maksilaris berdasarkan cone beam computed tomography (CBCT). *Majority.* 2018; 7(2): 232–7.
  15. Darkwah WK, Kadri A, Adormaa BB, Aidoo G. Cephalometric study of the relationship between facial morphology and ethnicity: review article. *Transl Res Anat.* 2018; 12: 20–4.
  16. Prabhat M, Rai S, Kaur M, Prabhat K, Bhatnagar P, Panjwani S. Computed tomography based forensic gender determination by measuring the size and volume of the maxillary sinuses. *J Forensic Dent Sci.* 2016; 8(1): 40–6.
  17. Przystańska A, Kulczyk T, Rewekant A, Sroka A, Jończyk-Potoczna K, Gawriołek K, Czajka-Jakubowska A. The association between maxillary sinus dimensions and midface parameters during human postnatal growth. *Biomed Res Int.* 2018; 2018: 1–10.
  18. Koppe T, Weigel C, Bärenklau M, Kaduk W, Bayerlein T, Gedrange T. Maxillary sinus pneumatization of an adult skull with an untreated bilateral cleft palate. *J Craniomaxillofac Surg.* 2006; 34(Suppl 2): 91–5.
  19. Zheng W, Suzuki K, Yokomichi H, Sato M, Yamagata Z. Multilevel longitudinal analysis of sex differences in height gain and growth rate changes in Japanese school-aged children. *J Epidemiol.* 2013; 23(4): 275–9.
  20. Möhlhenrich SC, Heussen N, Peters F, Steiner T, Hölzle F, Modabber A. Is the maxillary sinus really suitable in sex determination? A three-dimensional analysis of maxillary sinus volume and surface depending on sex and dentition. *J Craniofac Surg.* 2015; 26(8): e723-6.
  21. Jasim HH, Al-Taei JA. Computed tomographic measurement of maxillary sinus volume and dimension in correlation to the age and gender (comparative study among individuals with dentate and edentulous maxilla). *J Baghdad Coll Dent.* 2013; 25(1):87–93.