

Contemporary guided bone regeneration therapy for unaesthetic anterior peri-implantitis case

Benso Sulijaya, Sandra Olivia Kuswandani, and Yuniarti Soeroso

Department of Periodontology
Faculty of Dentistry, Universitas Indonesia
Jakarta – Indonesia

ABSTRACT

Background: Dental implant is one of an alternative solutions reconstruction therapy for missing teeth. Complication of dental implant could occurs and leading to implant failure. In order to restore the complication, surgical treatment with guided bone regeneration (GBR) is indicated. The potential use of bone substitutes is widely known to be able to regenerate the bone surrounding the implant and maintain bone volume. **Purpose:** The study aimed to demonstrate the effectiveness of implant-bone fully coverage by using sandwich technique of biphasic calcium phosphate (BCP) and demineralized freeze-dried bone allografts (DFDBA) bone substitutes combined with collagen resorbable membrane. **Case:** A 24-year-old male came with diagnosis of peri-implantitis on implant #11. Clinical finding indicated that implant thread was exposed on the labial aspect. **Case management:** After initial therapy including oral hygiene improvement performed, an operator did a contemporary GBR to correct the defect. Bone graft materials used were 40% β -tri calcium phosphate (β -TCP)-60% hydroxyapatite (HA) on the outer layer and DFDBA on the inner layer of the defect. Resorbable collagen membrane was used to cover the graft. **Conclusion:** GBR with sandwich technique could serve as one of the treatment choices for correcting an exposed anterior implant that would enhance the successful aesthetic outcome.

Keywords: guided bone regeneration; implant; bone substitute

Correspondence: Benso Sulijaya Suyono, Department of Periodontology, Building B, 2nd Floor. Faculty of Dentistry, Universitas Indonesia. Jl. Salemba Raya no. 4. Jakarta Pusat 10430, Indonesia. E-mail: bensosulijaya@gmail.com; benso.sulijaya87@ui.ac.id; Tel. (+6221) 3911502/ Fax. (+6221) 3911502.

INTRODUCTION

Peri-implantitis is one of the dental implant complications. It defines as an inflammatory condition on tissues surrounding implant characterized with loss of supporting bone and inflammation.¹ Koldslund *et al.*² did an observed in University of Oslo on 109 Canadian subjects and showed the prevalence of peri-implantitis was 11.3% to 47.1%.² Moreover, Tarnow³ stated that the average amount of bone loss in peri-implantitis was about 30% of implant length. Contrary a Tarnow, Nicolo *et al.*⁴ revealed that the incidence of peri-implantitis was lesser than most of researches.

Several studies have been conducted to cure peri-implantitis. Heitz-Mayfield *et al.*⁵ explained that generally there are two interventions, non-surgical (e.g. local and

or systemic delivery antibiotic, mechanical debridement, antiseptics, air-powder abrasive, Er:YAG laser) and surgical (regenerative treatment with or without additional regiment). Schwarz *et al.*⁶ reported that treatment with graft material and collagen membrane for peri-implantitis cases showed pocket depth reduction from 7.1 mm to 4.4 mm.

Sandwich technique of guided bone regeneration is defined as different bone allografts were used to encourage the composition of natural bone. Different layers are consisted of autograft and allograft materials.⁷ Fu *et al.*⁸ described the effectiveness of sandwich technique for augmenting bone in implant placement simultaneously. The use of GBR has been accepted as therapy modality because it reported has a predictable bone gain.

This case report aimed to demonstrate the effectiveness of implant-bone fully coverage by using sandwich technique

of biphasic calcium phosphate (BCP) (containing 40% β -tri calcium phosphate (β -TCP)-60% hydroxyapatite (HA)) and demineralized freeze-dried bone allografts (DFDBA) bone substitutes combined with collagen resorbable membrane.

CASE

A 24 year-old-male came with diagnosis of peri-implantitis on implant #11 (Figure 1). Dental history reported implant placement in last 6 months. Patient was an active smoker (6 cigarettes per day). Patient used removable partial denture made from flexible material at that moment.

From clinical examination, the operator found that patient had an average smile line and thick periodontal biotype. Periodontal parameter was evaluated and the oral hygiene index-score (OHI-s) was 1.7 (based on Silness and Loe).⁹ Pocket depth on labial was 5 mm. Bleeding on probing score was negative. Implant thread was exposed on the labial aspect. No mobility and suppuration were found.

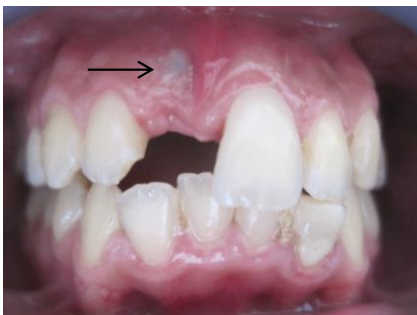

Figure 1. The implant on #11 was detected on labial aspect (seen by arrow).

Lang *et al.*,¹⁰ classified the protocol concept of cumulative interceptive supportive therapy (CIST)-modified AKUT as: stage A (pocket depth (PD) <3 mm) is indicated to mechanically cleaning and polishing; stage B (PD 4-5 mm) is indicated to mechanically cleaning with anti-infective regiments; stage C (PD>5 mm) is indicated to mechanically cleaning, microbiological test and anti-infective regiments; stage D (PD >5 mm) is indicated to respective or regenerative therapy.¹⁰ Based on that protocol, this case was categorized as stage D (pocket depth (PD) >5 mm; bone loss >2 mm) that needed a regenerative surgery.

CASE MANAGEMENT

Two weeks before surgery, patient fulfilled the initial therapy including scaling, root planing, polishing and correcting the denture. Patient also informed to use minocycline hydrochloride (minocycline HCl) 2% gargle, twice a day. Patient was also educated to reduce his smoking habit. No systemic antibiotic was given since patient had no systemic disease. A written informed consent was signed before the surgery.

Periodontal reconstructive surgery with sandwich technique of GBR was planned. Local anesthesia of 2% lidocaine (1 : 50,000 epinephrine) (INDOFARMA, Indonesia) was administrated in labial and palatal sides. Papilla preservation flap was indicated in this case. Vertical incisions were made on the 2/3 mesial angles of adjacent teeth. Full thickness flap was elevated. It noted that the second and fourth threads of implant were exposed and not covered by labial bone. The width of bone defect was estimated 3 x 5 mm width. Granulation tissue and necrotic bone were excavated. The implant surface was cleaned with plastic-made instrument. Bone decortication was made using slow-rotating small diameter bur on the cortical bone surround the implant (Figure 2).

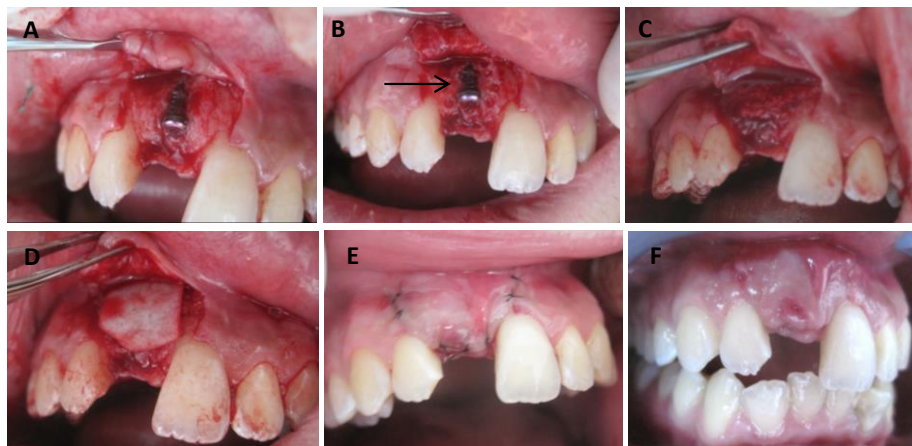


Figure 2. A) The implant thread on #11 was seen when the flap is raised. There was bone loss at the labial area. B. Implant was cleaned and de-cortication procedure was done on the bone surrounding the implant (seen by arrow); C) bone graft materials BCP was placed on the outer layer and DFDBA on the inner layer of the defect; D) collagen membrane was used to cover the graft; E) flap was repositioned back and sutured using Nylon 5.0; F) two weeks after surgery.

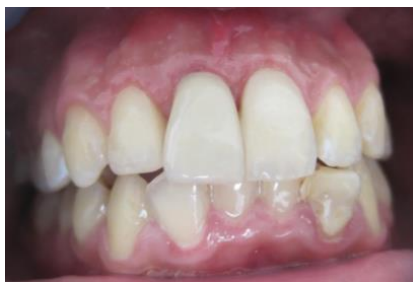

Figure 3. Twelve months follow-up post-surgery.

OSSIFI (Equinox Medical Technology B.V., Holland) bone graft materials used were biphasic calcium phosphate (BCP) (containing 40% β -tri calcium phosphate (β -TCP)-60% hydroxyapatite (HA)) on the outer layer and DFDBA (BATAN, Jakarta, West Java, Indonesia) on the inner layer of the defect. OsseoGuard (Collagen Matrix, Inc., Franklin Lakes, NJ, USA) resorbable collagen membrane was used to cover the graft. Tension-free flap was made in order to promote the healing process. Five hundred grams of paracetamol (INDOFARMA, Indonesia) was prescribed 3 times a day for 3 days as an analgesic.

Two weeks after surgery, the clinical outcome of implant-bone dehiscence was corrected and the gingiva was healthy and firm. Patient used temporary abutment screw retained crown made by using 3M ESPE Filtek Z250XT Nano Hybrid Universal (3M, ESPE, St Paul, USA) composite material. Twelve months follow-up, implant was completely healed with no sign of inflammation and no shadow of implant threads exposure (Figure 3).

DISCUSSION

Peri-implant mucositis and peri-implantitis are frequently occurred as a complication caused by an inflammatory host response.^{11,12} Mir-Mari *et al.*¹³ found 9.1% peri-implantitis cases from total 946 implants and almost 40% peri-mucositis cases in Spain. In Italy, Marrone *et al.*¹⁴ revealed 37% subjects from 103 patients from 2002 to 2012 had suffered peri-implantitis. In this particular patient, an exposed dental implant is categorized as peri-implantitis since there was a bone loss on labial side of implant #11. This complication might have happened as a result of inappropriate treatment planning and or surgical procedure. Labial bone dehiscence has risen within 6 months period after implant placement. Early detection of this condition will brighten our prediction about outcome's possibilities. Treatment option to manage peri-implantitis is depend on the situation. The goal is to discontinue further bone loss, rebuild a healthy peri-implant mucosal seal that could regenerate both hard and soft tissue-implant integration.^{8,15}

Oral hygiene improvement was done to eliminate bacterial biofilm on peri-implant surfaces. Plastic, teflon, carbon and titanium instruments are recommended to be

used in managing peri-implant diseases.¹⁶ This is because metallic instrument could roughening implant surface that directly could increase plaque retention.¹⁵ Lisa *et al.*⁵ explained that to treat peri-implantitis, it is essential to improve oral hygiene, remove prosthesis, debride non-surgically and to use of bone substitute. Surgical approach is applied after initial therapy was performed. Aims of this phase are to decontaminate implant surface, to fill the osseous defect surround the implant and also to improve soft tissue condition.¹ Rafl *et al.*¹⁶ explained that the principle of treating peri-implantitis is mainly similar with periodontitis.

Potential use of bone substitutes are widely known could regenerate the bone surrounding the implant and maintain bone volume. In some of severe bone atrophy cases that are not sufficient for implant, bone grafting procedure might be required.¹⁷ Analyzing on this case, author followed the protocol of cumulative interceptive supportive therapy (CIST) and modified into AKUT-concept produced by Lang *et al.*¹⁰ It stated that stage A (pocket depth (PD) <3 mm) was indicated to mechanically cleaning and polishing; stage B (PD 4-5 mm) was indicated to mechanically cleaning with anti-infective regiments; stage C (PD>5 mm) was indicated to mechanically cleaning, microbiological test and anti-infective regiments; stage D (PD >5 mm) was indicated to respective or regenerative therapy. Based on the stage mentioned, this case described as stage D (pocket depth (PD) >5 mm; radiology bone loss >2 mm) that need a regenerative surgery.

Bone substitutes used in this case was biphasic calcium phosphate (BCP) and DFDBA. Biphasic calcium phosphate was a mixture of an alloplastic or synthetic graft material with the composition of 40% β -tri calcium phosphate (β -TCP)-60% hydroxyapatite (HA), whereas DFDBA was an allograft that collected from human. Even though autograft is a gold standard for GBR, but both of BCP and DFDBA has a quite high osseo-inductive and osseo-conductive ability. In some studies the use of bone graft and membrane are still debate-able, but Rafl *et al.*¹⁰ have concluded that the result studies of GBR using bone graft and membrane were higher than GBR using membrane or bone graft alone. Schwarz *at al.*¹⁸ treated 22 peri-Implantitis patients randomly with open flap debridement combined with the application of nano-crystalline hydroxyapatite and collagen membrane. He stated that there was no significant differences were found.

The combination of alloplastic, allograft and or xenograft material could substitute and mimic the characteristic of autologous graft.¹⁶ Wang *et al.*⁷ explained that sandwich technique could be used to improve the composition of native bone. Autograft layer is placed over the exposed implant could serves as cancellous bone. Then, the outer layer is covered by cortical bone allograft or alloplast material. Collagen membrane was applied as a barrier membrane and it serves to protect bone regeneration from soft tissue proliferation. Based on the previous study described by Wang *et al.*,⁷ we applied BCP bone graft

material (40% β -TCP - 60% HA) on the outer layer and DFDBA on the inner layer of the defect. Beside the osseointegrative and osseo-conductive characters, the combination of BCP and DFDBA give a better osseogenic character. The treatment goals in this case are the absent of inflammation, pocket depth reduction, no further bone loss, soft and hard peri-implant tissues establishment. Important things stated in American Academy of Periodontology Consensus,¹⁹ that principles of regular implant's evaluation and structure beyond should be maintained. In conclusion, guided bone regeneration (GBR) with sandwich technique could serves as one of the treatment choices for correcting an exposed anterior implant that will enhance the success of aesthetic outcome and maintain long-term implant stability.

REFERENCES

- Mombelli A, Moene R, Decaillet F. Surgical treatments of peri-implantitis. *Eur J Oral Implantol* 2012; 5(Suppl): S61–S70.
- Koldslund OC, Scheie AA. Prevalence of peri-implantitis related to severity of the disease with different degrees of bone loss. *J Periodontol* 2010; 81(2): 231-8.
- Tarnow DP. Increasing prevalence of peri-implantitis: how will we manage?. *J Dent Res* 2016; 95(1): 7-8.
- Cavalli N, Corbella S, Taschieri S, Francetti L. Prevalence of peri-implant mucositis and peri-implantitis in patients treated with a combination of axial and tilted implants supporting a complete fixed denture. *Scientific World Journal* 2015; doi: 10.1155/2015/874842.
- Heitz-Mayfield LJ, Mombelli A. The therapy of peri-implantitis: a systematic review. *Int J Oral Maxillofac Implants* 2014; 29(Suppl): 325-45.
- Schwarz F, Sahm N, Bieling K. Surgical regeneration treatment of peri-implantitis lesions using nanocrystalline hydroxy-apatite or a natural bone mineral in combination with collagen membrane: a four-year clinical follow-up report. *J Clin Periodontol* 2009; 36: 807-14.
- Wang HL, Misch C, Neiva RF. "Sandwich" bone augmentation technique: rationale and report of pilot cases. *Int J Periodontics Restorative Dent* 2004; 24(3): 232-45.
- Fu J, Wang H-L. The sandwich bone augmentation technique. *Clin Adv Periodontics* 2012; 2: 172-7.
- Loe H. The gingival index, the plaque index and the retention index systems. *J Periodontol* 1967; 38(6 suppl): 610-6.
- Lang NP, Berglundh T, Heitz-Mayfield LJ, Pjetursson BE, Salvi GE, Sanz M. Consensus statements and recommended clinical procedures regarding implant survival and complications. *Int J Oral Maxillofac Implants* 2004; 19(Suppl): 150-4.
- Berglundh T, Persson L. A systematic review of the incidence of biological and technical complications in implant dentistry reported in prospective longitudinal studies of at least 5 years. *J Clin Periodontol* 2002; 29(Suppl 3): 197-212.
- Lindhe J, Meyle J. Peri-implant diseases: consensus report of the sixth european workshop on periodontology. *J Clin Periodontol* 2008; 35 (Suppl. 8): 282–5.
- Mir-Mari J, Mir-Orfila P, Figueiredo R, Valmaseda-Castellón E, Gay-Escoda C. Prevalence of peri-implant diseases. A cross-sectional study based on a private practice environment. *J Clin Periodontol* 2012; 39(5): 490-4.
- Marrone A, Lasserre J, Bercy P. Prevalence and risk factors for peri-implant disease in Belgian adults. *Clin Oral Implants Res* 2012; 2: 247-50.
- Popat RP, Bhavsar NV, Popat PR. Peri-implantitis: management of ailing, failing & failed dental implants. *IOSR Journal of Dental and Medical Sciences* 2014; 13(1): 43-6.
- Smeets R, Henningsen A, Jung O, Heiland M, Hammächer C, Stein JM. Definition, etiology, prevention and treatment of peri-implantitis: a review. *Head Face Med* 2014; 10: 34.
- Chiapasco M, Zaniboni M. Augmentation procedures for the rehabilitation of deficient edentulous ridges with oral implants. *Clin Oral Implants Res* 2006; 17(2): 136-59.
- Schwarz F, Bieling K, Latz T, Nuesry E, Becker J. Healing of intrabony peri-implantitis defects following application of nanocrystalline hydroxyapatite (Ostim) or a bovine-derived xenograft (Bio-Oss) in combination with a collagen membrane (Bio-gide). A case series. *J Clin Periodontol* 2006; 33(7): 491-9.
- Cohen RE. Research, science and therapy committee, american academy of periodontology. position paper: periodontal maintenance. *Journal of Periodontology* 2003; 74(9): 1395-401.