

## Case Report

## Orthodontic-surgical treatment of a severe class III malocclusion

Pakpahan Evie Lamtiur

Department of Orthodontic

Faculty of Dentistry, Universitas Prof Dr. Moestopo (B)

Jakarta - Indonesia

**ABSTRACT**

**Background:** Adult patient with dentofacial deformities usually need surgical orthodontic treatment. Although case of class II dentofacial deformities are more common, the need for treatment and improvement in term of facial profile is generally greater in class III patients. When a skeletal Class III malocclusion is diagnosed, orthognathic surgery is always considered if the orthodontist and patient desire complete correction of the skeletal discrepancy. **Purpose:** The purpose of this article were to reported a case of severe class III malocclusion and to showed the positive effect of orthognathic surgical treatment on the patient's profile. **Case:** This case report describes the surgical-orthodontic treatment of a 20 year old male patient with class III dentofacial deformity. **Case managements:** To allow adequate surgical movement, both maxillary first premolars were extracted, and the maxillary incisors were retracted. No extractions were performed in the mandibular arch. Surgery included a Le Fort I osteotomy with 8 mm advancement, a bilateral sagittal split osteotomy with the mandibula was set back 13 mm at right side and 11 mm at left side for the correction of dental midline and chin deviation. The genioplasty treatment also was done. **Conclusion:** Surgical-orthodontic treatment could be chosen as a treatment option for achieving an acceptable occlusion and a good esthetic result in a patient with a Class III dentofacial deformity. Nevertheless, it should be performed by a multidisciplinary team to ensure a satisfactory outcome

**Key words:** Class III dentofacial deformity, orthognathic surgery, orthodontic treatment

**ABSTRAK**

**Latar belakang:** Pasien dewasa dengan deformitas dentofacial biasanya ditangani dengan perawatan bedah orthodonti. Walaupun kasus deformitas dentofacial klas II lebih sering dijumpai, namun kebutuhan perawatan dan keinginan untuk memperbaiki profil muka lebih tinggi pada pasien dengan kasus klas III. Untuk koreksi kelainan skeletal secara menyeluruh pada maloklusi skeletal klas III maka dibutuhkan perawatan bedah ortodonti. **Tujuan:** Laporan kasus ini bertujuan melaporkan penanganan kasus dengan kelainan klas III maloklusion skeletal serta memperlihatkan hasil perawatan bedah ortognati yang memperbaiki profil pasien. **Kasus:** Perawatan bedah ortodonti dilakukan pada pasien laki-laki (20 tahun) dengan kelainan deformitas dentofacial klas III. **Tatalaksana Kasus:** Dilakukan pencabutan premolar pertama rahang atas kanan dan kiri, kemudian dilakukan retraksi gigi insisif rahang atas, agar didapatkan pergerakan yang adekuat. Tidak dilakukan pencabutan gigi pada rahang bawah. Perawatan bedah yang dilakukan adalah Le Fort I osteotomy dengan memajukan rahang atas sebanyak 8mm, mandibula dimundurkan dengan tehnik bilateral sagittal split ostetomy sebanyak 13 mm disebelah kanan, dan 11 mm disebelah kiri untuk koreksi dental midline dan deviasi dagu. Pasien juga mendapatkan perawatan genioplasty. **Simpulan:** Bedah ortognatik dapat dipilih sebagai perawatan untuk mendapatkan oklusi dan hasil estetik yang baik pada pasien dengan deformitas dentofasial kelas III. Namun demikian, perawatan perlu dilakukan oleh tim dari multidisiplin untuk mendapatkan hasil yang memuaskan.

**Kata kunci:** Deformitas dentofasial Klas III, bedah orthognati, perawatan ortodonti

**Correspondence:** Pakpahan Evie Lamtiur, c/o: Departemen Ortodonsia, Fakultas Kedokteran Gigi Universitas Prof Dr. Moestopo (B). Jl. Bintaro Permai Raya no. 3 Jakarta Selatan 12330, Indonesia. E-mail: evie\_lamtiur@yahoo.com

## INTRODUCTION

Many approaches have been performed successfully by orthodontist for the treatment of malocclusion and Class III malocclusion is considered as one of the most complex and difficult orthodontic problem to be diagnosed and treated.<sup>1</sup> In reality dental camouflage only leads to an effective improvement of aesthetics in a few situations. More frequently it has no significant influence on facial aesthetics, as in purely orthodontic correction of class III cases. In an adult with dentoskeletal discrepancy, surgery is the only sure treatment option if the dental defect cannot be corrected by orthodontics alone or if dental camouflage would involve technical or periodontal contraindications, or would not produce a marked aesthetic improvement. When a skeletal class III malocclusion is diagnosed, orthognatic surgery is almost always a consideration if the orthodontist and the patient desire complete correction of the skeletal discrepancy. Individuals with class III malocclusion frequently show combinations of skeletal and dentoalveolar components. Several distinct cephalometric features have been reported in class III patients, such as a short anterior cranial base length, acute cranial base angle, a short and retrusive maxilla, proclined maxillary incisors, retroclined mandibular incisors, an excessive lower anterior face height and obtuse gonial angle.<sup>2</sup> Therefore class III patients are large proportion of those seeking surgical orthodontic treatment. However, the etiology all class III malocclusion might not be the same. The

etiology of class III malocclusions may involve hereditary factors, environmental influences and even pathology.<sup>3</sup> Additionally, class III patients typically have longer and unpredictable facial growth.<sup>2</sup> Class III patients can have varying degrees of dental and skeletal abnormalities. An accurate diagnosis is important to treat the malocclusion in order to insure that the treatment plan is directed at correcting the various abnormalities.<sup>3</sup>

The purpose of this article were to reported a case of severe class III malocclusion and to showed the positive effect of orthognatic surgical treatment on the patients profile.

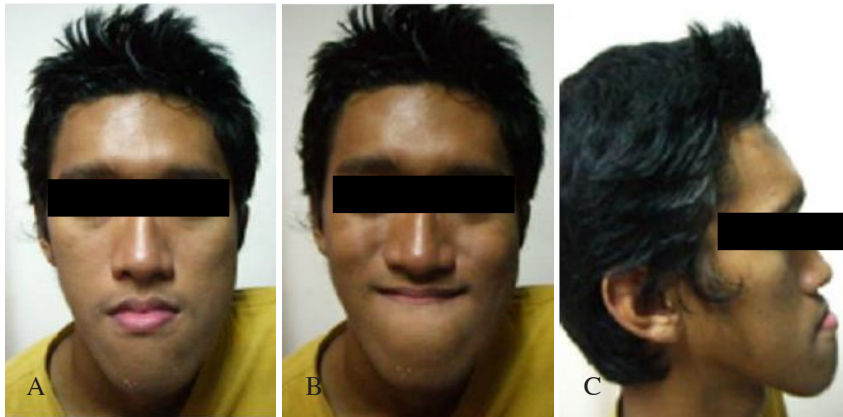
## CASE

A male patient, 20 years old, initially came for orthodontic treatment with the complaint of long face, crossbite and inability to incise. He has family history of class III malocclusion. The patient has a nonrelevant medical history. After thorough clinical examination and cephalometric analysis, surgical-orthodontic treatment was recommended.

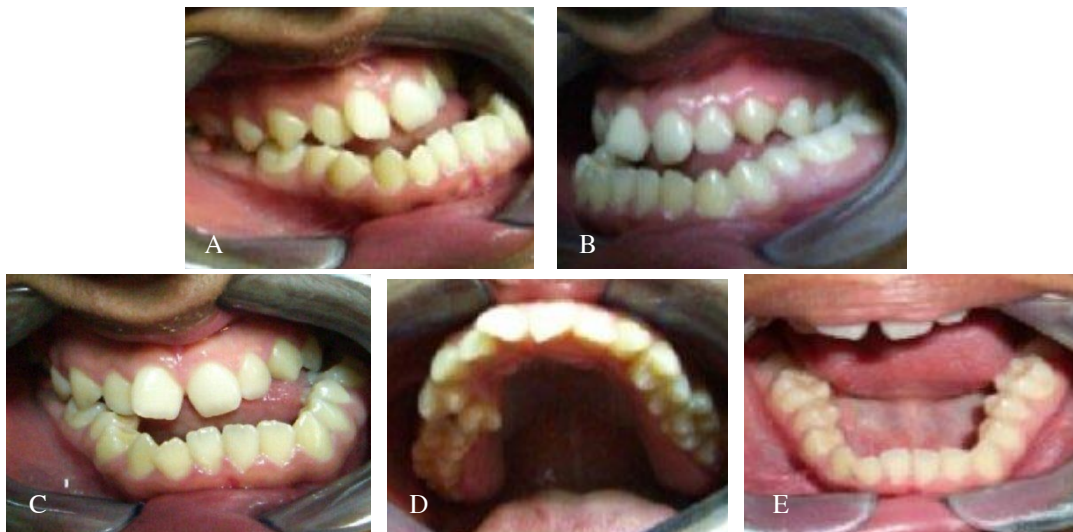Extraoral examination showed a concave profile with extremely long lower face height, incompetent lip and a flattened lower lip without labiomental sulcus. Frontal view of the face showed chin deviation to the left and long middle third of the face. The lower lip was stretched to compensate for the vertical discrepancy (Figure 1).

**Table 1.** Cephalometric summary

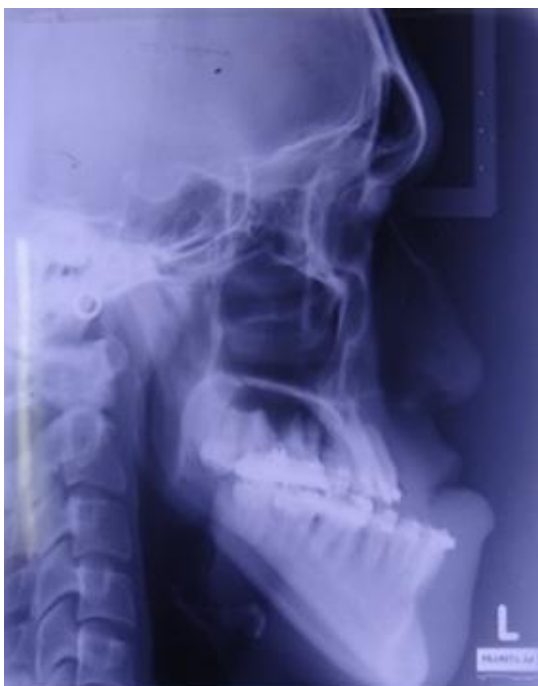Measurement	Initial	Presurgical	Postsurgical
NA	85°	84°	92°
SNB	96°	96°	90°
ANB	-11°	-12°	+2°
Wits	-20mm	-29mm	-10mm
NAPg	-20°	-22°	-2°
FMA	40°	40°	35°
N PERP A	-3°	-5°	+4°
N PERP B	+12°	+13°	+6°
N-ANS	60 mm	59mm	65mm
ANS-Me	87mm	86mm	75mm
Faxial axis	66°	65°	62°
Sn Go Gn	39°	38°	35°
I SN	114°	107°	110°
IPP	125°	120°	109°
MX I TO NA	10mm	12mm	8mm
	25°	24°	35°
Mn I to nb	6mm	10mm	7mm
	14°	32°	15°
I mpa	65°	77°	75°
E line bibir atas	-5mm	-6mm	-3mm
E line bibir bawah	+5mm	+5mm	+3mm



**Figure 1.** Pretreatment facial profiles: A, B. front; C. Right side.



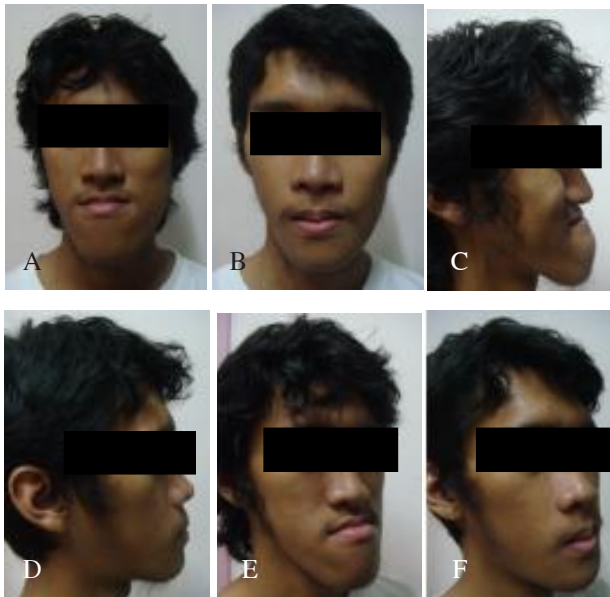**Figure 2.** Pretreatment intraoral photographs. A) right side; B) left side; C) front; D) maxilla; E) mandibula.



**Figure 3.** Presurgical cephalometric radiograph.

The analysis of intraoral confirmed an angle class III malocclusion with antero posterior discrepancy in the molar relationship was more than 10 cm, and a -13 cm incisor overjet, absence of overbite were measured. The mandibular dental midline were deviated 6mm to the left. There was posterior crossbite on the left side, mild crowding in the lower as well and compensation of incisor inclination in both arches (Figure 2).

Study model analysis showed an angle class III malocclusion more than 10 mm anteroposterior discrepancy in the molar relationship. The archform were not well coordinated due to severe compensations that led to large anterior and buccal overjet. The lateral cephalometric radiograph revealed Class III skeletal malocclusion ( $ANB = -11^\circ$ ), maxillary a bit protusion ( $SNA = 85^\circ$ ), and mandible protusion ( $SNB = 96^\circ$ ) in relation to the anterior skull base. Concave bone profile ( $NAPg = -20^\circ$ ), dolichofacial morphological type (facial axis =  $66^\circ$ ) and predominance of vertical growth of the face ( $SNGoGn = 39^\circ$  and  $FMA = 40^\circ$ ). The maxillary incisors presented increased to their alveolar (Table 1 and Figure 3) .



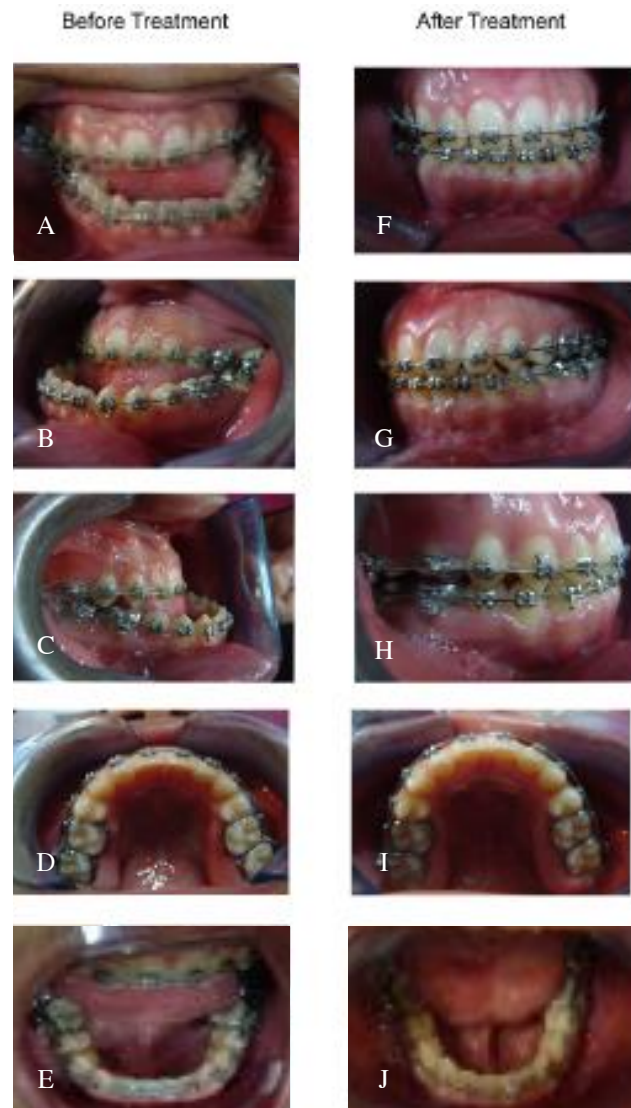
**Figure 4.** A, C, E) Presurgical ekstraoral photographs. B, D, F) post surgical ekstraoral photographs-1.

#### CASE MANagements

preoperative orthodontic preparation was performed with 0.022 appliance. Leveling and alignment began with 0.016-in nickel-titanium archwires, followed by 0.018, 0.016 x 0.022-inch nickel-titanium archwires up to 0.19 x 0.025-inch stainless steel rectangular archwires. In the leveling and alignment stage, the archwires were coordinated. To allow adequate surgical movement, the maxillary first premolars on both side was extracted to correct the position of maxillary incisor therefore the maxillary incisors were retracted. No extractions were performed in the mandibular arch because there was minimal crowding. The mandibular incisors were aligned and the arch and the archform were coordinated.

After presurgical orthodontic treatment achieved, the orthognathic surgery were performed. Surgery included a Le Fort I osteotomy with 8mm of advancement and it was rotated anterior down 3 mm and posterior up 1 mm at Posterior Nasal Spine (clockwise rotation). The pivoting point is around the first molar. A bilateral sagittal split osteotomy with 13 mm of setback at right and 11 mm at left for the correction of dental midline and chin deviation. The chin therefore moves 11 mm backward. Rigid internal fixation with screws and plates was used to stabilize the osteotomy site. The patient was followed up closely after the procedures. Postoperatively, to achieve the proper occlusal contacts, vertical intermaxillary and class III elastic were used.

After surgery, it was observed functional occlusion, normal overjet and overbite, and adequate intercuspation, with class II Angle molar relationship and class I canine relationship, coincident midlines. Mandibular prognathism and asymmetry were eliminated and facial esthetic was



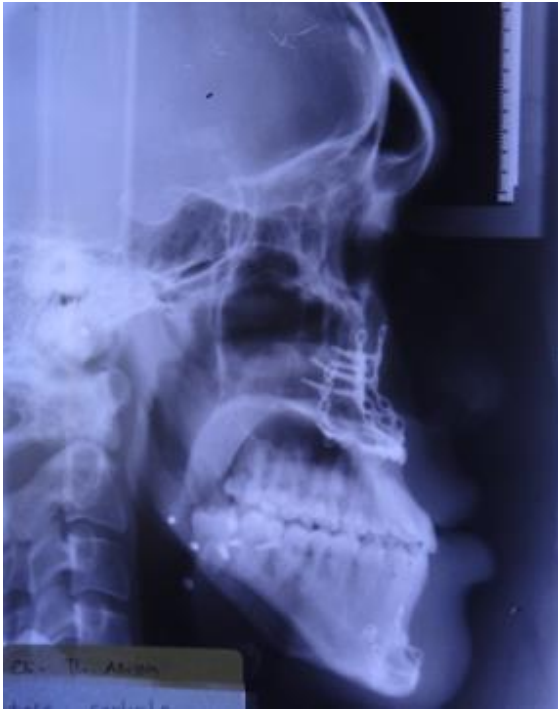**Figure 5.** A, B, C, D, E) Presurgical intraoral photographs. F, G, H, I, J) post surgical intraoral photographs copy.

considerably improved. Figures 4 and 5 show the results obtained with the orthognathic surgery and orthodontic finishing stage, and postsurgical cephalometric radiograph is shown in Figure 6.

#### DISCUSSION

There are three main treatment options for skeletal class III malocclusion, which is growth modification, orthodontic therapy, and orthognathic surgery combined with orthodontic treatment. Maxillofacial growth modification with dentofacial orthopedic appliance is an effective method for resolving skeletal class III jaw discrepancies in children. Correcting this problem in adults requires orthognathic surgery in conjunction with orthodontic treatment.<sup>4</sup>

Some studies reported the factors that the choice between conventional orthodontic treatment and surgical orthodontic



**Figure 6.** Post surgical cephalometric radiograph copy.

treatment. Kerr<sup>5</sup> et al reported that patients with ANB angles of less than  $-4^\circ$  and mandibular incisor inclination of less than  $83^\circ$  were more likely to have surgical-orthodontic treatment than conventional orthodontic treatment. A recent study concluded that surgical patients could be distinguished from nonsurgical ones, on the basis of WITS measurement, maxillary/mandibular length ratio, gonial angle, and sella-nasion distance.<sup>6</sup> Miller<sup>5</sup> found there were four areas of significant difference between the surgery and non surgery case, which are: ANB Angle was significantly more negative in the surgical group.<sup>5</sup> Surgery was often considered necessary when ANB angle was less than  $-4^\circ$ . Thus the ratio of maxillary to mandibular lengths was significantly smaller for the surgical patients. Also, the lower incisor were more retroclined in the surgical group. The division between the two group was about  $83^\circ$ . The last role is the Holdaway angle was larger in the orthodontic group. Surgery was almost always carried out when the Holdaway angle was less than  $3.5^\circ$ .<sup>5</sup> Before treatment this patient had ANB =  $-11^\circ$ , and mandibular incisor inclination of less than  $83^\circ$  which is  $65^\circ$  (Table 1 and Figure 3). That measurement indicate for this patient to have orthognatic surgery treatment.

It is very important to understand the components of facial asymmetry in order to outline an accurate and effective treatment plan.<sup>7-10</sup> The analysis of posteroanterior cephalometric radiographs determines if the asymmetry is related to the maxilla, mandible or both, in the sagittal or transverse direction, and is the anomaly is also associated with dental compensations. Most studies have demonstrated that transverse dental compensation

is correlated with skeletal asymmetry.<sup>11-13</sup> Inclination of the occlusal plane greater than 4 and mentum deviations observed in the posteroanterior cephalogram are important characteristic to determine the presence and extension of facial asymmetry.<sup>14-15</sup> The patient of this case presented significant facial asymmetry with mandibular asymmetry and mentum deviation to the left. Severt and Proffit also Haraguchi *et al.*<sup>15</sup> have reported that in patients with dentofacial deformities with mandibular deviation, lateral excursion to the left was present in over 85% of the studied population. He also added that the mandible is more asymmetrical than the maxilla because of its greater to potential. While the mandible is a movable bone, the maxilla is rigidly connected to the adjacent skeletal structures by means of sutures and synchondroses.

The patient presented unilateral posterior crossbite on the left side and midline sifting to the left, it results from mandibular deviation. The mandibular deviation and midline shifting was corrected by surgically. The same treatment was taken with similar cases in some case report.<sup>17,18</sup> Orthodontic treatment to obtain the preoperative alignment of the dental arches was also an important part as the best result with minimum relapse could not be expected without a stable occlusion.<sup>19-20</sup> The maxillary premolars on both side were extracted to correct maxillary incisors inclination. The main aim of the presurgical orthodontic phase is to correct the incisor inclinations to normal to allow maximum surgical correction and the less-than-ideal outcomes for the skeletal relationships might have been due to inadequate presurgical orthodontic decomensation of the incisor inclination.<sup>20</sup>

After surgery the position of maxilla in this patient was +5mm anterior to the nasion Frankfort line and the maxillary incisor was +8mm anterior to the nasion Frankfort. Position maxillary incisor was  $109^\circ$ . When only orthodontic treatment considered, the orthodontist formulates a treatment plan based on the desired final position of the mandibulat incisor. For surgical treatment planning the scenario is reversed; the maxillary incisor final position is used to determine the placement of the facial bones. McNamara's nasion Frankfort perpendicular is an anteroposterior guideline that can be used to help determine the best placement of the maxillary incisor.<sup>21</sup> Point A should be positioned as close as possible to the nasion Frankfort line, but more importantly, the maxillary incisor should be positioned 5 mm  $\pm$  2 mm anterior to the nasion Frankfort line and at  $110^\circ$  to the palatal plane.<sup>22-23</sup>

The overall result of the treatment was good (Figure 4, 5 and 6). The lower face height (ANS-Me) was improved cephalometrically from 87 mm to 75 mm. The ANB was improved from  $-11^\circ$  to  $+2^\circ$ . Visually, pleasing changes in the frontal and profile views of the face are evident (Figure 4). The pretreatment lip incompetency was totally eliminated and the labiomental sulcus was normalized.

Dental changes resulted in a class II molar occlusion with a class I canine relationship. The pretreatment maxillary midline deviation to the left was completely

corrected. All the functional movement of the mandible are without limitation and without symptoms. The treatment protocol produced a satisfactory occlusal and esthetic result for the patient and his parents as demonstrated by their attitude.

This case report describes the treatment of an adult patient with severe class III dentofacial deformity. Orthognatic surgery treatment was the best option for achieving an acceptable occlusion and a good esthetic result in this patient. An experienced multidisciplinary team approach ensures a satisfactory outcome. Presurgical orthodontics removes all the dental compensations and suggests the location and extent of the skeletal discrepancy. Normal skeletal base relationship was achieved by osteotomy and setback of the prognathic mandible, postsurgical orthodontics guides the normal occlusal rehabilitation by correcting any emerging dental discrepancies.

---

#### ACKNOWLEDGEMENTS

Sincere gratitude to dr. Enrina Diah, Sp.BP for performing the orthognatic surgery in Cipto Mangunkusomo Hospital, Jakarta.

#### REFERENCES

- Mucedero M, Coviello A, Baccetti T, Franchi L, Cozza P. Stability factors after double-jaw surgery in class III malocclusion. *Angle Orthodontist* 2008; 78(6): 1141-52.
- Katiyar R, Singh GK, Mehrotra D, Singh A. Surgical-orthodontic treatment of a skeletal class III malocclusion. *Natl J Maxillofac Surg* 2010; 1(2): 143-9.
- Lowenhaupt EB. Compromised nonsurgical treatment of a patient with a severe class III malocclusion. *International Dentistry* 2009; 11: 52-61.
- seng YC, Pan CY, Chou ST, Liao CY, Lai ST, Chen CM, Chang HP, Yang YH. Treatment of adult class III malocclusion with orthodontic therapy or orthognatic surgery: Receiver operating characteristic analysis. *Am J Orthod Dentofacial Orthop* 2011; 139(5): e485-e493.
- Kerr WJ, Miller S, Dawber JE. Class II malocclusion: surgery or orthodontics?. *Br J Orthod* 1992; 19: 21-4.
- Stellzig-Eisenhauer A, Lux CJ, Schuster G. Treatment decision in adult patients with class III malocclusion: orthodontic therapy or orthognatic surgery?. *Am J Orthod Dentofacial Orthop* 2002; 122: 27-37.
- Decker, JD. Asymmetric mandibular prognatism: A 30-year retrospective case report. *Am J Orthod Dentofacial Orthop* 2006; 129(3): 436-43.
- Hayashi K, Mugutuma T. Morphologic characteristic of the dentition and palate in cases of skeletal asymmetry. *Angle Orthod* 2004; 74(1): 26-30.
- Ko EW, Huang CS, Chen YR. Characteristic and corrective outcome of face asymmetry by orthognatic surgery. *J Oral Maxillofac Surg* 2009; 67(10): 2201-9.
- Sekiya T, Nakamura Y, Oikawa T, Ishii H, Hirashita A, Seto K. Elimination of transverse dental compensation is critical for treatment of patients with severe facial asymmetry. *Am J Orthod Dentofacial Orthop* 2010; 137(4): 552-62.
- Hayashi K, Muguruma T. Morphologic characteristics of the dentition and palate in cases of skeletal asymmetry. *Angle Orthod* 2004; 74(1): 26-30.
- Kusayama M, Motohashi N, Kuroda T. Relationship between transverse dental anomalies and skeletal asymmetry. *Am J Ortho Am J Orthod Dentofacial Orthop* 2003; 123(3): 329-37.
- Van Elslande DC, Russett SJ, Major PW, Flores-Mird C. Mandibular asymmetry diagnosis with panoramic imaging. *Am J Orthod Dentofacial Orthop* 2008; 134(2): 183-92.
- Padwa BL, Kaiser MO, Kaban LB. Occlusal cant in the frontal plane as a reflection of facial asymmetry. *J Oral Maxillofac Surg* 1997; 55(8): 811-6.
- Haraguchi S, Takada K, Yasuda Y. Facial asymmetry in subjects with skeletal class III deformity. *Angle Orthod* 2002; 72(91): 28-35.
- Severt TR, Proffit WR. The prevalence of facial asymmetry in the dentofacial deformities population at the University of North Carolina. *Int J Adult Orthodon Orthognath Surg* 1997; 12(3): 171-6.
- Janson M, Janson G, Sant Ana E, Tibolao, Martins DR. Orthognatic treatment for a patient with class III malocclusion and surgically restricted mandible. *Am J Orthod J Dentofacial* 2009; 136(2): 290-8.
- Cho HJ. Patient with severe skeletal class II malocclusion and severe open bite treated by orthodontic and orthognathic surgery-a case report. *Am J Orthod Dentofac Orthop* 1996; 110(2): 155-62.
- Nakajima T, Kajikawa Y, Hirose T, Tokiwa N, Hanada K, Fukuhara T. Surgical-orthodontic approach to skeletal class III malocclusion. *Int J Oral Surg* 1978; 7(4): 274-80.
- Johnston C, Burden D, Kennedy D. Class III surgical-orthodontic treatment: A cephalometric study. *Am J Orthod Dentofacial Orthop* 2006; 130: 300-9.
- Mc Namara JA. A method of cephalometric evaluation. *Am J Orthod* 1984; 86(6): 449-69.
- Bilodeau JE. Vertical consideration in diagnosis and treatment, a surgical orthodontic case report. *Am J Orthod Dentofac Orthop* 1995; 107(1): 91-100.
- Bilodeau JE. Correction off a severe class II malocclusion that required two stage orthognatic procedure: A case report. *Am J Orthod Dentofac Orthop* 1995; 108(4): 421-7.