

## Research Report

# Pulp nerve fibers distribution of human carious teeth: An immunohistochemical study

Tetiana Haniastuti

Department of Oral Biology

Faculty of Dentistry, Universitas Gadjah Mada

Yogyakarta - Indonesia

### ABSTRACT

**Background:** Human dental pulp is richly innervated by trigeminal afferent axons that subservise nociceptive function. Accordingly, they respond to stimuli that induce injury to the pulp tissue. An injury to the nerve terminals and other tissue components in the pulp stimulate metabolic activation of the neurons in the trigeminal ganglion which result in morphological changes in the peripheral nerve terminals. **Purpose:** The aim of the study was to observe caries-related changes in the distribution of human pulpal nerve. **Methods:** Under informed consents, 15 third molars with caries at various stages of decay and 5 intact third molars were extracted because of orthodontic or therapeutic reasons. All samples were observed by micro-computed tomography to confirm the lesion condition 3-dimensionally, before decalcifying with 10% EDTA solution (pH 7.4). The specimens were then processed for immunohistochemistry using anti-protein gene products (PGP) 9.5, a specific marker for the nerve fiber. **Results:** In normal intact teeth, PGP 9.5 immunoreactive nerve fibers were seen concentrated beneath the odontoblast cell layer. Nerve fibers exhibited an increased density along the pulp-dentin border corresponding to the carious lesions. **Conclusion:** Neural density increases throughout the pulp chamber with the progression of caries. The activity and pathogenicity of the lesion as well as caries depth, might influence the degree of neural sprouting.

**Key words:** Caries, dental pulp, nerve fibers, protein gene product 9.5

### ABSTRAK

**Latar belakang:** Pulpa gigi manusia diinervasi oleh serabut saraf trigeminal yang berespon terhadap stimuli penyebab perlukaan dengan menimbulkan rasa sakit. Perlukaan pada akhiran saraf dan komponen lain dari pulpa akan menstimulasi aktivasi metabolik dari neuron pada ganglion trigeminal sehingga mengakibatkan perubahan morfologi pada akhiran saraf perifer. **Tujuan:** Penelitian ini bertujuan untuk mengamati perubahan distribusi saraf pada pulpa gigi manusia yang disebabkan oleh proses karies. **Metode:** Penelitian ini menggunakan 15 buah gigi molar tiga yang mengalami karies dengan berbagai tingkat kedalaman karies dan 5 buah gigi molar tiga normal (tidak mengalami karies). Gigi-geligi tersebut dicabut untuk keperluan perawatan ortodontik atau alasan perawatan lainnya. Sebelum didekalsifikasi dengan menggunakan EDTA 10% (pH 7,4), seluruh sampel diamati dengan micro-computed tomography untuk mengetahui kondisi lesi secara tiga dimensi. Spesimen kemudian diproses secara immunohistokimia menggunakan anti-protein gene products (PGP) 9,5 yang merupakan penanda spesifik untuk serabut saraf. **Hasil:** Pada pulpa gigi normal, serabut saraf yang menunjukkan ekspresi PGP 9,5 positif tampak terkonsentrasi di bawah lapisan odontoblast. Distribusi serabut saraf tampak meningkat pada perbatasan dentin-pulpa di bawah lesi karies. **Kesimpulan:** Densitas serabut saraf pada kamar pulpa meningkat dengan bertambahnya kedalaman karies. Aktivitas dan patogenisitas dari lesi serta kedalaman karies dapat berpengaruh terhadap penyebaran serabut saraf.

**Kata kunci:** Karies, pulpa gigi, serabut saraf, protein gene product 9,5

**Correspondence:** Tetiana Haniastuti, c/o: Bagian Biologi Oral, Fakultas Kedokteran Gigi Universitas Gadjah Mada. Jl. Denta I Yogyakarta 55281, Indonesia. E-mail: haniastuti@yahoo.com

## INTRODUCTION

Caries is an infectious and transmittable disease resulting from certain bacteria present within the oral cavity such as *Streptococcus mutans*, *Streptococcus sobrinus*, and *Lactobacilli*.<sup>1,2</sup> Those bacteria produce acids following an individual's sugar consumption which have ability to diffuse through the dental calcified tissues and drop the local pH to below 5.0, which in turn leads to dissolution of the mineral crystals.<sup>3,4</sup>

A variety of stimuli, including caries, have been demonstrated to have an effect on the pulp. Carious lesion contains bacterial and antigenic substances which may affect the pulp through the dentin. Caries can exert its effects on the dental pulp even before the infection breaches the dentin enamel junction. Thereafter, the progression of infection exerts an increasing effect on the underlying pulp by eliciting defense and repair mechanisms mainly aimed at decreasing dentin permeability and eradicating pathogens.<sup>5,6</sup>

Human dental pulp is richly innervated by trigeminal afferent axons that subserve nociceptive function. Accordingly, they respond to stimuli that induce injury to the pulp tissue.<sup>7</sup> An injury to the nerve terminals and other tissue components in the pulp stimulate metabolic activation of the neurons in the trigeminal ganglion which result in morphological changes in the peripheral nerve terminals. The results of previous studies have demonstrated a sprouting of pulpal nerve fibers following dental injury.<sup>8-10</sup>

Protein gene product (PGP) 9.5 is a novel neuron-specific protein, widely distributed in both central and peripheral neurons. Previous research on dental innervation clearly revealed that PGP 9.5 is a useful marker for identifying delicate nerve fibres such as A-delta and C-fibres. In addition, PGP 9.5 antigenicity is well preserved during demineralization process.<sup>11</sup>

Although structural neural changes have been investigated following experimental pulp injury,<sup>8-10</sup> there has been little attempt to study caries-induced neural changes in human. The purpose of the study was to observe caries-related changes in the distribution of human pulpal nerve using PGP 9.5.

## MATERIALS AND METHODS

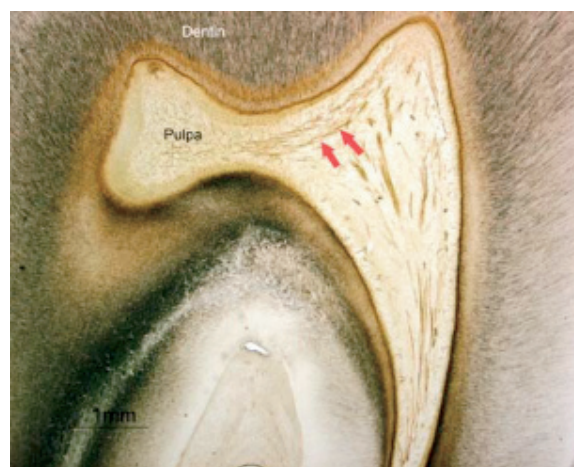
Twenty volunteers ranging in age from 20–40 years, who had been scheduled to undergo extraction for orthodontic or therapeutic reasons were enrolled in the study. Informed consents were obtained from subjects after the proposed study was fully explained. Fifteen third molars with caries at the occlusal site at various stages of decay and 5 intact third molars were extracted. The depth of the cavity judged by clinical examination was recorded. Before decalcifying with 10% ethylene-diaminetetraacetic acid (EDTA) solution (pH 7.4) for 6 months at 4°C, all the samples were observed

by micro-computed tomography (micro-CT) to confirm the lesion condition 3-dimensionally. The specimens were then processed for cryosection. The tissues were equilibrated in a 30% sucrose solution for cryoprotection. The specimens were cut at thickness of 50 µm on a freezing microtome, collected into cold phosphate-buffered saline, and treated as free-floating sections.

Frozen sections were processed for the avidin-biotin peroxidase complex (ABC) method by using rabbit anti-human PGP 9.5 polyclonal antibody (Chemikon International, Temecula, USA). Endogenous peroxidase was inhibited by treatment with 0.3% H<sub>2</sub>O<sub>2</sub> in absolute methanol for 30 minutes. Any non-specific immunoreaction was inhibited by preincubation in 2.5% normal goat serum (Vector Laboratories Inc, CA, USA). Following incubation with the primary antibodies, the sections were then reacted consecutively with biotinylated anti-rabbit IgG and ABC (Vector Laboratories Inc, CA, USA). The sites of antigen-antibody reactions were visualized using 3–3'-diaminobenzidine tetrachloride in Tris buffer and 0.002% H<sub>2</sub>O<sub>2</sub> and counterstained with 0.05% methylene blue. The immunostained sections were thaw-mounted onto silane-coated glass slides and stained with 0.03% methylene blue. Immunohistochemical controls omitting the primary antibody, the biotinylated anti-rabbit IgG, or the ABC complex resulted in no staining.

## RESULTS

Micro-CT observation showed intact teeth; no lesion was observed. The nerve density is greatest near the tip of the pulp horn. Arrangement of positive fibers below the odontoblastic layer (Rasckow's plexus) was observed (Figure 1). The nerves directed radially toward



**Figure 1.** A specimen of intact tooth. Rasckow's plexus (arrows) was observed below the odontoblastic layer. The nerves directed radially toward the odontoblasts. Most of PGP 9.5-positive nerve fibres penetrate into the predentine and dentine beyond the pulpodentinal border.

the odontoblasts. The pulpal nerves, thin and frequently beaded in appearance, entered the odontoblast cell layer. Some of PGP 9.5-positive nerve fibres terminated in the odontoblast layer, but the majority penetrated into the predentine and dentine beyond the pulpodentinal border. PGP 9.5-positive immunoreaction was also recognized in odontoblast cells.

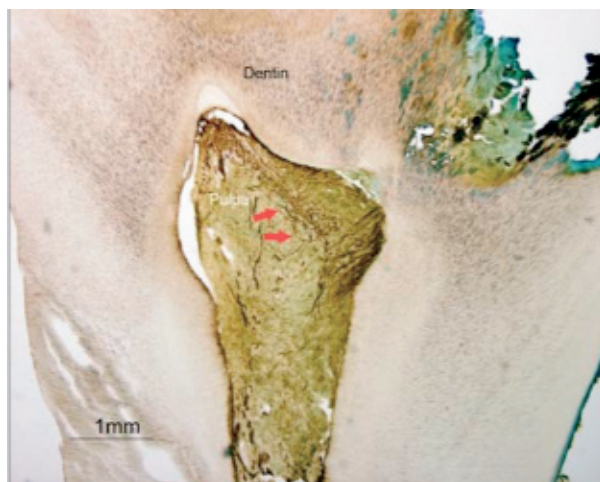Although micro-CT observation showed radiolucent area involving enamel, no dentinal injury was observed in histological specimens. PGP 9.5-positive nerve fibers demonstrated similar distribution to the intact teeth.

Radiolucent area involving dentin was showed. PGP 9.5 immunoreactivity exhibited an increase in density in the para odontoblastic region correspond to the area of inflammatory cells infiltration. There were sprouting nerve fibers under the lesions. Reparative dentin was found beneath the lesion. PGP 9.5-positive nerve fibres were fewer subjacent the reparative dentin and terminated in the odontoblast layer; while in other areas PGP 9.5-positive nerve fibers penetrated into the predentine and dentine beyond the pulpodentinal border. The rest of the pulp demonstrated a normal appearance.

Micro-CT observation showed lesion involving pulp. Numerous PGP 9.5-positive nerve fibers were concentrated heavily in areas where pulp was inflamed (Figure 2). In this region, nerve fibers displayed both extensive arborization and thickening of small nerve bundles to form bands of neural tissue. It appeared that increased neural density in the pulp horn was due to sprouting of nerve terminals rather than to increasing in the number of parent axons entering the tooth, since there were no apparent changes within the main nerve trunks passing up through the coronal pulp.

## DISCUSSION

The present study has demonstrated the distribution of nerve fibers within the pulp with caries progression. Neural



**Figure 2.** A specimen with pulp lesion. Numerous PGP 9.5-positive nerve fibers were concentrated heavily in areas subjacent to the lesions (arrows).

density appeared to increase markedly throughout the pulp chamber with the progression of caries. It is likely that, in addition to caries depth, the activity and pathogenicity of the lesion may also influence the degree of neural sprouting. These findings concur with the previous studies of pulpal inflammation.<sup>8,9</sup>

This study used micro-CT to observe the depth and condition of the carious lesion three-dimensionally. Micro-CT is an emerging technology that has been used as a research tool in various applications including morphometry of bone, connective tissue, teeth or root canals. The micro-CT technique is rapid and noninvasive. In addition, the results are reproducible and comparable with histology.<sup>12</sup>

PGP 9.5 is a novel neurone-specific protein. This protein is a useful marker for identifying delicate nerve fibers such as A-delta and C-fibers.<sup>11</sup> A study by Yoshida *et al.*<sup>13</sup> demonstrated that PGP 9.5 is a reliable marker for the demonstration of fine nerve terminals in human tooth pulp.

Caries-induced changes in neural distribution might be functionally important in the regulation of pulpal inflammation and healing. In this study, the nerve sprouting was most remarkable at the site where inflammatory cells were densely accumulated. These findings suggest a functional communication between neuropeptides and pulpal immunocompetent cells such as neutrophils, macrophages and T-lymphocytes. Nerve fibers have demonstrated an extensive sprouting reaction in response to dentinal injury which probably results in metabolic activation of the neurons in the trigeminal ganglion to provide an increased local source of neuropeptides to the inflammatory region.<sup>14,15</sup>

Previous studies revealed that the neuropeptides induce vasodilation and an increase in the permeability of the vessel walls; therefore, they regulate inflammatory cells invasion to the injury sites. Such vascular reactions are an essential part of the inflammatory reaction and are also necessary to satisfy the nutritional needs related to the increased metabolic activity in connection with tissue repair and healing.<sup>16,17</sup>

Pulp has ability to produce reparative dentin beneath a carious lesion as a mechanism for limiting the diffusion of toxic substances to the pulp.<sup>18</sup> This study showed that the areas beneath the reparative dentin showed fewer number of PGP 9.5 immunoreactivity than normal. These findings indicating that sprouting of the nerve and neuropeptides up-regulation continue as long as there is active inflammation that has not been walled off by scar formation. Once an effective scar and reparative dentin were formed, the nerve sprouting decreases and neuropeptide levels return to normal range or are subnormal.<sup>15</sup>

In this study, the post mitotic mature odontoblasts also exhibited intense PGP 9.5 immunoreactivity as secretion of predentinal matrix was visible. PGP 9.5 immunohistochemical studies have shown that this protein is widely distributed in neuroendocrine cells in addition to

central and peripheral neurons. A possible explanation of the immunoreactivity for PGP 9.5 in the human odontoblast may be due to their derivation from the neural crest, in common with neurons and neuroendocrine cells.<sup>19</sup>

In conclusion, neural density increases throughout the pulp chamber with the progression of caries. It is likely that the activity and pathogenicity of the lesion as well as the depth of the caries, might influence the degree of neural sprouting.

## REFERENCES

1. Love RM. Invasion of dentinal tubules by root canal bacteria. *Endod Top* 2004; 9: 52–65.
2. Marsh PD, Nyvad B. The oral microflora and biofilms on teeth. In: Fejerskov O, Kidd E, editors. *Dental caries: the disease and its clinical management*. Oxford: Blackwell Munksgaard; 2008. p. 163–84.
3. Featherstone JDB. The continuum of dental caries—evidence for a dynamic disease process. *J Dent Res* 2004; 83: C39–C42.
4. Shen S, Samaranayake LP, Yip H. In vitro growth, acidogenicity and cariogenicity of predominant human root caries flora. *J Dent* 2004; 32: 667–78.
5. Bjørndal L. The caries process and its effect on the pulp: the science is changing and so is our understanding. *J Endod* 2008; 34: S2–S5.
6. Goldberg M, Farges J, Lacerda-Pinheiro S, Six N, Jegat N, Decup F, Septier D, Carrouel F, Durand S, Chaussain-Miller C, DenBesten P, Veis A, Poliard A. Inflammatory and immunological aspects of dental pulp repair. *Pharmacol Res* 2008; 58: 137–47.
7. Byers MR, Narhi MVO. Nerve supply of the pulpodentin complex and responses to injury. In: Hargreaves KM, Goodis HE, editors. *Seltzer and Bender's dental pulp*. Chichago: Quintessence Publishing Co; 2002. p. 154–5.
8. Haug SR, Heyeraas KJ. Modulation of dental inflammation by the sympathetic nervous system. *J Dent Res* 2006; 85(6): 488–95.
9. Rodd HD, Boissonade FM. Comparative immunohistochemical analysis of the peptidergic innervation of human primary and permanent tooth pulp. *Arch Oral Biol* 2002; 47: 375–85.
10. Yu C, Abbott PV. An overview of the dental pulp: its functions and responses to injury. *Aust Dent J* 2007; 52 (1 Suppl): S4–S16.
11. Rood H, Boissonade FM. Immunocytochemical investigation of neurovascular relationships in human tooth pulp. *J Anat* 2003; 202: 195–203.
12. Jung M, Lommel D, Klimek J. The imaging of root canal obturation using micro-CT. *Int Endod J* 2005; 38: 617–26.
13. Yoshida K, Yoshida N, Iwaku M. Class II antigen-presenting dendritic cell and nerve fiber responses to cavities, caries, or caries treatment in human teeth. *J Dent Res* 2003; 82(6): 422–7.
14. Byers MR, Suzuki H, Maeda T. Dental neuroplasticity, neuro-pulpal interactions, and nerve regeneration. *Microsc Res and Tech* 2003; 60: 503–15.
15. Olgart L, Bergenholtz G. The dentine-pulp complex: responses to adverse influences. Bergenholtz G, Hørsted-Bindslev P, Reit C, editors. *Textbook of endodontology*. Oxford: Blackwell Munksgaard; 2003. p. 36.
16. Caviedes-Bucheli J, Camargo-Beltran C, Gomez-la-Rotta A, Moreno SC, Abello GCM, Gonzalez-Escobar JM. Expression of calcitonin gene-related peptide in irreversible acute pulpitis. *J Endod* 2004; 30(4): 201–4.
17. Caviedes-Bucheli J, Arenas N, Guiza O, Moncada NA, Moreno GC, Diaz E, Munoz HR. Calcitonin gene-related peptide receptor expression in healthy and inflamed human pulp tissue. *Int Endod J* 2005; 38: 712–7.
18. Kim S, Trowbridge H, Suda H. Pulpal reaction to caries and dental procedures. In Cohen S, Burns RC, editors. *Pathways of the pulp*. 8<sup>th</sup> ed. St. Louis: Mosby; 2002. p. 574.
19. Arana-Chavez VE, Massa LF. Odontoblasts: the cells forming and maintaining dentine. *Int J Biochem Cell Biol* 2004; 36: 1367–73.