

Case Report

Erythema multiforme as the result of taking carbamazepine

Maharani Laillyza Apriasari¹ and M. Jusri²¹ Faculty of Dentistry, Lambung Mangkurat² Department of Oral Medicine, Faculty of Dentistry, University of Airlangga
Surabaya - Indonesia**ABSTRACT**

Background: Erythema multiforme is an acute mucocutaneous disease which is caused by the hypersensitivity reaction. It is characterized by target lesions on the skin or ulcerative oral lesion. Etiology of the disease is unknown, it is currently considered as immunologic disease. The triggering factors is the use of certain type of drugs like antibiotics, anticonvulsant, and NSAID. Most of the dentists do not know about it is mechanism, so a lot of people consider it as a malpractice. **Purpose:** This paper reported a case of a man, 46 years old which had ulcerative oral mucous, peeled and pain lips after taking carbamazepine drugs. **Case:** The clinical diagnosis of this case was erythema multiforme because of the hypersensitivity reaction as the result of taking carbamazepine. **Case management:** The final diagnosis based on anamnesis history of taking systemic drugs and clinical manifestation of erythema multiforme in the oral cavity. The drugs therapy that had been given were antihistamine, oral corticosteroid, gargle liquid contained of topical anesthetic, corticosteroid, and antibiotic. **Conclusion:** In this case, it can be concluded that erythema multiforme appeared was triggered by taking carbamazepine as the drug of choice for trigeminal neuralgia therapy. These drugs can cause type III hypersensitivity reaction. The final diagnosis based on anamnesis history of taking carbamazepine before lesions erupted and the characterized clinical manifestation.

Key words: erythema multiforme, carbamazepine, hypersensitivity

ABSTRAK

Latar belakang: Erythema multiforme adalah penyakit mukokutaneus akut yang menyerang kulit dan mukosa sebagai akibat dari reaksi hipersensitivitas. Secara karakteristik ditandai oleh lesi target pada kulit atau lesi ulserasi pada mukosa rongga mulut. Etiologi penyakit ini belum jelas, diduga karena adanya reaksi imunologi. Pencetusnya dikarenakan adanya pemakaian obat-obatan tertentu seperti antibiotik, antikonvulsan dan NSAID. Banyak dokter gigi kurang memahami mekanisme timbulnya penyakit ini, sehingga oleh masyarakat dianggap sebagai malpraktek. **Tujuan:** Tulisan ini melaporkan kasus pasien pria berusia 46 tahun dengan keluhan sariawan dan bibir terkelupas dan sakit setelah sehari minum obat karbamazepin. **Kasus:** Diagnosis klinis kasus ini adalah erythema multiforme karena reaksi hipersensitivitas terhadap pemakaian obat karbamazepin. **Tatalaksana kasus:** Diagnosis ditegakkan berdasarkan anamnesis riwayat pemakaian obat sistemik dan manifestasi klinis dari erythema multiforme pada rongga mulut. **Pengobatan yang diberikan** adalah antihistamin, kortikosteroid oral, obat kumur dengan anastesi topikal, kortikosteroid topikal dan antibiotik topikal. **Kesimpulan:** Dapat disimpulkan bahwa erythema multiforme yang timbul pada kasus ini dipicu oleh pemakaian obat karbamazepin yang merupakan obat pilihan untuk terapi trigeminal neuralgia. Obat ini menimbulkan efek samping reaksi hipersensitivitas tipe III. Diagnosis ditegakkan berdasarkan anamnesa riwayat pemakaian obat karbamazepin sebelum timbulnya lesi dan pemeriksaan klinis pada pasien.

Kata kunci: Erythema multiforme, karbamazepin, hipersensitivitas

Correspondence: Maharani Laillyza Apriasari, c/o: Program Studi Kedokteran Gigi Fakultas Kedokteran Gigi Universitas Lambung Mangkurat. Jl. A. Yani Km 36 Banjarbaru Kalsel, Indonesia. E-mail: rany.rakey@gmail.com

INTRODUCTION

Erythema multiforme is an acute mucocutaneous disease which is caused by the hypersensitivity reaction. It is characterized by target lesions on the skin or ulcerative oral lesion. In the serious case, it is named Steven Johnson's syndrome. It attacks eyes, mouth, genital, and skin. 20–30% of erythema multiforme patients suffer it in oral mucous lesion as ruptured multiple vesicle and it leaves large erosion covered by white pseudo membrane.^{1–3} The disease always attack young people especially men and rarely attack children and old people.⁴

There are two kinds of erythema multiforme, they are minor type and major type. Major type of erythema multiforme has serious degree condition which is called Steven Johnson's syndrome. It is an acute disease. It is started by the symptoms like fever, dizzy, and malaise. Less than 24 hours, it appears explosive lesion on the skin and the mucosa. The lightest lesions on the skin are macula and papule with 0.5–2 cm diameter. Lesion on the oral cavity is started by vesicle and bulla which is very easy to be ruptured. It has a specific clinical manifestation which can be fatal because of secondary infection and unbalance electrolyte liquid.^{3,5}

Etiology of the disease is unclear. Hipersensitivitas reaction that appears as erythema multiforme can be triggered by taking various drugs like antibiotic, barbiturate, phenylbutazone and carbamazepine.^{1,2,6}

Carbamazepine is a drug of choice for trigeminal neuralgia. It also can be use to cure headache because of neuropathy pain, but the side effects of carbamazepine therapy are always happened. Twenty five percents of all patient which have been given carbamazepine got the side effects like dizzy, vertigo, ataxia, diplopia, and blurred eyes. This drug can cause hypersensitivity like Steven Johnson's syndrome and dermatitis. Steven Johnson's syndrome is always happened relatively, so that the patient must be reminded for returning to the doctor if there is vesicle appeared on the skin or oral mucous.^{7,8}

This paper reported the case of erythema multiforme in the oral cavity as a reaction of hypersensitivity caused by carbamazepine therapy. Most of the dentists do not know about erythema multiforme mechanism, so a lot of people consider it as a malpractice. The clinical manifestation and anamnesis about history of this disease are very important, because it is related to the triggering factors that can make final diagnosis accurately so they can give the therapy as soon as possible.

CASE

A 46 years old male patient came to Oral Medicine Department of Faculty of Dentistry Airlangga University suffering arthralgia, fever and malaise. Hands and foot feel numb. Previously, the patient came with seriously pain on

the right face then it was diagnosed as trigeminal neuralgia. Patient had been given carbamazepine 100 mg which are taken 3×0.5 tablet/day. The next day after the patient had taken this drug for one day, there were oral ulcerative pain, peeled lips, and feeling wounded face. The patient had stopped taking the drugs, and then patient gave revanol on his peeled lips, while the right face was still painful.

CASE MANAGEMENT

On 27 May 2008, extra oral examination showed the upper and lower lips of the patient had hyper pigmentation, painful, yellow and red crusted. Intra oral examination could not be done, because of the pain (Figure 1).

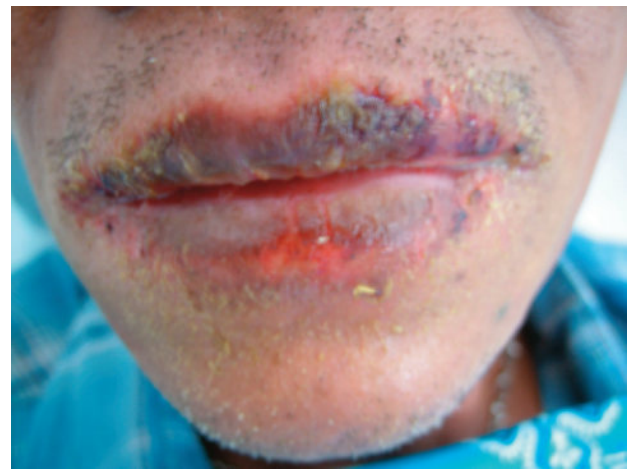

Figure 1. Visit 1: There was hyper pigmentation, yellow and red crusted on upper and lower lips.

Based on anamnesis and clinical examination, it could be concluded that the final diagnose was erythema multiforme. Patient was given feksofenedin 120 mg 1×1 /day at night, prednisone 5 mg 3×2 /day, benzydamin HCl gargle 2×1 /day, zalf contain of hydrocortisone 125 gr, chemisitin 0.5 gr, lanolin, and vaseline was spread on his upper and lower lips 3×1 /day after eating. The patient had been required to consume soft meals and liquid with high calorie and protein; like milk, fruit juice, and bread. Patient was asked to come 3 days later.

On 29 May 2008 (control 1), based on the anamnesis on the 3rd day, the pain of oral ulcerative were decreased. The patient had been able to eat.

Extra oral examination showed the crusted, peeled, and bleeding on the upper and lower lips. There was yellow crusted on the corner of the lips. Intra oral examination showed that there were ulcer, multiply, 1.2 cm in diameter, irregular form, indurate barrier, and white pseudo membrane on the right cheek mucous. There was also the other ulcer with 5 mm diameter, irregular form, flat barrier, and white pseudo membrane rounded by red areas (Figure 2 & 3).

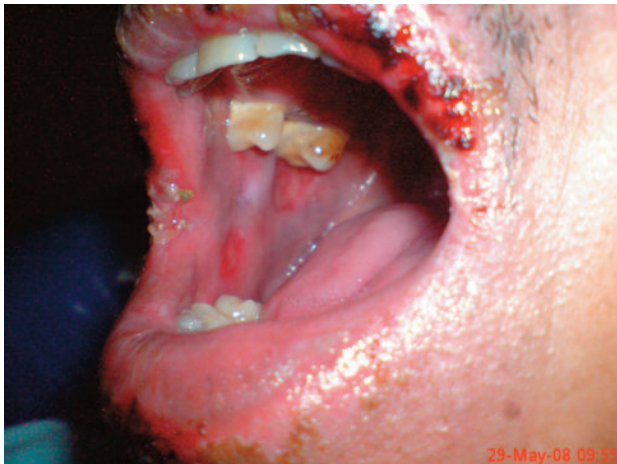

Figure 2. Visit 2: There were ulcers, multiply, irregular form, red barrier and white pseudo membrane.

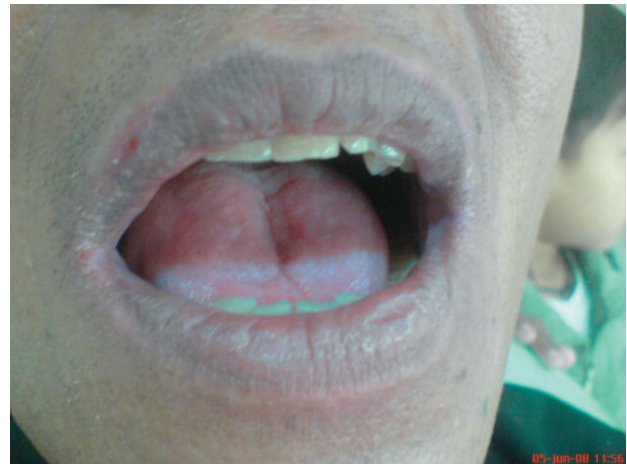

Figure 4. Visit 3: There were red crusted and peeled on upper lip and corner lips.

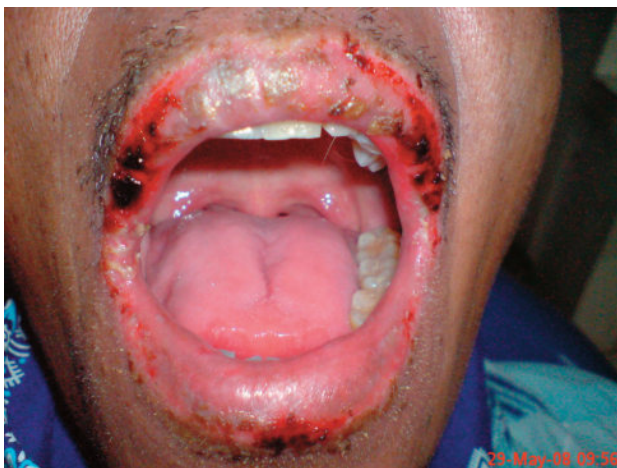

Figure 3. Visit 2: There were crusted, peeled and bleeding on upper and lower lips.

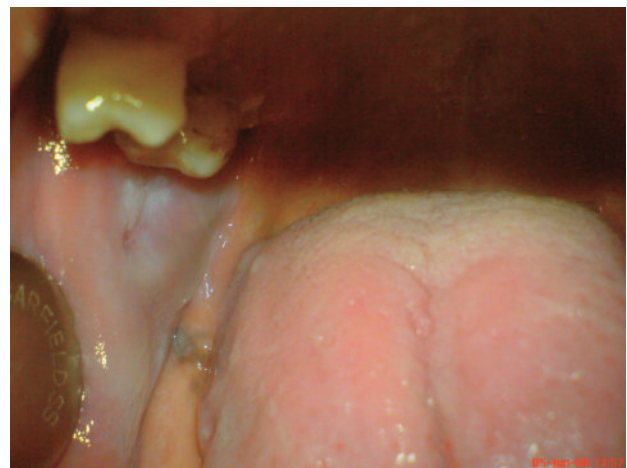


Figure 5. Visit 3: There were white cicatrix and irregular form.

The patient was asked to continue taking feksofenedin tablet 120 mg, benzydamin HCl gargle, prednisone 5 mg 3×1/day, zalf contain of hydrocortisone 125 gr, chemisitn 0.5 gr, lanolin, and vaseline was spread on his upper and lower lips 3×1/day after eat. Patient was asked to come again 3 days later.

On 5 June 2008 (control 2), based on anamnesis it could be shown that there was no pain on the right mucous cheek and lips. The patient was able to eat, but his serious pain on his right face was not cured, especially when he tried to move. During this week, the pain on his right face was more serious.

Extra oral examination showed the red crusted and peeled on the upper lip and the corner lips. Intra oral examination showed irregular white cicatrix on the right buccal mucous (Figure 4 & 5).

The patient was asked to continue taking the drugs and sent to UPF neurology RSUD Dr. Sutomo to recover his Trigeminal Neuralgia, because the drug replacement was the responsible of the specialist of neurology.

DISCUSSION

Erythema multiforme is an acute mucocutaneous disease which is caused by the hypersensitivity reaction. It is characterized by target lesions on the skin or ulcerative oral lesion. The diseases always happen to young people especially men and rarely attack children and old people.¹⁻⁴ Erythema multiforme is type III hypersensitivity reaction as the result of antigen antibody complex increased which makes the vasculitis. Specific factors of vasculitis in immune complex is caused by the hypersensitivity reaction as a result of the use of various drugs, microorganism, radiotherapy, systemic disease, and cancer.⁶ Final diagnosis of erythema multiforme must be supported by accurate anamnesis and characteristic clinical signs. The specific clinical manifestation like target lesion, can also be found in the skin. If there is no target lesion, it will difficult to make the diagnose, and the differential diagnose is primary herpetic stomatitis.¹⁰

This case was about a patient with erythema multiforme in oral cavity without skin lesion. The lesion erupted in oral cavity after the patient had been taking carbamazepin as trigeminal neuralgia therapy. When the hypersensitivity reaction appeared, the patient stopped taking the drug, so the erythema multiforme reaction was not become serious and the skin lesion eruption can be avoided.¹¹

Carbamazepin was the triggering factor of erythema multiforme. The lesion typically affect the oral mucosa, the lips, and bulbar conjunctivae. Initial bullae rupture caused hemorrhagic pseudomembrane of the lips and made superficial oral ulcerates were need.¹²

Hypersensitivity reactions occur as a result of an individual's immune system responding to an inappropriate stimulus, which may take the form of the drug-modified self-protein subsequent to drug bioactivation.¹³ Based on immunopathology, erythema multiforme occurred because of the type III hypersensitivity reaction that makes immune complex reaction of antigen antibody. The pathogenesis of systemic immune complex disease can be divided into three phases: formation of antigen-antibody complex in the circulation, deposition of the immune complex in various tissues, and an inflammatory reaction at the sites of immune complex deposition.¹⁴

The first phase is initiated by the introduction of antigens, it is resulting in the formation of specific antibodies. In circulation, they make antigen antibody complex. If antigens are not removed by stopping the drug or replacing it with the other drugs. It will make the antigens stay longer in circulation. It makes deposition of the immune complex in various tissues and continues to form vasculitis.^{15,16}

Immune complex which leave the circulation can deposit in or out of the blood vessels and will make blood vessels permeability increased. This condition is signed by immune complex that is related to inflammatory cell through Fc and C3b receptors. The receptor can trigger mast cell release and basophile that release various mediator of vasoactive and cytokine. Complement can make cell lyses if immune complex have deposited in various tissues. Vasoactive substance that is formed by mast cell and trombocyt can make vasodilatation, increased of vascular permeability, and inflammation. Neutrophile will go out to eliminate immune complex, but when neutrophile was encircle by tissues, it will be difficult to eliminate immune complex, as a results of granular released by neutrophile that increase the tissue destruction.^{13,16}

When immune complex condition is deposited in the tissues, it will form the reaction of inflammation at the 3rd phase. In this phase there are fever symptoms, urticaria, arthralgia, and lymphadenopathy.^{12,13,15} It happens in the first form of erythema multiforme, then followed by the clinical manifestation. Prodromal symptoms were not as serious as virus infection disease.

The main therapy of the patient was to stop taking carbamazepine, then the patient was given feksofenedin 120 mg 1×1/day in the night, prednisone 5 mg 3×2/day,

benzydamin HCl gargle 2×1/day, zalf contain of hydrocortisone 125 gr, chemisitin 0.5 gr, lanolin, and vaselin was spread on his upper and lower lips 3×1/day after eat.

Feksofenedin is an antihistamine without sleepy effect. This 2nd generation antihistamine inhibit H1 receptor which is useful for curing hypersensitivity reaction where mast cell has released histamine. Histamin is stimulated by the complement, and antigen antibody complex is formed on erythema multiforme.^{8,16}

Therapy for erythema multifome is giving oral corticosteroid. In the beginning, the patient takes prednisone 30 mg/day. In the simple case the patient can take prednisone 20–40 mg/day during 4–6 days. Then dosage can be decreased through tapering off the dosage which is given not more than 2 weeks.⁷ Action prevent the adrenal crisis, because this drug can disturb adrenal gland as the producer of natural steroid.

Prednisone is the oral corticosteroid with intermediate work (class 1 immunosuppressant). This drug is given before induction phase, is formed in the immune response of the body before antigen stimulation happened. The immunosuppressant effect of this drug can be reached through: inhibiting fagocytosis process and antigen process to be immunogenic antigen by macrophage, inhibiting antigen introduction by immunocompetent lymphoid cell, and destroying immunocompetent lymphoid cell.⁸

The other therapy is by using topical drugs in oral cavity. It can be given gargle contain of topical anesthetic and zalf contains of topical corticosteroid, antibiotic, lanolin and vaseline that was spread on his upper and lower lips. These drugs remove the inflammation, uncomfortable feeling, and prevent secondary infection.^{1,18}

On the last visit, the patient was sent to UPF neurology RSUD Dr. Sutomo to recover his Trigeminal Neuralgia, because the drug replacement was the responsible of the specialist of neurology. Several non-drug therapies have been recommended if pharmacologic treatment is unsuccessful. The most popular therapies were transcutaneous electrical nerve stimulation, lasers and several surgical approaches.¹

It can be concluded that erythema multiforme can be triggered by the use of carbamazepine as the drug of choice of trigeminal neuralgia. This drug caused type III hypersensitivity reaction. The final diagnosis based on anamnesis the history of taking carbamazepine before lesion eruption and the characteristics clinical manifestation.

REFERENCES

1. George L. Treatment of oral disease: A concise textbook. Stuttgart, Germany: Thieme; 2005. p. 66–7.
2. Cawson RA, Odell EW. Cawson's essentials of oral pathology and oral medicine. 7th ed. London: Churchill Livingstone; 2002. p. 205–7.
3. Regezi AJ, Sciubba JJ, Jordan CKR. Oral pathology: Clinical pathologic correlations. 4th ed. USA: Saunders Elsevier; 2003. p. 44–6.
4. Langlais RP, Miller CS. Color atlas of common oral disease. 3rd ed. Philadelphia, Pennsylvania: Lippincott Williams & Wilkins; 2003. p. 151.

5. David W, Lowe DOG, Dagg HJ, Felix HD, Scully C. Textbook of general and oral medicine. London: Churchill Livingstone; 2001. p. 238–9.
6. Glick M, Greenberg SM. Burket's: Oral diagnosis and treatment. 10th ed. Hamilton, Ontario: BC Decker Inc; 2003. p. 208–11.
7. Yagiela AJ, Dowd JF, Neidle AE. Pharmacology and therapeutics for dentistry. 5th ed. St Louis, Missouri: Elsevier Mosby; 2004. p. 392–3.
8. Tim Farmakologi Fakultas Kedokteran Universitas Indonesia. Farmakologi dan terapi. Edisi 5. Jakarta: Bagian Farmakologi Fakultas Kedokteran Universitas Indonesia; 2007. p. 252, 495–8, 707.
9. Field A, Longman L. Tyldesley's oral medicine. 5th ed. New York: Oxford University Press; 2004. p. 135–6.
10. George L. Pocket atlas of oral disease. Stuttgart, New York: Thieme; 2006. p. 108–13.
11. Shah KN, Honig J Paul, Yan C Albert. Urticaria multiforme: A case series and review of acute annular urticarial hypersensitivity syndrome in children. *Journal Watch Dermatology* 2007; 119(5): 117–83.
12. Scully C, Bagan JV. Adverse drug reactions in the orofacial region. *J Oral Biol Med* 2004; 15: 221.
13. Kumar V, Cotran SR, Robbins LS. **Pathologic basis of disease**. 7th ed. Philadelphia, Pennsylvania: Elsevier Saunders; 2005. p. 128–30.
14. Naisbitt DJ, Britschgi M, Guong G, Farrell J, Depta JPH, Chadwick DW, Pichler WJ, Pirmohamed M, Park BK. Hypersensitivity reactions to carbamazepine: characterization of the specificity, phenotype, and cytokine profile of drug-specific T cell clones. *Journal Molecular Pharmacology* 2003; 63:732–41.
15. Roeslan BO. Imunologi kelainan di dalam rongga mulut. Jakarta: Abadi Dhaya Insani; 2000. p. 69–76, 86–9.
16. Baratawidjaja KG. Imunologi dasar. Edisi 6. Jakarta: Fakultas Kedokteran Universitas Indonesia; 2004. p. 180–6.
17. Zlotoff B, Leggott J, Doherty S. Cutaneous reactions to drugs in children. *Journal of the American Academy of Pediatrics* 2007; 120: 1082–96.
18. Sen P, Chua SH. A case of recurrent erythema multiforme and its therapeutic complication. *J Ann Acad Med Singapore* 2004; 33:793–6.