

# Pityriasis rubra pilaris-like eruption following insulin therapy initiation

Talel Badri<sup>1</sup>, Anissa Zaouak<sup>1</sup>, Ghazlane Lakhoua<sup>2</sup>, Wafaa Koubaa<sup>3</sup>, Sami Fennich<sup>1</sup>, Ahmed Zaiem<sup>2</sup>

<sup>1</sup> Department of Dermatology, Habib Thameur Hospital, Faculty of Medicine, University of Tunis El Manar, Tunisia

<sup>2</sup> National Center of Pharmacovigilance, Faculty of Medicine, University of Tunis El Manar, Tunisia

<sup>3</sup> Laboratory of Pathology, Habib Thameur Hospital, Faculty of Medicine, University of Tunis El Manar, Tunisia

**Key words:** pityriasis rubra pilaris, insulin, drug-induced, cutaneous rash, skin

**Citation:** Badri T, Zaouak A, Lakhoua G, Koubaa W, Fennich S, Zaiem A. Pityriasis rubra pilaris-like eruption following insulin therapy initiation. *Dermatol Pract Concept* 2016;6(4):4. doi: 10.5826/dpc.0604a04

**Received:** May 31, 2016; **Accepted:** July 30, 2016; **Published:** October 31, 2016

**Copyright:** ©2016 Badri et al. This is an open-access article distributed under the terms of the Creative Commons Attribution License, which permits unrestricted use, distribution, and reproduction in any medium, provided the original author and source are credited.

**Funding:** None.

**Competing interests:** The authors have no conflicts of interest to disclose.

All authors have contributed significantly to this publication.

**Corresponding author:** Talel Badri, MD, Department of Dermatology, Habib Thameur Hospital, 8 rue Ali Ben Ayed, 1008 Tunis, Tunisia. Tel. +216.98.829.300. Email: talel\_badri@yahoo.fr

**ABSTRACT** Pityriasis rubra pilaris (PRP) is a chronic disorder of keratinization of unclear pathogenesis. PRP-like eruptions induced by drugs have rarely been described. A previously healthy 29-year-old man presented with a generalized, rapidly spreading, erythematous scaly dermatosis, that started three days after initiation of subcutaneous insulin therapy for diabetes mellitus type 1. Clinical and histopathological features were consistent with a PRP-like eruption, possibly due to insulin therapy. The patient was switched to insulin analogue therapy and a complete healing of all lesions was achieved after two months. No recurrence was seen after one year of follow-up. Other possible etiologies of PRP were excluded. The mechanism leading to the occurrence of drug-induced PRP-like eruptions are not clear. Since PRP may occur in the context of immunological anomalies, it is possible that diabetes mellitus type 1 may have been a predisposing condition for the development of PRP in this case.

## Introduction

Pityriasis rubra pilaris (PRP) is a chronic disorder of keratinization of unclear pathogenesis [1]. It typically manifests as erythematous and scaly cutaneous plaques with islands of spared skin associated with follicular scaly papules and orange palmar and plantar keratoderma.

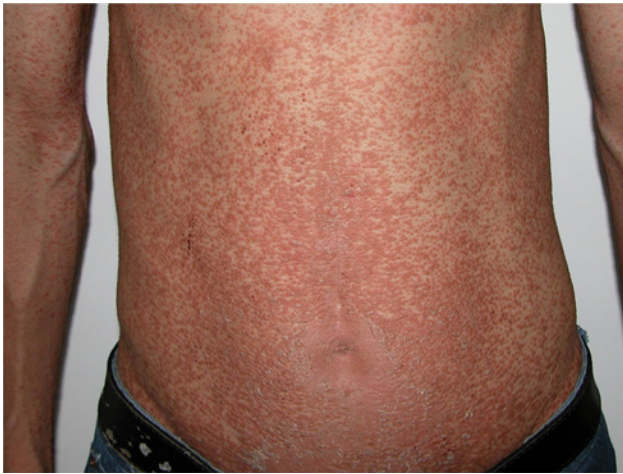Although PRP is usually idiopathic, certain trigger events have occasionally been reported, mainly traumatic, infectious (infections of streptococcus, cytomegalovirus and rubella) or

after vaccination [2]. However, PRP-like eruptions induced by drugs have been described, albeit rarely [3-5].

We report a case of PRP-like eruption that occurred during the initiation of insulin therapy. To our knowledge, no previous similar cases have been reported.

## Case report

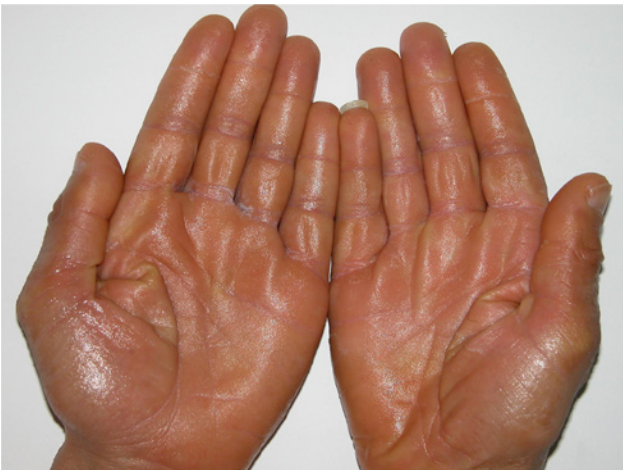A 29-year-old man was referred to our department because of a generalized erythematous scaly and non-pruritic der-



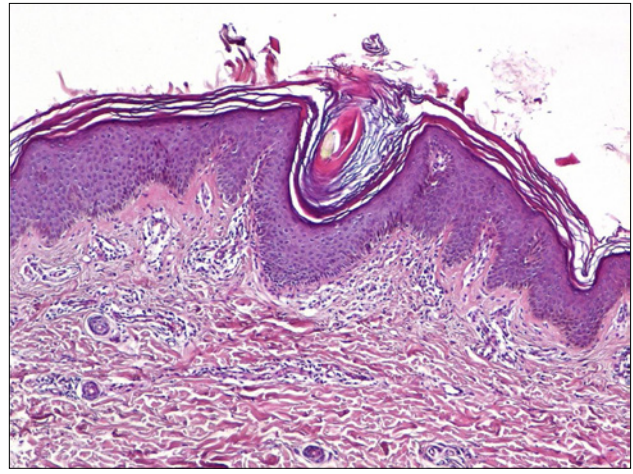
**Figure 1.** Erythematous scaly papules coalescent into large plaques on the trunk. [Copyright: ©2016 Badri et al.]

matosis that had rapidly spread during the previous week. It had started three days after initiation of Insulatard® ([Neutral Protamine Hagedorn insulin]: 12 IU in the morning; 8 IU in the evening) and Actrapid® ([soluble regular insulin]: 4 IU b.i.d.) for a recently diagnosed diabetes mellitus type 1. The patient's past medical history showed neither personal nor familial previous episodes of papulosquamous disorders. No other medical condition or concomitant medication intake were noticed. The patient had not received any vaccination during the previous five years and he denied any trauma.

Cutaneous examination revealed large areas of erythematous orange scaly plaques with small islands of uninvolved skin, as well as follicular keratotic papules. These lesions were located on the trunk (Figure 1) and limbs. The patient also had an orange-red waxy keratoderma on his palms and soles with some fissures (Figure. 2). No nail changes and no mucous membrane involvement were observed. There was no other organ or systemic involvement.



**Figure 2.** Bilateral orange-red waxy keratoderma. [Copyright: ©2016 Badri et al.]



**Figure 3.** Irregular hyperkeratosis with alternating orthokeratosis and parakeratosis and cornelial plugs characteristic of pityriasis rubra pilaris (hematoxylin-eosin X100). [Copyright: ©2016 Badri et al.]

## Histopathology

A skin biopsy was performed, and histopathological examination revealed irregular hyperkeratosis with orthokeratosis and parakeratosis in addition to dilated hair follicles and keratinous plugs (Figure 3).

## Diagnosis and outcome

A diagnosis of a PRP-like eruption, possibly induced by insulin therapy, was suspected. Insulatard® and Actrapid® were discontinued and the patient was switched to insulin analogue therapy: glargine (Lantus®) and glulisine (Apidra®). Skin lesions were treated with betamethasone ointment (30 g daily) and petrolatum. A progressive resolution of the rash was obtained and complete healing of all cutaneous lesions was achieved after two months. Skin tests (patch test and intradermal test) with insulin and its additives were considered but the patient refused them. No recurrence of skin lesions was seen after one year of follow-up.

## Discussion

The acute onset of the dermatosis after insulin therapy initiation, the rapid favorable outcome after human insulin withdrawal, as well as the absence of recurrence after one year of follow-up, were suggestive of a possible responsibility of insulin therapy for the genesis of the PRP-like eruption in our patient. Although possible, a fortuitous association “insulin therapy—idiopathic PRP” seems unlikely in our case because of the rapid resolution of the rash, as opposed to the classical chronic course of idiopathic PRP, even with the use of systemic treatments, such as retinoids [1].

Drug-induced PRP-like eruptions are rare, and the mechanisms leading to their occurrence have not been clearly elu-

culated [2-5]. The pathogenesis in our patient is also unclear. Although insulin therapy is largely used worldwide, its association with PRP-like eruptions has never been reported. However, since PRP may occur in certain cases with underlying immunological anomalies [2], it is possible that diabetes mellitus type 1 might have contributed to the development of the dermatosis in our patient, after insulin therapy initiation.

Insulin preparations containing zinc or protamine (such as Insulatard®) may also cause a delayed-type hypersensitivity [6,7]. However, in the absence of skin tests, the role of such additives in the genesis of the dermatosis in our patient could not be determined.

## Conclusion

Although a fortuitous association could not totally be ruled out, a cutaneous reaction induced by insulin therapy in a context of underlying immunological anomalies might be the cause of the dermatosis in our patient.

## References

1. Gemmeke A, Schönlebe J, Koch A, Wollina U. Pityriasis rubra pilaris—a retrospective single center analysis over eight years. *J Dtsch Dermatol Ges* 2010;8(6):439-44. PMID: 15982236.
2. Naciri Bennani B, Cheikh Rouhou H, Waton J, et al. Pityriasis rubra pilaire après vaccination. *Ann Dermatol Venerol* 2011;138(11):753-6. PMID: 22078037. DOI: 10.1016/j.annder.2011.01.049.
3. Paz C, Querfeld C, Sbea CR. Sorafenib-induced eruption resembling pityriasis rubra pilaris. *J Am Acad Dermatol* 2011;65(2):452-3. PMID: 21763585. DOI: 10.1016/j.jaad.2010.03.015.
4. Plana A, Carrascosa JM, Villavella M, Ferrandiz C. Pityriasis rubra pilaris-like reaction induced by imatinib. *Clin Exp Dermatol* 2013;38(5):520-2. PMID: 23777493. DOI: 10.1111/ced.12081.
5. Schmutz JL, Trechot P. Telaprevir-induced pityriasis rubra pilaris-like drug eruption. *Arch Dermatol* 2012; 148(10):1215-7. PMID: 23069976. DOI: 10.1001/archdermatol.2012.2039.
6. Feinglos MN, Jegasothy BV. “Insulin” allergy due to zinc. *Lancet* 1979;1(8108):122-4. PMID: 84149.
7. Raap U, Liekenbrocker T, Kapp A, Wedi B. Delayed-type hypersensitivity to protamine as a complication of insulin therapy. *Contact Dermatitis* 2005;53(1):57-8. PMID: 15982236.