

Clinical Efficacy of Medical Dextrose Tincture Liquid in the Treatment of Facial Photoaging

Yuexing Song¹, Qiuhui Liu², Yihan Zhang², Huina Zhang³, Bin Li²

1 Department of Cosmetic Dermatology, Xi'an EVERCARE Medical Beauty Hospital, Xi'an, China

2 Department of Cosmetic Dermatology, Beijing EVERCARE Medical Beauty Hospital, Beijing, China

3 Beijing Evercare Medical Technology Group Co., Ltd, Beijing, China

Key words: medical dextran tincture liquid, facial photoaging, clinical efficacy

Citation: Song Y, Liu Q, Zhang Y, Zhang H, Li B. Clinical Efficacy of Medical Dextrose Tincture Liquid in the Treatment of Facial Photoaging. *Dermatol Pract Concept*. 2023;13(1):e2023015. DOI: <https://doi.org/10.5826/dpc.1301a15>

Accepted: May 5, 2022; **Published:** January 2023

Copyright: ©2023 Song et al. This is an open-access article distributed under the terms of the Creative Commons Attribution-NonCommercial License (BY-NC-4.0), <https://creativecommons.org/licenses/by-nc/4.0/>, which permits unrestricted noncommercial use, distribution, and reproduction in any medium, provided the original authors and source are credited.

Funding: None.

Competing Interests: None.

Authorship: All authors have contributed significantly to this publication

Corresponding Author: Bin Li, Beijing EVERCARE Medical Beauty Hospital, Building A, No.3 East Third Ring North Road, Chaoyang District, Beijing, 100027 China. Tel: 86-010-82037778 Email: binli1228@163.com

ABSTRACT **Introduction:** Exogenous aging mainly refers to photo-aging, which is caused by environmental factors including ultraviolet exposure. Dextran is a homopolysaccharide composed of glucose as monosaccharide, and glucose units are connected by glycosidic bonds.

Objectives: The purpose of this study was to explore the clinical efficacy of medical dextrose tincture liquid (medical dextrose tincture) in the treatment of facial photoaging.

Methods: Thirty-four volunteers were included in the randomized double-blind study. According to the random number table method, the subjects were randomized into control and treatment groups. The subjects in the control and treatment groups were treated with medical hyaluronic acid gel and medical dextrose tincture, respectively. They received mesotherapy therapy three times with an interval of 28 days between treatments. Video image acquisition was performed before treatment and 28 days after treatment. Skin moisture content, glossiness, heme content, collagen density, and elasticity were tested. The subjective evaluations of subjects and doctors before and after treatment were compared.

Results: Compared with the pre-treatment baseline, medical dextran tincture significantly increased skin moisture retention, skin gloss, and skin collagen density ($p < 0.001$). Additionally, the skin retraction time was significantly reduced, and the skin retraction time was also markedly decreased after treatment with medical dextran tincture ($p < 0.001$). The effects of medical dextran tincture were more significant in comparison with medical hyaluronic acid gel ($p < 0.05$). The subjective evaluation results

of doctors showed that after 84 days of treatment, the overall skin photoaging score was significantly reduced ($p < 0.001$). The subjective evaluation results of volunteers showed that the various skin problems of more than 50% of volunteers were improved after treatment.

Conclusion: Medical dextran tincture has obvious effects of moisturizing, increasing luster, improving skin redness, increasing skin collagen content and enhancing skin elasticity.

Introduction

Skin is the largest organ of the human body, and its aging is a complex process caused by a variety of endogenous and exogenous factors [1]. Endogenous aging is inherent, that is, natural aging that develops over time. Exogenous aging mainly refers to photo-aging, which is caused by environmental factors including ultraviolet (UV) exposure. The clinical manifestations of naturally aging skin are decreased skin thickness, dryness and fine wrinkles [2]. However, the clinical manifestations in the skin caused by photoaging are deep wrinkles, roughness, relaxation, spotted pigmentation, telangiectasia and various skin tumors [3].

Exogenous aging damage caused by skin exposure to ultraviolet light (UV) is slow. UV radiation can affect skin pigment metabolism [4]. The immediate response is an increase in the reactive synthesis of melanin and its redistribution, and the delayed response is an increase in the number and vitality of melanocytes [4]. UV can upregulate the expression level of vascular endothelial growth factor (VEGF), resulting in the proliferation and expansion of capillaries [5]. At the same time, UV has an autoimmune inhibitory effect, resulting in the changed number and vitality of immune cells, and the expression of related cytokines [6]. The most relevant feature of photoaging caused by UV is the changes in the proportion, quality and function of the dermal extracellular matrix [7]. The main components of the dermal extracellular matrix are the collagen fiber network, elastic fiber network and proteoglycan [8]. The elastic fiber network provides elasticity to the skin, while proteoglycan plays a role in moisturizing and biological signal transduction. In exogenously damaged skin, these three components have undergone specific changes.

Dextran is a homopolysaccharide composed of glucose as monosaccharide, and glucose units are connected by glycosidic bonds [9]. According to the type of glycosidic bond, dextran can be divided into α -dextran and β -dextran. Dextran is a kind of widely studied and used α -dextran. In animal models, dextran materials showed good soft tissue filling effect and biocompatibility [10,11]. However, there are no relevant reports on clinical research on the therapeutic effects of dextrose on cosmetic dermatology and facial photoaging. Therefore, the purpose of this study was to explore

the clinical efficacy of medical dextrose tincture liquid in the treatment of facial photoaging.

Subjects and Methods

Subjects

All volunteers were informed of the purpose of the study in detail and signed the informed consent documents. A total of 34 volunteers were included in the randomized double-blind study. Inclusion criteria: (1) those whose face had symptoms of photo-aging, including dryness, dullness, lack of elasticity, etc.; (2) non-smokers; (3) individuals aged more than 18 years old. Exclusion criteria: (1) women who were menstruating, pregnant or breastfeeding; (2) those with a history of food or drug allergies and ethical contraindications; (3) those who had taken corticosteroids, antibiotics, tretinoin or other anti-acne medications two weeks before treatment; (4) those who had used hormone drugs and immunosuppressant in the past month; (5) those with obvious damage, redness, scars, active skin diseases, inflammation, or infection on the face; (6) those with symptoms of colds, headaches and fever on the day of the test; (7) those who were allergic to injection materials or certain ingredients in injection preparations; (8) those who had injected unknown fillers into the face that had not gone away before treatment.

Informed consent has been obtained from all the participants. This study was approved by the Ethics Committee of Xi'an EVERCARE Medical Beauty hospital (No. 20200501).

Treatment

Medical hyaluronic acid gel (Huaxi Furuida Biomedical Co., Ltd., Jinan, China) was marked as product A, and medical dextrose tincture liquid (Ningxia Miaolang Biotechnology Co., Ltd., Ningxia, China) was marked as product B. According to the random number table method, the subjects were randomized into control and treatment groups ($n = 17$). Each volunteer randomly selected product A and product B. The volunteers in the control and treatment groups were treated with medical hyaluronic acid gel and medical dextrose tincture, respectively. They received mesotherapy three times with an interval of 28 days. The steps of mesotherapy were as follows. Volunteers cleaned their faces

with mild soap. After topical anesthesia for 20-30 min, the face was cleaned again. Iodophor solution is used for disinfection and deiodination. The whole face was injected with the mesotherapy instrument, the injection depth was 0.8-12 mm, and the skin punctate hemorrhage was the standard. After treatment, the facial treatment area was covered with a sterile facial pack for 20-30 min.

Image Analysis

On the 0th, 28th, 56th and 84th day of treatment, visual images of the face were collected by VISIA image acquisition as previously described [13].

Skin Detection and Analysis

On the 0th, 28th, 56th and 84th day of treatment, skin moisture content test, skin gloss test, skin heme content test, skin collagen density test and skin elasticity test were carried out by MPA10 skin tester (CK, Germany) and Dermalab skin tester (CORTEX, Denmark). The effects of those two products on skin moisture content, skin gloss, skin tone, and anti-aging were assessed through the changes in those indexes. The test environment was 20.0°C-22°C, with a humidity of 40.0%RH-60.0%RH. At the junction of the middle line of the left eye and the nasal wing, the moisture content of the stratum corneum, skin gloss and skin heme were measured. The skin collagen density and skin elasticity were measured at the junction of the middle line of the right eye and the nasal wing.

Subjective Evaluation

For subjective evaluation by doctors, two dermatologists scored the degree of facial photoaging before treatment and after a course of treatment according to the VISIA image. The scoring standard was shown in Table 1. For subjective evaluation by volunteers, volunteers rated themselves in terms of skin color, wrinkles, luster, elasticity and moisturizing on the 28th day after each treatment. 0 points for deterioration, 1 point for ineffectiveness, 2 points for slight improvement,

3 points for obvious improvement and 4 points for complete improvement.

Evaluation Indexes

On the 0th, 28th, 56th and 84th day of treatment, the visual images of the face were analyzed. The moisture content of the stratum corneum, skin gloss and skin heme, skin collagen density and skin elasticity were analyzed. Skin subjective evaluation of doctors and volunteers was also assessed after treatment.

Statistical Analysis

IBM SPSS statistics 22 was used to make descriptive statistics on the measured values and the subjective evaluation scores. The measurement data were expressed as means \pm standard deviation (SD). The count data were expressed as a percentage. For the intra-group comparison before and after treatment, the measured values at different time points were compared with the initial values. If the data were normally distributed, *t*-test was used for statistical analysis. If the data were not normally distributed, *t*-test was used for statistical analysis.

Results

General Information

A total of 34 people completed this study. There were 17 volunteers in group A, including 1 man and 16 women, with an average age of 29.59 ± 1.05 years. There were 17 volunteers in group B, including 3 males and 14 females, with an average age of 31.35 ± 1.05 years. There were no significant differences in general information such as gender and age between the two groups ($p < 0.05$).

Comparison of Skin Moisture Content Between the Two Groups

After 28, 56 and 84 days of treatment, the skin moisture contents in group A were significantly increased by 18.0%,

Table 1. Overall score of photoaging.

Scores	Descriptions
0	The whole face is smooth, without obvious fine wrinkles and uneven pigment in any part of the cheek, forehead and eyes.
1	There is obvious roughness, uneven pigment (pigmentation or hypopigmentation) or fine wrinkles on one of the above three parts of the whole face.
2	There are obvious roughness, uneven pigment or fine wrinkles on two of the above three parts of the face, or rough, uneven pigment and fine wrinkles in one part at the same time.
3	There are obvious roughness, uneven pigment or fine wrinkles on the above three parts of the face, or rough, uneven pigment and fine wrinkles in two parts at the same time.
4	There is any situation heavier than 3 points on the face.

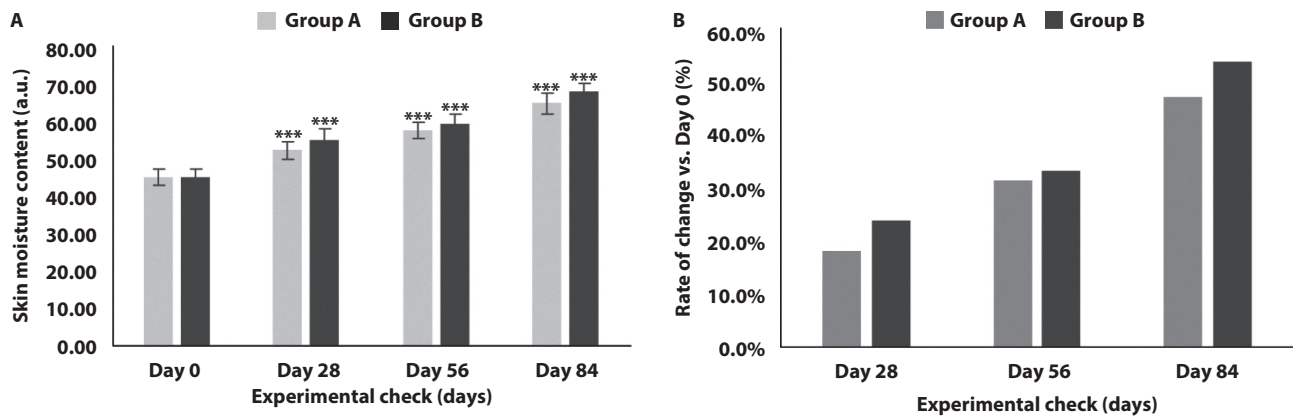


Figure 1. Changes in skin moisture content before and after treatment. (A) skin moisture content; (B) rate of change vs. Day 0. *** $p < 0.001$; ** $p < 0.01$; * $p < 0.05$ vs. Day 0.

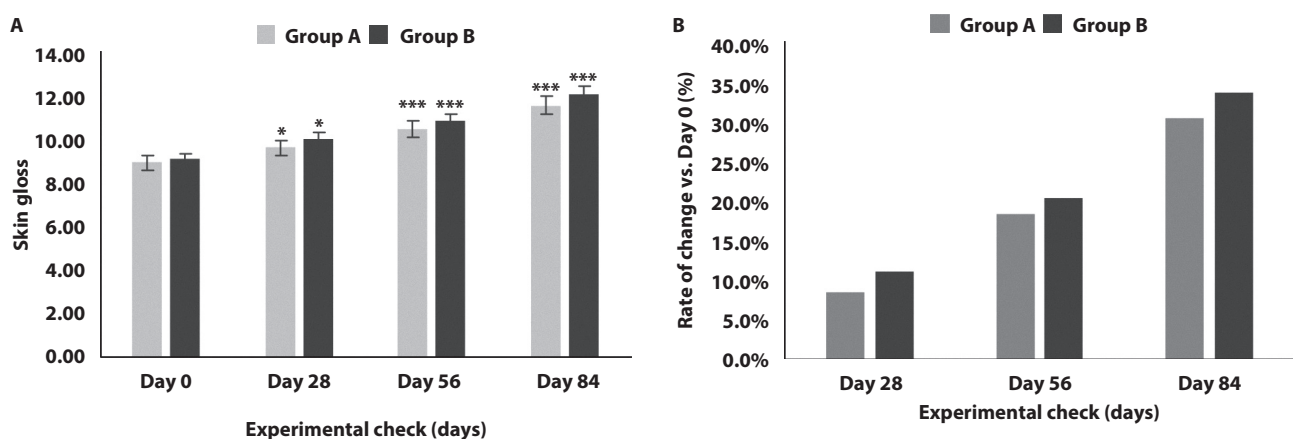


Figure 2. Changes in skin gloss before and after treatment. (A) skin gloss; (B) rate of change vs. Day 0. *** $p < 0.001$; ** $p < 0.01$; * $p < 0.05$ vs. Day 0.

31.4% and 47.0% in comparison with those before treatment, respectively ($p < 0.001$). After 28, 56 and 84 days of treatment, the skin moisture contents in group B were also notably increased by 23.9%, 33.2% and 53.6% compared with those before treatment ($p < 0.001$, Figure 1). Taken together, both products A and B had a moisturizing effect, which can significantly improve the moisture content of cheek cuticles. Particularly, the effect of product B was more obvious than product A.

Comparison of Skin Gloss Between the Two Groups

After 28, 56 and 84 days of treatment, skin gloss in group A was markedly increased by 8.4%, 18.3% and 30.3% in comparison with that before treatment, respectively ($p < 0.001$). After 28, 56 and 84 days of treatment, skin gloss in group B was also significantly increased by 11.0%, 20.4% and 33.7% compared with that before treatment, respectively ($p < 0.001$, Figure 2). In conclusion, both products A and B can significantly increase skin gloss.

Comparison of Skin Erythema Index Between the Two Groups

In group A, there was no significant difference in the changes in skin erythema index after 28 days, 56 days and 84 days of treatment in comparison with those before treatment ($p > 0.05$), indicating that product A had no significant change in skin heme contents (erythema index). In group B, the average skin heme content (erythema index) of volunteers before treatment, 28 days, 56 days and 84 days after treatment were 351.8 ± 15.2 , 332.9 ± 13.4 , 313.4 ± 11.2 and 303.01 ± 18.0 , respectively. Compared with that before treatment, the changes in skin erythema after treatment with product B were statistically reduced by 4.8%, 10.0% and 13.1% ($p < 0.001$, Figure 3). Taken together, product B can significantly reduce skin erythema index and improve skin redness.

Comparison of Skin Collagen Density Between the Two Groups

Although skin collagen density after treatment with product A was higher than that before treatment, the effect of

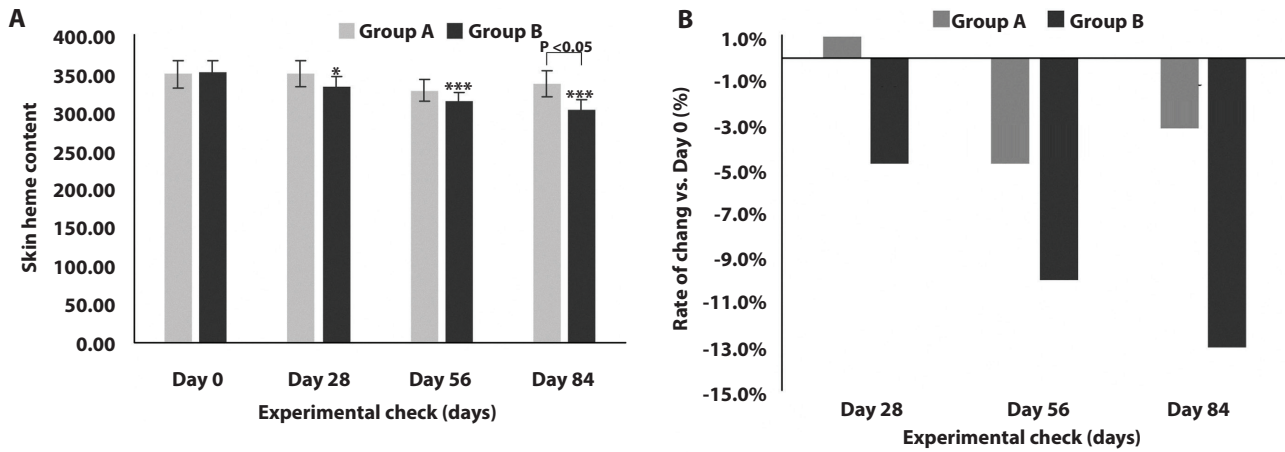


Figure 3. Changes in skin heme content before and after treatment. (A) skin heme content; (B) rate of change vs. Day 0. *** $p < 0.001$; ** $p < 0.01$; * $p < 0.05$ vs. Day 0.

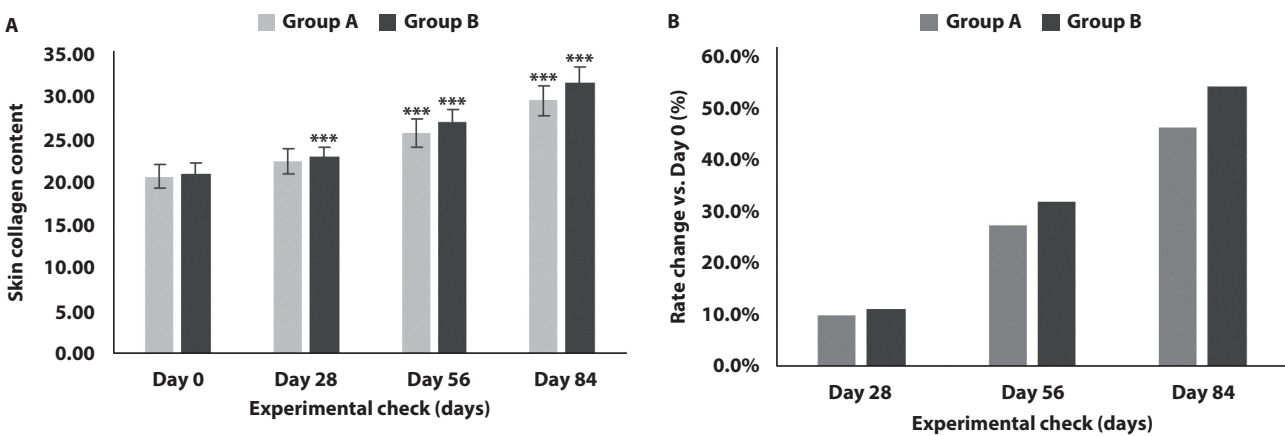


Figure 4. Changes in skin collagen density before and after treatment. (A) skin collagen density; (B) rate of change vs. Day 0. *** $p < 0.001$ vs. Day 0.

product A on skin collagen density showed significant differences after 56 and 84 days of treatment, with an increase of 26.4% and 44.9%, respectively ($p < 0.001$). After 28, 56 and 84 days of treatment, skin collagen density after treatment with product B was increased by 10.6%, 30.9% and 52.5% respectively compared with that before treatment ($p < 0.001$, Figure 4). In short, both products A and B can significantly increase skin collagen density, and the effect of product B on skin collagen density was significantly earlier than that of product A.

Comparison of Skin Elasticity Between the Two Groups

Skin retraction time is one of the indicators to measure skin elasticity. It refers to the time required for the skin to fully lift and retract to 33% of the peak height. The shorter the retraction time, the better the elasticity of the skin. After 56 and 84 days of treatment, compared with before treatment, the skin retraction time of product A group decreased by

4.4% and 5.4% respectively. After 28, 56 and 84 days of treatment, the skin retraction time in group B was decreased by 9.5%, 11.2% and 14.8% respectively in comparison with that before treatment ($p < 0.001$, Figure 5). As described above, product B can significantly reduce skin retraction time and enhance skin elasticity. The effect of product B on skin elasticity was significantly earlier than that of product A, and the effect of improving skin relaxation was better than that of product A.

Comparison of Subjective Assessments of Doctors and Volunteers Between the Two Groups

The lower the score of comprehensive skin improvement, the better the effect of the product on improving skin photoaging. Before treatment, the skin scores in group A and group B were 2.14 ± 0.1 and 2.30 ± 0.1 , respectively ($p > 0.05$). After three instances of treatment, the doctor's score was significantly lower than that before treatment ($p < 0.01$). According to the doctor's score, after 84 days of treatment, product A and product

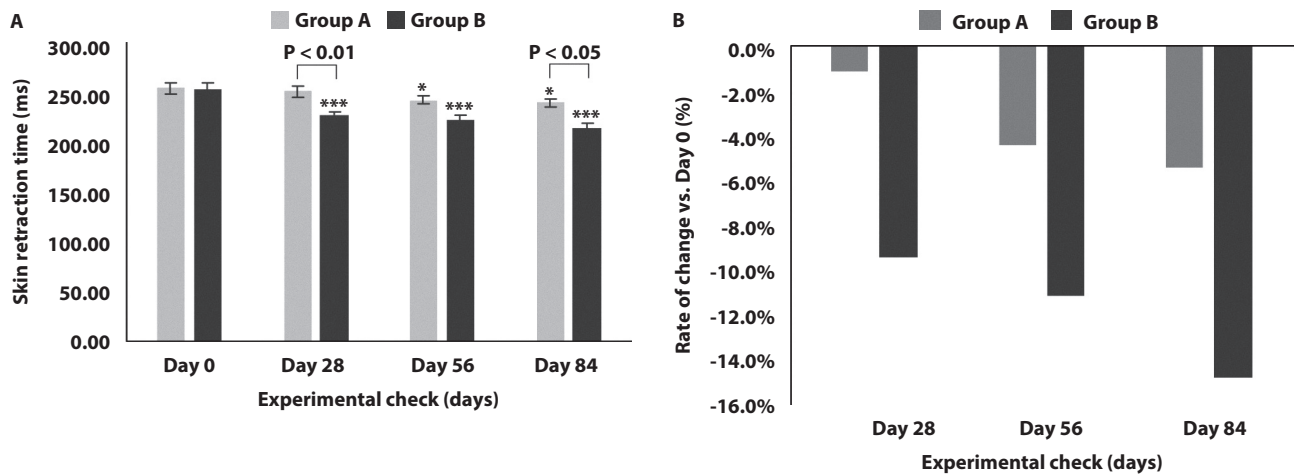


Figure 5. Changes in skin retraction time before and after treatment. (A) skin retraction time; (B) rate of change vs. Day 0. *** $p < 0.001$ vs. Day 0.

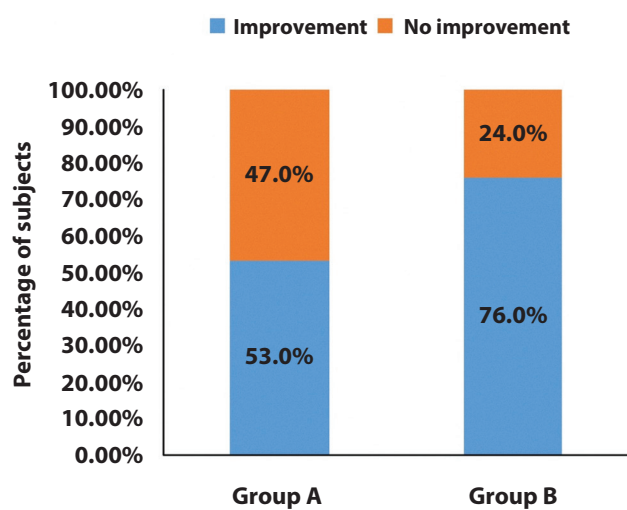


Figure 6. The percentage of volunteers who showed improvement and those who did not show improvement in the subjective evaluation score of doctors.

B improved the skin condition of 53% and 76% of volunteers, respectively ($P > 0.05$, Figure 6). Volunteers subjectively evaluated the treatment effect according to the improvement of skin color, wrinkles, elasticity, gloss and moisture contents. The higher the percentage of positive feedback, the more satisfied volunteers were. The clinical results were assigned and scored, and the higher the score, the better the treatment effect. After three treatments, the total score and positive response percentage of product B were higher than those of product A in the dimensions of skin color, wrinkles, elasticity, gloss and moisture contents (Fig. 7A, 7B).

Representative Image of the Treatment Effect of Product B

Fig. 8A is a case of improvement of dull and rough skin (volunteer No. 21, VISIA standard light source mode). After three instances of treatment with product B, the dullness and roughness of the volunteer's skin were significantly improved.

The skin color became brighter, the pores narrowed and the gloss increased. Figure 8B showed a case of skin redness and uneven complexion improvement (volunteer No. 25, VISIA standard light source mode). After three instances of treatment with product B, the volunteer's skin turned red, and the uneven skin color was significantly improved. The skin color was uniform, and the skin became bright and white. Figure 8C showed a case of skin redness and uneven complexion improvement (volunteer No. 25, VISIA standard light source mode). Figure 8C showed a case of skin redness improvement (volunteer No. 38, VISIA Red Areas light source mode photo). After three instances of treatment with product B, the volunteer's skin redness was significantly improved, the color of erythema became lighter, the red area became smaller, and skin inflammation was decreased. Figure 8D showed a case of skin redness and roughness improvement (volunteer No. 8, VISIA standard light source mode). After three instances of treatment with product B, the volunteer's skin dullness and roughness were significantly improved, the skin color became brighter, the pores narrowed and the gloss increased.

Discussion

Water light therapy is the accurate injection of nutrients or drugs into specific layers of the skin through hollow microneedles, which can effectively supplement nutrients, such as hyaluronic acid and vitamins [13]. Moreover, it can stimulate collagen production, make the skin moist and shiny, effectively delay skin aging and improve skin quality [14]. It can also treat diseases by injecting drugs [15]. The common drugs and components used in water light therapy can be divided into simple use of hyaluronic acid, non-crosslinked hyaluronic acid as carrier, matching with different nutrients, collagen preparation, mixed growth factor series, cocktail formula with multiple components or focusing on one component, polydeoxynucleoside, etc. [16].

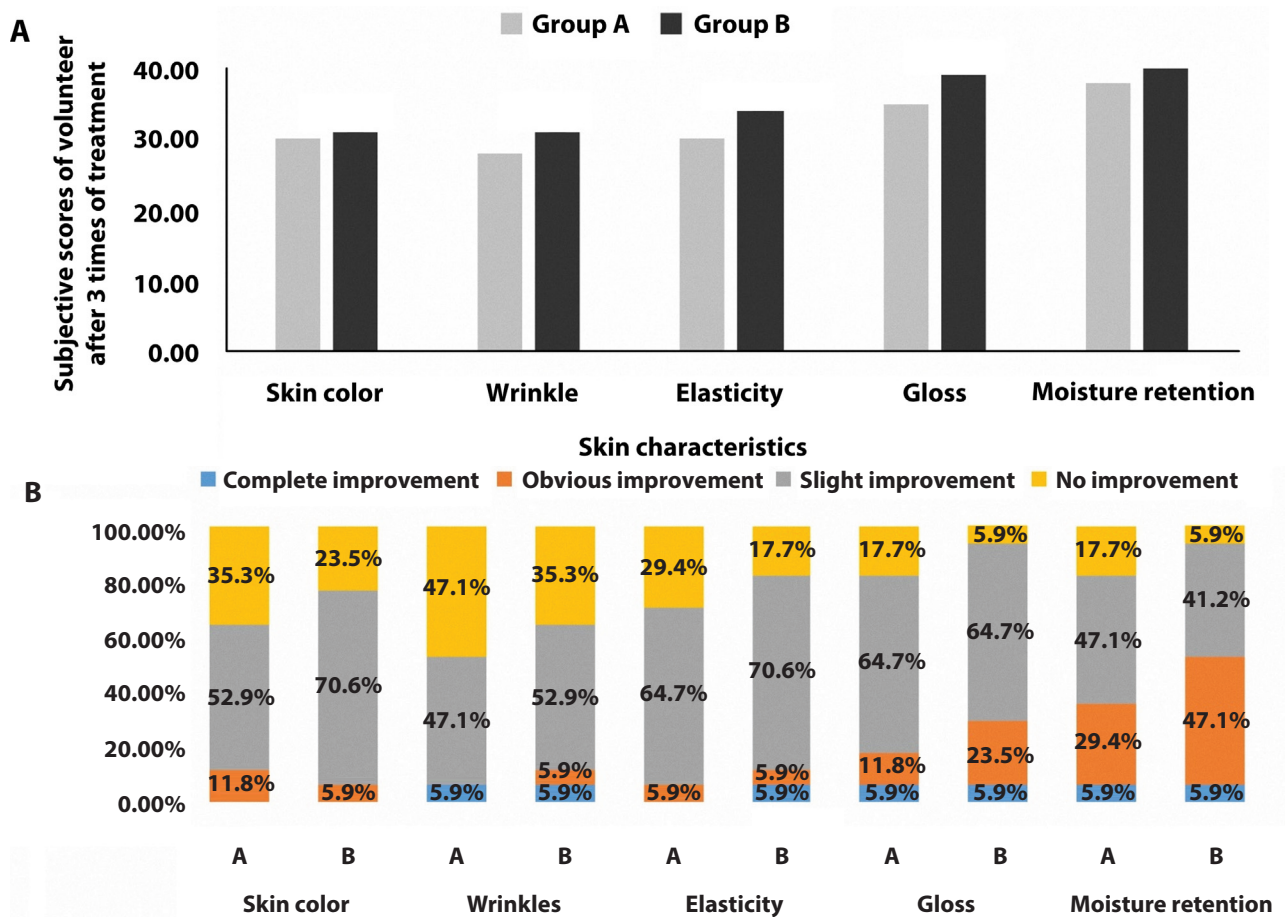


Figure 7. Efficacy evaluation after treatment. (A) results obtained from the questionnaire completed by volunteers after 84 days of treatment with product A and product B. The results are expressed as the total score of each volunteer's questionnaire. Complete improvement = 4 points, obvious improvement = 3 points, slight improvement = 2 points, no improvement = 1 point, deterioration = 0 points. The higher the score, the better the skin state; (B) After treatment, the percentage of each item in the volunteers' questionnaire.

Dextran is a kind of branched dextran polymer with molecular weight ranging from 1 kDa to 2000 kDa. The side chain degree of dextrose differs according to molecular weight [17]. The smaller the molecular weight, the lower the side chain degree. The closer the molecular weight distribution is, the different application emphases of different molecular weights are different [18]. Compared with other polymer materials, dextran has the advantages of good water solubility, biodegradability, small antigenicity and high safety, and it has been used as a plasma substitute in clinics [19, 20]. Therefore, dextran with the above characteristics has important application value in the field of skin rejuvenation treatment. The cross-linked dextran filler (Lipen De, Cheonghwa Medipower Corporation, Jangseoung, Korea) was approved by the Korean food and Drug Administration in 2012. Shin and his team have confirmed that it has a filling effect for more than six months for the treatment of nasolabial folds [21].

In this study, we explored the therapeutic effect of medical dextran as a new type of water-light injection material on skin photoaging. Our results showed that compared with that before treatment, medical dextran significantly increased skin moisture retention and skin gloss after 84 days

of treatment. It showed that medical dextran can significantly improve the roughness of the skin and increase the moisture content of the skin stratum corneum. In terms of moisturizing and improving skin gloss, medical dextran has the same improvement effect as sodium hyaluronate. Compared with that before treatment, medical dextran treatment significantly reduced skin erythema and redness. However, sodium hyaluronate had no significant effect in improving skin erythema. Compared with that before treatment, medical dextran treatment significantly increased skin collagen density, stimulated collagen production, and has an anti-aging effect. Particularly, the significant difference in the effect of medical dextran on skin collagen density appeared earlier than that of sodium hyaluronate, indicating that medical dextran can start and promote collagen regeneration faster. Compared with that before treatment, medical dextrose treatment can significantly reduce the skin retraction time, indicating that it can improve skin sagging problems, and the effect was significantly better than with sodium hyaluronate.

The subjective evaluation results of doctors showed that after 84 days of treatment with medical dextran and sodium

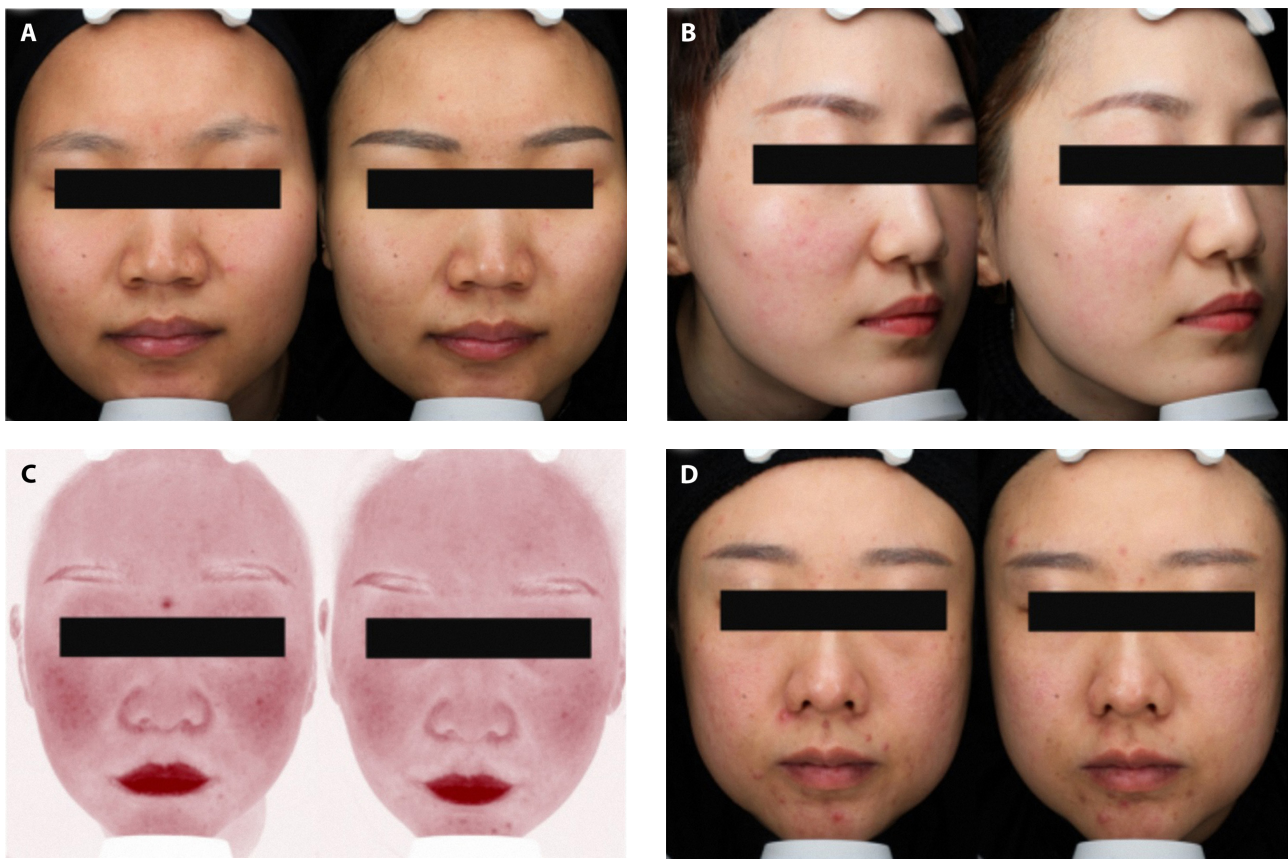


Figure 8. Representative images of improvement of dull, rough, reddish skin and uneven skin color. (A) Representative images of improvement of dull and rough; (B) Representative images of improvement of reddish skin and uneven skin color; (C) Representative images of improvement of reddish skin; (D) Representative images of improvement of reddish skin and rough.

hyaluronate, the overall score of the volunteers' photoaging was significantly reduced in comparison with that before treatment, indicating that they can significantly improve skin photo-aging problems, including skin roughness, dryness, lack of elasticity, etc. From the subjective evaluation results of volunteers, as the time of treatment increased, the percentage of positive responses from volunteers in various aspects, such as dry skin, skin gloss, uneven skin tone and dullness, skin elasticity, and skin wrinkles, gradually increased. Especially for gloss and elasticity, the overall improvement with medical dextran is better than with sodium hyaluronate.

Conclusion

In conclusion, medical dextran has obvious effects of increasing moisture content, increasing luster, improving skin redness, increasing skin collagen and enhancing skin elasticity. Medical dextrose is superior to hyaluronic acid in improving skin redness and skin relaxation.

References

1. Klinngam W, Rungkamoltip P, Thongin S, et al. Polymethoxyflavones from *Kaempferia parviflora* ameliorate skin aging in primary human dermal fibroblasts and ex vivo human skin. *Biomed Pharmacother.* 2021;145:112461.
2. Chung JH, Eun HC. Angiogenesis in skin aging and photoaging. *J Dermatol.* 2007;34(9):593-600.
3. Kosmadaki MG, Gilchrest BA. The role of telomeres in skin aging/photoaging. *Micron.* 2004;35(3):155-159.
4. Kim HM, Oh S, Yang JY, et al. Evaluating Whether Radiofrequency Irradiation Attenuated UV-B-Induced Skin Pigmentation by Increasing Melanosomal Autophagy and Decreasing Melanin Synthesis. *Int J Mol Sci.* 2021;22(19):10724.
5. Hartono SP, Bedell VM, Alam SK, et al. Vascular Endothelial Growth Factor as an Immediate-Early Activator of Ultraviolet-Induced Skin Injury. *Mayo Clin Proc.* 2021;S0025-6196(21):00643-1.
6. Vechtomova YL, Telegina TA, Buglak AA, Kritsky MS. UV Radiation in DNA Damage and Repair Involving DNA-Photolyases and Cryptochromes. *Biomedicines.* 2021;9(11):1564.
7. Fernando IPS, Heo SJ, Dias MKHM, et al. (-)-Loliolide Isolated from *Sargassum horneri* Abate UVB-Induced Oxidative Damage in Human Dermal Fibroblasts and Subside ECM Degradation. *Mar Drugs.* 2021;19(8):435.
8. Lin S, He X, He Y. Co-culture of ASCs/EPCs and dermal extracellular matrix hydrogel enhances the repair of full-thickness skin wound by promoting angiogenesis. *Stem Cell Res Ther.* 2021;12(1):129.
9. Zeng Y, Zhang X, Lin D, et al. A lysosome-targeted dextran-doxorubicin nanodrug overcomes doxorubicin-induced chemoresistance of myeloid leukemia. *J Hematol Oncol.* 2021;14(1):189.

10. Goldberg DJ. Breakthroughs in US dermal fillers for facial soft-tissue augmentation. *J Cosmet Laser Ther.* 2009;11(4):240-247.
11. Lemperle G, Morhenn V, Charrier U. Human Histology and Persistence of Various Injectable Filler Substances for Soft Tissue Augmentation. *Aesthetic Plast Surg.* 2020;44(4):1348-1360.
12. Yang F, Zhou Z, Guo M, Zhou Z. The study of skin hydration, anti-wrinkles function improvement of anti-aging cream with alpha-ketoglutarate. *J Cosmet Dermatol.* 2021;10.1111/jocd.14635.
13. Wanitphakdeedecha R, Iamphonrat T, Phothong W, Eimpunth S, Manuskiatti W. Local and systemic effects of low-level light therapy with light-emitting diodes to improve erythema after fractional ablative skin resurfacing: a controlled study. *Lasers Med Sci.* 2019;34(2):343-351.
14. Yang G, Xiang LF, Gold MH. 5-Aminolevulinic Acid-based Photodynamic Intense Pulsed Light Therapy Shows Better Effects in the Treatment of Skin Photoaging in Asian Skin: A Prospective, Single-blinded, Controlled Trial. *J Clin Aesthet Dermatol.* 2010;3(3):40-43.
15. Skin laser medical cosmetology group of Dermatology and Venereology branch of Chinese Medical Association, laser sub-committee of cosmetology and plastic surgeons branch of Chinese Medical Association. Expert consensus on electronic injection (water light therapy). *Qiong Journal of practical dermatology.* 2018;11 (2).
16. Chun J, Bao F, Pei L, Sun L. Application status, efficacy and Prospect of aesthetic formula in the field of skin rejuvenation. *Chinese cosmetic medicine.* 2018;27(10):21-25.
17. Trandel MA, Johanningsmeier S, Schultheis J, Gunter C, Perkins-Veazie P. Cell Wall Polysaccharide Composition of Grafted 'Liberty' Watermelon with Reduced Incidence of Hollow Heart Defect. *Front Plant Sci.* 2021;12:623723.
18. Wang X, Zhao B, Pan B. Application research and Prospect of glucan as a new medical dressing. *China tissue engineering research.* 2017;21(26):4252-4257.
19. Kleinveld DJB, Simons DDG, Dekimpe C, et al. Plasma and rADAMTS13 reduce trauma-induced organ failure by restoring the ADAMTS13-VWF axis. *Blood Adv.* 2021;5(17):3478-3491.
20. Darras A, Peikert K, Rabe A, et al. Acanthocyte Sedimentation Rate as a Diagnostic Biomarker for Neuroacanthocytosis Syndromes: Experimental Evidence and Physical Justification. *Cells.* 2021;10(4):788.
21. Shin SJ, Her Y, Yu DS, Kim CW, Kim SS. Twenty-four-week multicenter, evaluator-blinded clinical study of the efficacy and safety of a dextran filler in the treatment of nasolabial folds. *Dermatol Surg.* 2014;40(6):652-657.