

Cryotherapy Unmasks Umbilication in Molluscum Contagiosum

Camilo Arias-Rodriguez¹, Julia Nowowiejska², Giuseppe Argenziano³, Vincenzo Piccolo³

¹ Department of Dermatology, Universidad Pontificia Bolivariana, Medellín, Colombia

² Department of Dermatology and Venereology, Medical University of Białystok, Białystok, Poland

³ Dermatology Unit, University of Campania, Naples, Italy

Citation: Arias-Rodriguez C, Nowowiejska J, Argenziano G, Piccolo V. Cryotherapy Unmasks Umbilication in Molluscum Contagiosum. *Dermatol Pract Concept*. 2023;13(2):e2023106. DOI: <https://doi.org/10.5826/dpc.1302a106>

Accepted: September 17, 2022; **Published:** April 2023

Copyright: ©2023 Arias-Rodriguez et al. This is an open-access article distributed under the terms of the Creative Commons Attribution-NonCommercial License (BY-NC-4.0), <https://creativecommons.org/licenses/by-nc/4.0/>, which permits unrestricted noncommercial use, distribution, and reproduction in any medium, provided the original authors and source are credited.

Funding: None.

Competing Interests: None.

Authorship: All authors have contributed significantly to this publication.

Corresponding Author: Julia Nowowiejska, MD, PhD, Department of Dermatology and Venereology, Medical University of Białystok, Poland. Tel: +48857409572 E-mail: julia.nowowiejska@umb.edu.pl

Case Presentation

Molluscum contagiosum (MC) is a viral skin disease caused by the Molluscum contagiosum virus [1]. The virus is characterized by high infectious potential and may be transmitted via direct contact, using fomites, or due to auto-inoculation [1]. Clinically, MC usually manifests as multiple pearl-whitish shiny papules with the umbilicated center, although solitary lesions may be observed [1]. On dermoscopy, typical features can be seen, mainly a central white-yellowish amorphous areas, surrounded by blurry crowned vessels on the periphery [2]. Solitary lesions represent a clinical challenge, especially in cases where umbilication is not evident (Figure 1A), and in cases with confusing dermoscopic

findings. What else can aid diagnosis in these cases, apart from histopathological examination?

Teaching Point

Cryotherapy is a practical and cost-effective solution to this problem. After administration of a short cycle of liquid nitrogen to a lesion with an inconspicuous umbilicated center, the concavity appears instantly, confirming the diagnosis of molluscum contagiosum (Figure 1B). Cryotherapy is widely available in every dermatology department, moreover, it is a non-invasive technique and it does not require much time to perform or to recover after the procedure. Hence, in doubtful monolesional non-umbilicated cases, it improves the diagnostic efficacy.

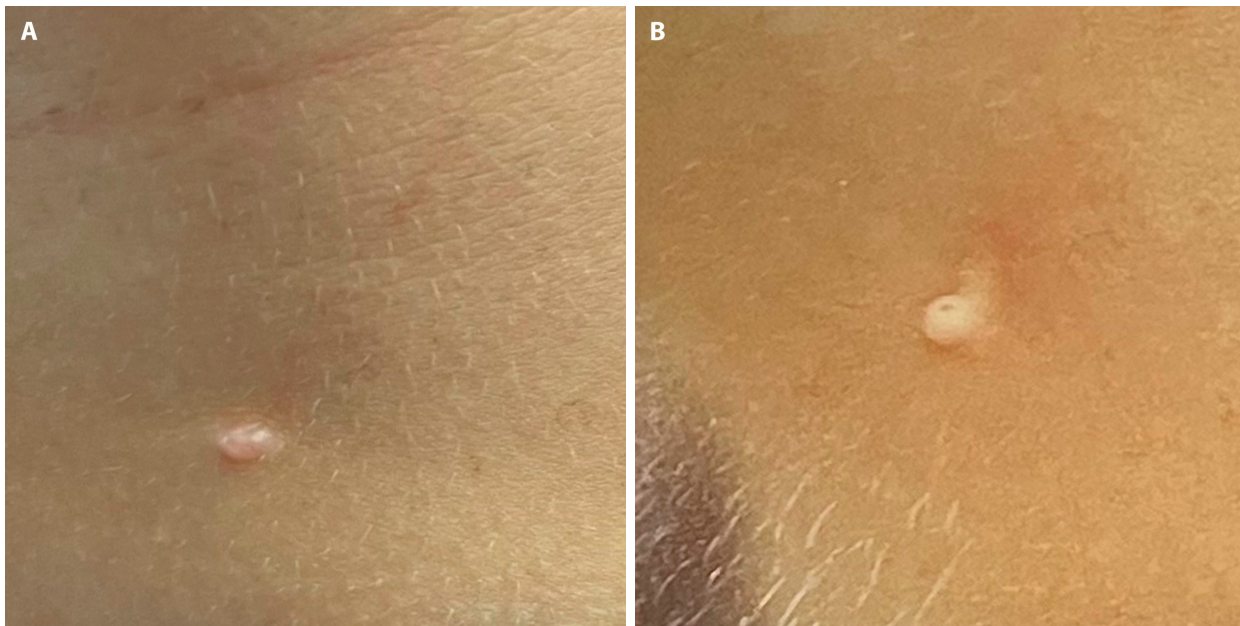


Figure 1. Molluscum contagiosum. (A) A solitary, non-umbilicated lesion before administration of treatment. (B) On the right: umbilicated center appears after administration of cryotherapy.

References

1. Meza-Romero R, Navarrete-Dechent C, Downey C. Molluscum contagiosum: an update and review of new perspectives in etiology, diagnosis, and treatment. *Clin Cosmet Investig Dermatol.* 2019;12:373–381. DOI: 10.2147/CCID.S187224. PMID: 31239742. PMCID: PMC6553952.
2. Piccolo V. Update on Dermoscopy and Infectious Skin Diseases. *Dermatol Pract Concept.* 2019;10:e2020003. DOI: 10.5826/dpc.1001a03. PMID: 31921490 PMCID: PMC6936624.