

Dermoscopic findings in a collision tumor composed of a dermatofibroma and a melanocytic nevus mimicking melanoma

Carolina Marcucci¹, Emilia Cohen Sabban², Paula Friedman¹, Rosario Peralta¹,
Ricardo Sánchez Marull³, Horacio Cabo²

1 Dermatology, Buenos Aires, Argentina

2 Dermatology Section, Instituto de Investigaciones Médicas "A. Lanari", University of Buenos Aires, Argentina

3 Dermatopathology, Buenos Aires, Argentina

Key words: dermoscopy, collision tumor

Citation: Marcucci C, Cohen Sabban E, Friedman P, Peralta R, Sánchez Marull R, Cabo H. Dermoscopic findings in a collision tumor composed of a dermatofibroma and a melanocytic nevus mimicking melanoma. *Dermatol Pract Concept* 2015;5(4):12. doi: 10.5826/dpc.0504a12

Received: April 15, 2015; **Accepted:** July 13, 2015; **Published:** October 31, 2015

Copyright: ©2015 Marcucci et al. This is an open-access article distributed under the terms of the Creative Commons Attribution License, which permits unrestricted use, distribution, and reproduction in any medium, provided the original author and source are credited.

Funding: None.

Competing interests: The authors have no conflicts of interest to disclose.

All authors have contributed significantly to this publication.

Corresponding author: Carolina Marcucci, MD, 72 Ambrosetti St., Buenos Aires, Argentina. Tel. 0541149021487. Email: caromarcucci@hotmail.com

ABSTRACT Collision tumors consist of two different neoplasms occurring concurrently in the same lesion. This association has been described for both benign and malignant neoplasms that may be difficult to identify. Therefore, dermoscopy is a valuable tool to make a correct diagnosis. We report a very unusual collision tumor composed of both a dermatofibroma and a melanocytic nevus mimicking melanoma.

Case report

A 57-year-old man with a history of melanoma, two basal cell carcinomas (BCC) and several dysplastic nevi presented for a routine skin check. The patient had an asymptomatic pigmented lesion on the left side of his back that he had not noticed before (Figure 1), measuring 0.6 cm in diameter with a flat and smooth surface, irregular borders and different colors. The suspected clinical diagnosis was melanoma and a dysplastic nevus.

Under dermoscopic examination (Figure 2) we could identify three different parts in the lesion. On the left side, there was an atypical pigment network and some globules. In the central area, we found an intensification of the pigment network, which looked darker brown. On the right side of

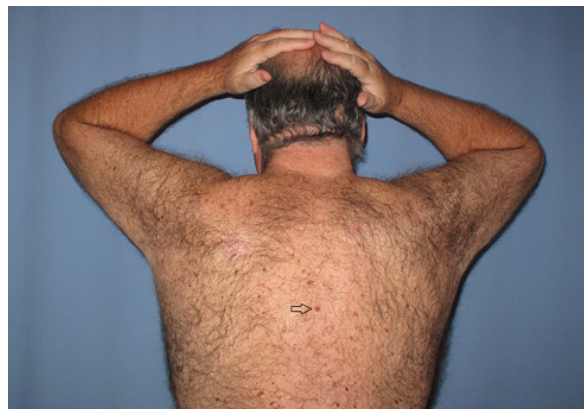

Figure 1. Pigmented 0.6 cm diameter lesion, with irregular borders and different colors, located in the back of a 57-year-old male patient. [Copyright: ©2015 Marcucci et al.]

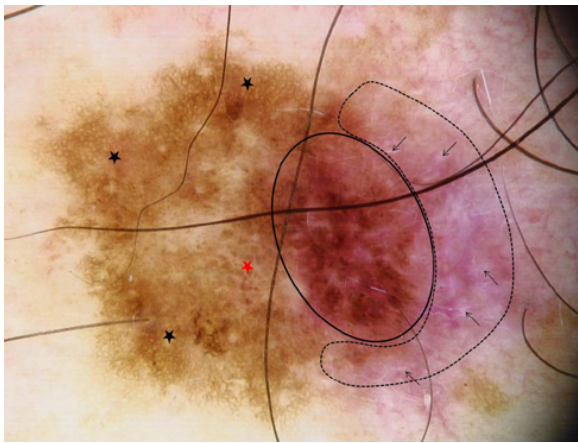


Figure 2. Dermoscopic examination of the lesion showing the following features: an atypical pigment network (black stars), globules (red star), darker brown atypical pigmented network (black line area), and white shiny structures (black arrow) in a pink background (dotted line area). Original magnification x 10. [Copyright: ©2015 Marcucci et al.]

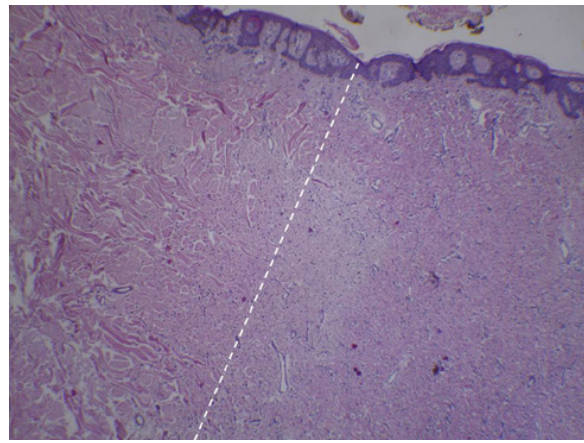


Figure 3. Melanocytic nevus with mild dysplasia (left side of the lesion) and fusocellular proliferation (right side of the lesion). Hematoxylin & eosin X 4. [Copyright: ©2015 Marcucci et al.]

the lesion, we found a pink-colored area with multiple white shiny structures.

Considering that this was a suspicious lesion in a high-risk patient, the lesion was excised and histopathology confirmed the presence of two different contiguous neoplasms: a melanocytic nevus with mild dysplasia (left side of the lesion) and fusocellular proliferation (right side of the lesion) (Figure 3). The immunohistochemical stains were negative for HMB 45, Melan A and smooth muscle actin (Figure 4). A diagnosis of dermatofibroma (DF) was made.

Comments

The coexistence of two different neoplasms in the same biopsy specimen is defined as a collision tumor. This entity has been widely reported in the literature, and a BCC and an SK (seborrheic keratosis) [1,2] is the most common combination. In general, the association between the two lesions is fortuitous, although some of them may involve related cell types [3].

The clinical diagnosis of a collision tumor is extremely difficult to make. In these cases, dermoscopy becomes a necessary and useful tool to identify different structures and then make a correct diagnosis [4].

Pigment network and globules are two criteria of melanocytic lesions. In the case we presented, we could find these two features both on the left side and the central area of the lesion. We believe that this correlated to the melanocytic part of the lesion (left side) and also to the area where the nevus and the dermatofibroma overlapped.

White shiny structures were also noticed in our patient. These structures can be observed in a large variety of entities, such as in DF, Spitz nevus, melanoma, BCC and scars [5]. In our patient, we could see multiple white shiny structures on a pink

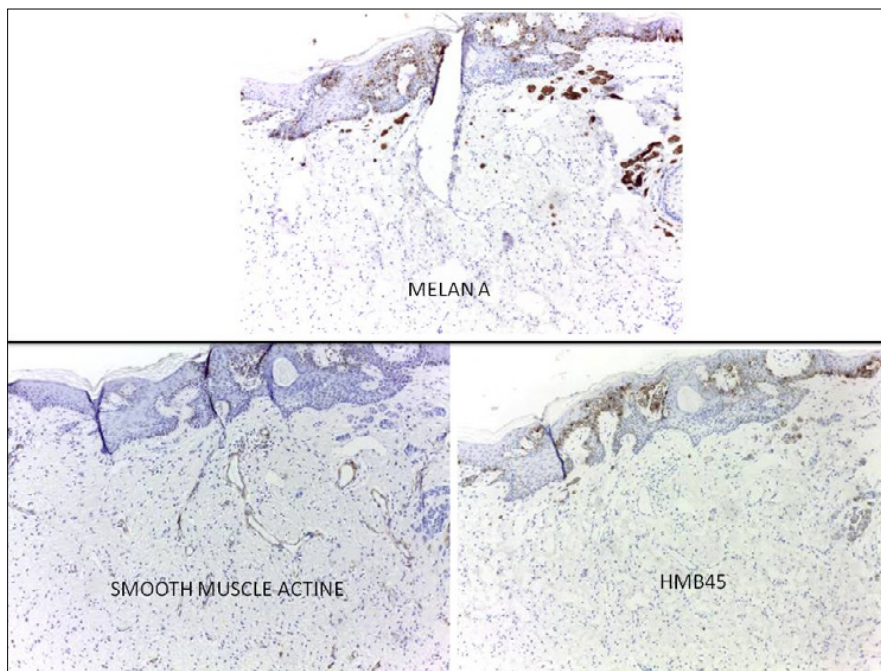


Figure 4. The immunohistochemical stains were negative for HMB 45, Melan A and smooth muscle actin were negative. [Copyright: ©2015 Marcucci et al.]

background on the right side of the lesion, which corresponded to the DF.

Identifying a collision tumor may be challenging for dermatologists. We described a case of a very unusual collision tumor composed of DF and a dysplastic nevus.

As in our experience, the importance of recognizing these cases relies not only on ruling out a melanoma, but also avoiding misdiagnosing a melanoma.

References

1. De Giorgi V, Massi D, Sestini S, et al. Cutaneous collision tumour (melanocytic naevus, basal cell carcinoma, seborrhoeic keratosis): a clinical, dermoscopic and pathological case report. *Br J Dermatol*. 2005;152:787–90.
2. Cabo H, Cohen Sabban E. Combined lesions. In: Cabo H. *Dermatología*, 2nd edition, Buenos Aires; Ediciones Journal, 2012:309-15.
3. Martorell A, Botella-Estrada R, Nagore E, Guillen-Barona C. Dermoscopic features of a collision tumour composed of a pigmented basal cell carcinoma and a melanoma. *J Eur Acad Dermatol Venereol*. 2010;24:974-85.
4. Álvarez-Cuesta C, Vázquez-López F, Pérez-Oliva N. Dermatoscopy in the diagnosis of cutaneous collision tumour. *Clin Exper Dermatol*. 2004;29:196–205.
5. Ferrari A, Argenziano G, Buccini P, et al. Typical and atypical dermoscopic presentations of dermatofibroma. *J Eur Acad Dermatol Venereol*. 2013;27:1375-80.