

Metaphoric and descriptive terminology in dermoscopy: Lessons from the cognitive sciences

Jason Giacomel¹, Iris Zalaudek², Ashfaq A. Marghoob³

¹ Skin Spectrum Medical Services, Como, Western Australia, Australia

² Department of Dermatology, Medical University of Graz, Graz, Austria

³ Memorial Sloan Kettering Cancer Center, Hauppauge, NY, USA

Citation: Giacomel J, Zalaudek I, Marghoob AA. Metaphoric and descriptive terminology in dermoscopy: Lessons from the cognitive sciences. *Dermatol Pract Concept* 2015;5(2):11. doi: 10.5826/dpc.0502a11

Copyright: ©2015 Giacomel et al. This is an open-access article distributed under the terms of the Creative Commons Attribution License, which permits unrestricted use, distribution, and reproduction in any medium, provided the original author and source are credited.

Corresponding author: Jason Giacomel, MBBS, PO Box 270, South Perth, WA, 6951, Australia. Tel. +61 8 9450 2113; Fax. +61 8 9450 2116. Email: jasongiacomel@gmail.com

Summary

- Metaphoric or analogical terminology is common in clinical dermatology, dermoscopy and dermatopathology.
- Metaphoric language in dermatology has been criticized for a perceived lack of clear definition and specificity, and non-metaphoric (descriptive) terms and diagnostic algorithms have attempted to be constructed.
- Metaphors are pervasive in human language and appear to be deeply rooted in our conceptual frameworks.
- The utility of metaphors in dermoscopy is discussed, with particular reference to research in the cognitive sciences.

Introduction: Metaphoric language in dermatology, dermoscopy and dermatopathology

Metaphor is a complex subject in language and cognitive science. It is a linguistic and conceptual tool commonly used in science and the arts and has been defined as “understanding and experiencing one kind of thing in terms of another” [1]. Metaphors are a special form of analogy or association, and aim to help the learner comprehend and communicate new or unfamiliar (“target”) information based on known or familiar (“source”) knowledge.

Lakoff and Johnson propose that our abstract thoughts are largely metaphoric, and that metaphoric language is

secondary to this [1]. In their view “metaphoric thought is unavoidable, ubiquitous, and mostly unconscious,” having developed automatically in childhood as we learn to function in our everyday world [1]. Consequently, they regard metaphor as a natural and unavoidable aspect of human language.

Metaphors are widely used in the dermatology lexicon, developed to aid recognition and description of clinical, dermoscopic, and dermatopathologic criteria. Examples include the prefix “lichen” in lichen planus, “bamboo” hair, “guttate” psoriasis, “arborizing” telangiectasias, “saw tooth” pattern, and so on. Besides explicit metaphoric terminology, covert metaphoric concepts are also common. The “disease as an enemy” metaphor is one example, wherein the dermatologist uses various diagnostic or therapeutic “armamentaria” to “fight” or “combat” the disorder [2].

However, metaphors have received criticism in the dermatologic literature in recent years. Notably, Ackerman says [3]: “. . . clichés are ubiquitous in dermatology and pathology in general and in dermatopathology in particular, the realm of inflammatory skin diseases being no exception. . . . Images like ‘corps ronds and grains’ . . . , ‘dilapidated brick wall’ . . . , ‘tombstone pattern’ . . . , ‘festooning’ . . . , ‘flame figures’ . . . , ‘ground-glass cytoplasm’ . . . , and ‘saw tooth pattern’ . . . may be picturesque, but none of them lend themselves to definition meaningfully by those who mouth them . . . Moreover, not a single one of those whimsical mental pictures has specificity.”

[3] In sum, Ackerman regards these metaphors as lacking clear definition and specificity.

Similarly, Kittler criticizes metaphors in traditional dermoscopy [4]: “The images invoked by metaphoric terms and opaque expressions result inevitably in failure to conjure the very same construct in the brain of any two individuals. Examples: ‘Leaf-like areas,’ ‘fingerprint-like structures,’ ‘fat fingers,’ ‘radial streaming,’ ‘moth-eaten border,’ ‘blue gray veil,’ and ‘honeycomb-like pattern.’ Those images impede repeatable diagnosis by dermatoscopy and prevent rational communication between dermatoscopists.”

Moreover, Alendar et al [5] write, under the heading “No need for metaphoric language,” that “The current language of dermatoscopy consists mainly of metaphoric terms that are badly defined. This language is extremely confusing and discourages students to learn the technique profoundly.”

The above viewpoints present metaphors as being non-scientific, lacking clear definition and specificity. Metaphor is thus regarded as a hindrance to understanding and communication in dermatology, dermatopathology and dermoscopy.

Descriptive terminology in dermoscopy

Following on from their criticism of metaphoric language in dermoscopy, Kittler and colleagues have set about constructing a new dermoscopic vocabulary based on descriptive (analytic) language only, exempt from metaphors [4,6]. Pigmented structures are described as “lines,” “pseudopods,” “circles,” “clods,” and “dots.” Vessel morphologies are broadly described as “dots,” “clods,” and “linear” vessels, with the latter subdivided into “straight,” “looped,” “curved,” “serpentine,” “helical,” and “coiled” type vessels (Table 1).

However, some of these terms are actually metaphoric. For example, “clod” is a metaphor, meaning “a lump of earth or clay” [7]. Hence, the traditional dermoscopic metaphor (ovoid nest or lacunae/sacculae) has been exchanged for a new metaphor (blue/gray or red clods). “Pseudopod” is also used, which is employed also in traditional dermoscopy and is metaphoric, meaning ‘false foot’ (in Greek).

Similarly, “branched serpentine” vessels describe “arborizing telangiectasias” [6] (Table 1). However, “branched” is fundamentally a metaphor, meaning a natural subdivision of a plant stem or tree trunk [7]. “Serpentine” vessel is used as an alternative to the traditional descriptor “linear irregular.” However, “serpentine” is metaphoric, meaning to resemble the shape of a serpent or snake [7]. Paradoxically, the traditional term in this case (“linear irregular”) is essentially descriptive rather than metaphoric.

Although the descriptive terminologies mentioned above have been well defined by Kittler and colleagues [4,6], their specificities have yet to be thoroughly assessed. Conversely,

several metaphoric terms used in traditional dermoscopic nomenclature have been defined clearly and have high specificity [8,9]; for example, “spoke-wheel” pigmentation in pigmented basal cell carcinoma (BCC) [8] (Table 1).

Descriptive terminology is perhaps most useful when it is brief and describes simple dermoscopic features (such as a line, circle or dot), but becomes difficult when dealing with complex criteria (i.e., composed of multiple basic elements); for example, “spoke-wheel” pigmentation, or the “strawberry” pattern of facial actinic keratoses [10] (Table 1). Metaphors may be able to express succinctly not only basic morphologic elements of a dermoscopic feature or features, but also information relating to an often complex combination or arrangement of these features (e.g., the “strawberry” pattern of erythema surrounding hyperkeratotic follicles).

Lengthy descriptive text is typically harder to visualize and is less memorable than a striking and suitable metaphor, which can usually be expressed in one or few words and is frequently visual in nature (e.g., “spoke-wheel” pigmentation). However, descriptive terminology might still be useful in defining or explaining such a metaphor.

Schematic illustration





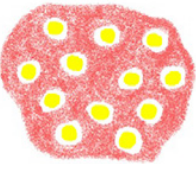


Clinical dermatology and dermoscopy are highly visual disciplines. We can infer, therefore, that the use of illustration would be an effective strategy for teaching and communicating features of skin disease.

Schematic illustration is well known in psychology for facilitating effective learning and communication of technical or scientific concepts. Levin and Mayer [11] and Carney and Levin [12] discuss and attempt to explain this by postulating that pictures make text more:

- i. **Concentrated:** pictures focus the reader’s attention on key points in the text;
- ii. **Compact or concise:** a picture can highlight essential information that may take many sentences of text to explain (i.e., “a picture is worth a thousand words”);
- iii. **Concrete:** allows for easy visualization of text content. Concrete pictures overcome the barrier of literal language to describe complex or abstract concepts;
- iv. **Coherent:** provides a framework or clear structure for the text material. For example, sequential diagrams showing a cause-and-effect process; and
- v. **Comprehensible:** links new, complex, unfamiliar text to a reader’s previous knowledge. That is, aims to help the student understand new, difficult ideas more effectively by connection to past knowledge and experience.

Learning and communication in dermoscopy appears to be assisted significantly by using illustration. However, effective terminology is required to describe or label these pictures.

TABLE 1. Metaphoric and descriptive terminologies listed for various dermoscopic features. Definitions are also provided.

Dermoscopic feature (pictorial)	Metaphoric term	Descriptive (analytic) term*	Definition
	'Comma' vessel	Curved vessel	Broad, curved, slightly unfocused vessels. Stereotypically present in dermal nevi.
	'Hairpin' vessel	Looped vessel	Vascular loops resembling a hairpin in morphology. May also be twisted. Surrounded by a whitish halo when occurring in keratinizing tumors, such as KA and invasive SCC.
	'Glomerular' vessel	Coiled vessel	Tortuous vessels, frequently arranged in clusters and resembling the glomerular apparatus of the kidney. Classically seen in BD.
	'Arborizing' vessel	Branched (serpentine) vessel	Classical arborizing telangiectasias resemble tree branches in morphology. Stem vessels of large diameter branch irregularly into focused, finer capillaries. A hallmark of BCC.
	'Strawberry pattern'	Red structureless pattern interrupted by follicular openings and white circles	Erythema between hyperkeratotic hair follicles (white-yellow circles), resembling the surface of a strawberry. Typical of facial AK.
	'Spoke-wheel' pigmentation	Central (often darker) clod with radial lines	Radial lines, usually tan-colored, meeting at an often darker central (circular to ovoid) axis (i.e., 'hub' of the spoke wheel). Highly specific for pigmented BCC.
	'(Maple) leaf-like' pigmentation	Radial lines connected to a common base	Discrete, brown to gray-blue, bulbous extensions resembling a (maple) leaf. Not connected to a pigment network. Highly specific for pigmented BCC.

*According to Kittler H et al [4,6].

Abbreviations: AK = actinic keratosis; BCC = basal cell carcinoma; BD = Bowen disease (squamous cell carcinoma in situ); KA = keratoacanthoma; SCC = squamous cell carcinoma.

This can be provided by metaphor or descriptive text (or a mixture of both).

Visual metaphors

Visual metaphors (graphic analogies) are a form of pictorial representation and psychological studies have demonstrated that students perform better when text is accompanied by visual metaphors or analogies [13,14]. Performance has been measured by using parameters such as recognition and recall of new knowledge, comprehension and application (i.e., problem solving). Furthermore, visual metaphors can assist students in solving complex or highly technical (scientific) problems [15], and tend to make lessons more interesting and enjoyable for students [14].

Synthesis: Seeking a clear, effective terminology in dermoscopy

Evidence from psychology contradicts the notion that all metaphors (analogical concepts) are ineffective. Contrarily, well-constructed metaphors can assist learning, comprehension, and problem solving in technical subjects.

The idea that metaphors should be avoided in science may reflect the general notion that science should seek objectivity, and that “metaphor and other kinds of poetic, fanciful, rhetorical, or figurative language can always be avoided in speaking objectively, and they should be avoided, since their meanings are not clear and precise and do not fit reality in any obvious way.” [1] This is indeed the prevalent idea in the West and may in part be traced back to ancient and enormously influential thinkers like Plato, who would banish poetry (and poets) from his utopian Republic [16].

However, not all ancient philosophers were opposed to metaphor. Aristotle believed that “It is a great thing, indeed, to make proper use of the poetic forms, . . . But the greatest thing by far is to be a master of metaphor” [1,17]; and “ordinary words convey only what we know already; it is from metaphor that we can best get hold of something fresh” [1, 18]. This function of metaphor as a tool of learning or understanding (with new “target” information built on old “source” knowledge) was one of the fundamental purposes of metaphor mentioned in the Introduction.

Rather than rational, empirical, unemotive science being an antithesis to the subjective, emotive, imaginative arts, these two fields might alternatively be seen to compliment each other. In this way, imagination is intertwined with rationality and scientific creativity, rather than being separate to it. As Lakoff and Johnson [1] state: “. . . metaphor unites reason and imagination. Reason, at the very least, involves categorization, entailment, and inference. Imagination, in one of its

many aspects, involves seeing one kind of thing in terms of another kind of thing—what we have called metaphorical thought. Metaphor is thus *imaginative rationality*.”

We already see evidence of *experientialism* in dermatology by the way art can compliment science through the close personal study of visual artwork (painting). Such experience can improve student’s recognition and description of essential visual features in dermatologic conditions [19,20,21]. Furthermore, the paintings are basically being used as metaphors for patients, with Braverman referring to the paintings as “patient surrogates” [21]. That is, the process of developing visual analytical skills might be considered in a broad sense to be an example of analogical (metaphoric) learning: with the appreciation of the visual details (clues) in the narrative paintings and their possible interpretations being used as a “source” metaphor to extrapolate to a more precise description, diagnosis and interpretation of “target” dermatological features in patients. It is also an example of *experiential* learning which aims to heighten observational and diagnostic skills (and hence optimized management decisions) in the student, rather than to rely on less effective methods such as mere memorization or rote learning.

Apt metaphoric concepts and language could therefore have a place in dermatology and dermoscopy. However, to be effective in diagnosis and communication the metaphoric term should be well constructed and used appropriately. We propose that the following four parameters should be considered; that is, the metaphor should be:

- (1) **Well defined and clearly pictured.** There should be adequate text to clearly explain the (prototypical) metaphor. Descriptive terminology may be useful in describing the metaphor.
- (2) **Useful.** The metaphor should help the student understand a new concept that has a degree of difficulty or complexity (e.g., “strawberry” appearance of facial actinic keratosis). If the new information is relatively simple and nontechnical a metaphor may not be required—a brief descriptive, “Kittlerian” type term (e.g., “line,” “circle”) may be more effective. Furthermore, if an effective descriptor already exists for a given feature then introducing subsequent, less effective metaphors should be avoided.
- (3) **Fairly straightforward and commonplace** (i.e., easily and quickly recognized, and easily remembered). The metaphor should be seen commonly in the everyday life of the target audience; and
- (4) **Similar in appearance to the dermatologic or dermoscopic feature it is describing.** The metaphor (“source”) should resemble the feature (“target”) in form or structure and preferably also in color. Too little or too much (visual) detail should be avoided. Differences between the metaphor and the dermoscopic feature should be appreciated, in order to avoid over-generalization of the meta-

phor. A metaphor may be particularly useful in describing a feature that has a high specificity (e.g., “spoke wheel” and “leaf-like” pigmentation in pigmented BCC), however it may still have utility if it evokes a relatively short list of differential diagnoses.

As Williams notes in the cognitive science field [22]: “Visual metaphors must be constructed carefully in order to be effective instructional strategies. The metaphor must be familiar to the target learner. It must come from everyday experiences and be appropriate for the developmental/educational level of the learner. The metaphor designer must create visuals with an appropriate degree of accuracy and detail.

Too much detail and the learner may not be able to interpret the metaphor; too little detail and the learner may not be able to find enough analogies to use the metaphor. A very accurate metaphor may contain so much detail that the learner is overwhelmed and abandons the attempt to interpret it at all. Finally, the judicious use of text along with the visual metaphor may assist in the interpretation.”

If care is taken to clearly construct, define and illustrate a metaphor then interobserver variability or confusion in interpretation of the dermoscopic feature may be potentially minimized. Effectively constructed metaphors would defray many of the general criticisms of metaphor made by Ackerman, Kittler and Alendar in the Introduction.

Dermoscopic metaphors which appear to satisfy the above parameters include (see Table 1):

- (1) “Arborizing” telangiectasias: the morphology of these vessels closely resemble tree branches, and are highly specific for BCC [8];
- (2) “Spoke-wheel” pigmentation: the form and also color of the “source” metaphor can closely resemble the dermoscopic feature it is symbolizing, and has a high specificity (reported as 100%) for pigmented BCC [8];
- (3) “Strawberry” pattern: a concise, compact description of the complex arrangement of dermoscopic features seen in facial actinic keratoses [10]. An accurate representation of structure and colors. The high sensitivity and specificity of this feature has recently been reported [23].

An effective metaphor allows a dermoscopic feature to be quickly visualized and easily remembered. Complex descriptive language is avoided, which may confuse the student and not be readily committed to memory. However, if a metaphor does not fulfill the above-mentioned four parameters it may be ineffective and obstruct learning. Furthermore, these opaque metaphors may also lack high specificity. In our view, examples of less effective dermoscopic metaphors include:

- (1) “Chrysalis” or “crystalline” structures [24, 25]: These are relatively complicated metaphors that do not closely resemble the corresponding dermoscopic feature. Instead, simple descriptive language may be effective, namely

“shiny white streaks/lines” [25, 26, 27]. These metaphors also appear to lack specificity, being so far described in malignant as well as benign conditions such as BCC, melanoma, dermatofibroma and Spitz nevi [24-27].

- (2) “Clods”: A clod of earth may have various sizes and shapes, and colors. The metaphor appears therefore to be somewhat vague (not readily visualized) and appears to lack high specificity; for example, “red clods” may describe both “red lacuna” (seen in hemangioma) and “blood spots” (a feature that may be present in tumors such as invasive SCC). “White clods” may refer to keratotic follicles (facial AK), the whitish globules in sebaceous hyperplasia, or the whitish globular structures of balloon cell nevi, to name but a few. The various types of “clods” could be described instead using pre-existing (but perhaps more precisely defined) metaphoric terms, for example “globule,” “ovoid nest,” and “lacunae” [4,6].

Metaphors are enmeshed in our everyday language and appear to be deeply rooted in our conceptual frameworks, influencing (often subconsciously or automatically) the way we think, learn, and act [1]. The difficulty of extricating metaphor from human language in general, and dermoscopy in particular, is mentioned above and highlighted in Kittler’s work [4,6] which aims to create a novel dermoscopic method without metaphoric language, but which paradoxically contains new metaphoric terms (such as “clod” and “serpentine”). As Lakoff and Johnson propose: “You don’t have a choice as to whether to think metaphorically. Because metaphorical maps are part of our brains, we will think and speak metaphorically whether we want to or not. Since the mechanism of metaphor is largely unconscious, we will think and speak metaphorically, whether we know it or not” [1].

With the traditional language of dermoscopy and the newer Kittlerian terminology now co-existing side-by-side, the dermoscopy lexicon has ironically become more difficult to learn and communicate. There are now multiple terms to describe the same dermoscopic feature. These difficulties have been potentiated by a proliferation of various algorithms for diagnosing both pigmented and non-pigmented skin lesions. Ideally, we should have a consistent, clear, effective, and simplified dermoscopy language (with as few algorithms as possible), which is used universally. This will require critical review of terms used in both traditional and Kittlerian systems and an expert consensus reached on the favored term to be used for each feature, whether it be metaphoric or simply descriptive. A project with these objectives is currently being organized by the International Skin Imaging Collaboration [28].

References

1. Lakoff G, Johnson M. *Metaphors We Live By*. 2nd edition. Chicago: The University of Chicago Press, 2003.

2. Lebwohl M. Combining the new biologic agents with our current psoriasis armamentarium. *J Am Acad Dermatol* 2003;49(Suppl):118-24.
3. Ackerman AB, Böer A, Bennis B, Gottlieb GJ. *Histologic Diagnosis Of Inflammatory Skin Diseases: An Algorithmic Method Based On Pattern Analysis*. 3rd edition. New York: Ardor Scribendi Ltd. 2005:367-8.
4. Kittler H. Dermatoscopy: Introduction of a new algorithmic method based on pattern analysis for diagnosis of pigmented skin lesions. *Dermatopathology: Practical & Conceptual* 2007;13(1):3.
5. Alendar F, Kittler H, Heliöpi Kangas H, Alendar T. Clear definitions, simple terminology, no metaphoric terms. *Expert Rev Dermatol* 2008;3:27-29.
6. Kittler H, Riedel E, Rosendahl C, Cameron A. Dermatoscopy of unpigmented lesions of the skin: A new classification of vessel morphology based on pattern analysis. *Dermatopathology: Practical & Conceptual* 2008;14(4):3.
7. Merriam-Webster Dictionary, Online Edition—available at: www.merriam-webster.com/dictionary. Accessed 5th February 2014.
8. Menzies SW, Westerhoff K, Rabinovitz H, et al. The surface microscopy of pigmented basal cell carcinoma. *Arch Dermatol* 2000;136:1012-16.
9. Menzies SW, Crotty KA, McCarthy WH. The morphologic criteria of the pseudopod in surface microscopy. *Arch Dermatol* 1995;131(4):436-40.
10. Zalaudek I, Giacomel J, Argenziano G, et al. Dermoscopy of facial non-pigmented actinic keratosis. *Br J Dermatol* 2006;155(5):951-56.
11. Levin JR, Mayer RE. Understanding illustrations in text. In: Britton B, Woodward A. (eds.). *Learning from Textbooks: Processes and Principles* Hillsdale, NJ: Erlbaum, 1993: 95-134.
12. Carney RN, Levin JR. Pictorial illustrations *still* improve students' learning from text. *Educational Psychology Review* 2002;14(1):5-26.
13. Royer JM, Cable GW. Illustrations, analogies, and facilitative transfer in prose learning. *Journal of Educational Psychology* 1976;68:205-9.
14. Rigney JW and Lutz KA. Effect of graphic analogies on concepts in chemistry on learning and attitude. *Journal of Educational Psychology* 1976;68:305-11.
15. Beveridge M, Parkins E. Visual representation in analogical problem solving. *Memory and Cognition* 1987;15:230-7.
16. Plato. *The Republic (360 BC)*. Translated by Benjamin Jowett. Project Gutenberg online eBook. Available at: <http://www.gutenberg.org/files/150/150.txt>. Accessed 23rd April 2014.
17. Aristotle. *Poetics* (section 1459a). Translated by S. H. Butcher. The Internet Classics Archive. Available at: <http://classics.mit.edu/Aristotle/poetics.html>. Accessed 12th September 2014.
18. Aristotle's *Rhetoric* (section 1410b). Translated by W. Rhys Roberts. Online version available at: <http://rhetoric.eserver.org/aristotle/rhet3-10.html>. Accessed 12th September, 2014.
19. Dolev JC, Friedlaender LK, Braverman IM. Use of fine art to enhance visual diagnostic skills. *JAMA* 2001;286(9):1020-1.
20. Naghshineh S, Hafler JP, Miller AR, et al. Formal art observation training improves medical students' visual diagnostic skills. *J Gen Intern Med* 2008;23(7):991-7.
21. Braverman IM. To see or not to see: how visual training can improve observational skills. *Clin Dermatol* 2011;29(3):343-6.
22. Williams VS. Creating Effective Visual Metaphors. www.personal.psu.edu/staff/vl/q/vqw/Portfolio/VislMeta.pdf. Accessed 25th June 2012.
23. Huerta-Brogeras M, Olmos O, Borbujo J, et al. Validation of dermoscopy as a real-time noninvasive diagnostic imaging technique for actinic keratosis. *Arch Dermatol* 2012;148(10):1159-64.
24. Marghoob AA, Cowell L, Kopf AW, Scope A. Observation of chrysalis structures with polarized dermoscopy. *Arch Dermatol* 2009;145(5):618.
25. Liebman TN, Rabinovitz HS, Balagula Y, Jaimes-Lopez N, Marghoob AA. White shiny structures in melanoma and BCC. *Arch Dermatol* 2012;148(1):146.
26. Giacomel J, Zalaudek I. Dermoscopy of superficial basal cell carcinoma. *Dermatol Surg* 2005;31(12):1710-3.
27. Zalaudek I, Ferrara G, Broganelli P, et al. Dermoscopy Patterns of Fibroepithelioma of Pinkus. *Arch Dermatol* 2006;142(10):1318-22.
28. Website. International Society for Digital Imaging of the Skin (ISDIS). <http://www.isdis.net/index.php/projects>. Accessed 3rd October 2014.