

Tinea capitis caused by *Trichophyton tonsurans* presenting as an obscure patchy hair loss due to daily antifungal shampoo use

Alita Sombatmaithai¹, Penvadee Pattanaprichakul¹, Papapit Tuchinda¹, Theetat Surawan¹, Chanai Muanprasart¹, Lalita Matthapan¹, Sumanas Bunyaratavej¹

¹ Department of Dermatology, Faculty of Medicine Siriraj Hospital, Mahidol University, Bangkok, Thailand

Key words: tinea capitis, *Trichophyton tonsurans*, patchy hair loss, alopecia

Citation: Sombatmaithai A, Pattanaprichakul P, Tuchinda P, Surawan T, Muanprasart C, Matthapan L, Bunyaratavej S. Tinea capitis caused by *Trichophyton tonsurans* presenting as an obscure patchy hair loss due to daily antifungal shampoo use. *Dermatol Pract Concept* 2015;5(2):27. doi: 10.5826/dpc.0502a27

Received: January 23, 2015; **Accepted:** March 8, 2015; **Published:** April 30, 2015

Copyright: ©2015 Sombatmaithai et al. This is an open-access article distributed under the terms of the Creative Commons Attribution License, which permits unrestricted use, distribution, and reproduction in any medium, provided the original author and source are credited.

Funding: None.

Competing interests: The authors have no conflicts of interest to disclose.

All authors have contributed significantly to this publication.

Corresponding author: Sumanas Bunyaratavej, MD, Department of Dermatology, Faculty of Medicine Siriraj Hospital, Mahidol University, 2 Wanglang Road, Bangkok Noi, Bangkok 10700, Thailand. Tel. +6624197000; ext 4333; Fax. +6624115031. Email: sumbunyaravej@hotmail.com

ABSTRACT Tinea capitis is unusual and often misdiagnosed in healthy adults. We report a case of a healthy woman with a several-year history of asymptomatic, bizarre-shaped, non-scarring alopecia. She had used over-the-counter ketoconazole shampoo regularly for a long time. An initial potassium hydroxide preparation showed negative result for fungal organism. The scalp biopsy revealed endothrix infection, and dermoscopic examination demonstrated the comma hair and corkscrew hair signs. The fungal culture showed *Trichophyton tonsurans*. The daily use of antifungal shampoo could be the important factor to conceal clinical and laboratory findings for diagnosis of *T. tonsurans* tinea capitis in our case, which required high clinical suspicion and histopathology and dermoscopic examinations.

Introduction

Tinea capitis is a fungal infection of hair and scalp that typically occurs in childhood and equally in both sexes that has recently increased in incidence in adults and the elderly [1,2]. It is typically caused by *Trichophyton* and *Microsporum* species. *T. tonsurans* infections may not be symptomatic and mostly infects children; however, it can also cause disease in adults who are close contact with those children [3]. Thus, it

is difficult to diagnose and it requires a high index of suspicion from the examination physician.

Tinea capitis has clinical features ranging from a non-inflammatory scaling to a severe pustular eruption with alopecia, known as kerion. The clinical manifestations of *T. tonsurans* tinea capitis are variable. *T. tonsurans* infection commonly causes “black dot” tinea capitis. *T. tonsurans* performs an endothrix type of hair invasion, which causes hair to

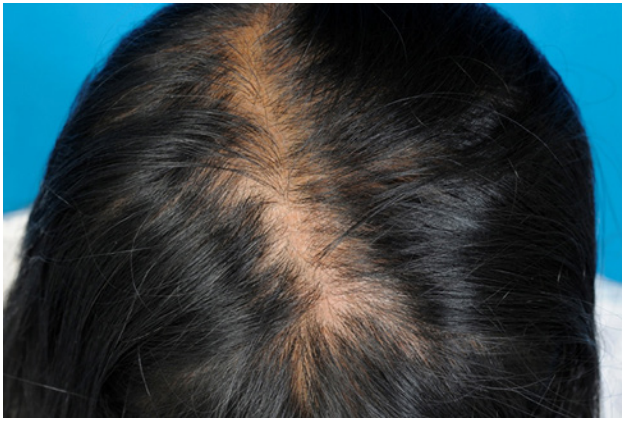

Figure 1. Bizarre-shaped patchy alopecia on vertex scalp. [Copyright: ©2015 Sombatmaithai et al.]

break easily [4]. In addition, it also leads to an inflammatory tinea capitis, which often leads to misdiagnoses.

Case report

A 38-year-old primary school female teacher presented with a history of symptomless, patchy, slow, progressive hair loss for several years. She had been using over-the-counter ketoconazole shampoo regularly for a long time without any improvement. The patient did not have other skin lesions or other underlying diseases. The patient denied history of animal contact or history of pattern hair loss in her family. She had not taken any medications. No other family members had the same lesions. On physical examination, bizarre-shaped patches of hair loss with surrounding hair thinning on the vertex were observed (Figure 1). There was no broken hair shaft, exclamation-point hair or significant scalp inflammation surrounding the area of alopecia. Hair pulling test was negative. Potassium hydroxide (KOH) 10%

examination from hair and scalp was negative, and therefore, fungal culture was not performed. The clinician raised the possible diagnosis of this atypical, non-scarring alopecia as alopecia areata with the differential diagnosis of androgenetic alopecia, chronic telogen effluvium, and trichotillomania. Betamethasone valerate scalp lotion was prescribed to apply twice daily on the affected scalp area but without any clinical improvement. Two 4 mm punch biopsy specimens were taken from the peripheral edge of the alopecia for both vertical and transverse sections to evaluate the cause of non-scarring hair loss in this patient.

The histopathology of the scalp biopsy specimens demonstrated an adequate number of terminal hair follicles without evidence of dermal fibrosis. There was minimal superficial perivascular and perifollicular mononuclear cell infiltrate in some of the follicles without definite peribulbar infiltration. An appropriate ratio of anagen to catagen/telogen hair was appreciated. Numerous fungal hyphae and arthrospores within several hair shafts were demonstrated in both vertical and transverse sections. The epidermis remained intact with orthokeratosis of the keratin and no significant inflammation (Figure 2A and B). KOH examination of lesional hair under dermoscopy showed a positive endothenrix result. Dermoscopic examination revealed broken hair shafts, comma hair sign and a large number of corkscrew hairs (Figure 3A and B). Wood lamp's test revealed a non-fluorescent result. A fungal culture from scalp biopsy and hair demonstrated colonies of *T. tonsurans*. Based on clinical presentation, histopathology and fungal culture, the diagnosis was tinea capitis caused by *T. tonsurans*.

The patient was treated with griseofulvin 500 mg twice daily in combination with ketoconazole shampoo once daily application for eight consecutive weeks. She achieved complete clinical cure. The followup mycological results were negative for both of KOH examination and fungal culture.

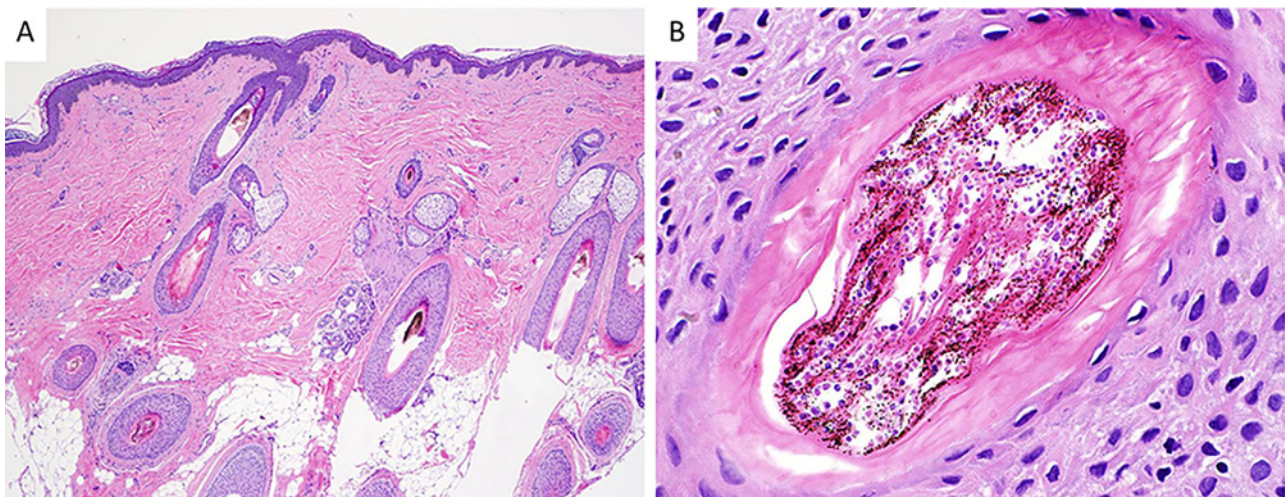


Figure 2. (A) Mild superficial perivascular and perifollicular lymphocytic infiltrate around some hair follicles without definite peribulbar infiltration (H&E x40). (B) Numerous fungal hyphae and arthrospores inside hair shaft (H&E x400). [Copyright: ©2015 Sombatmaithai et al.]

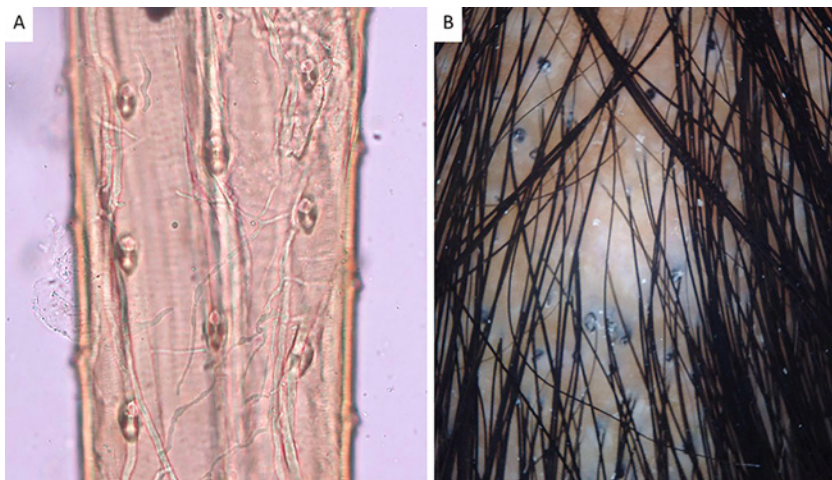


Figure 3. (A) KOH examination of hair shaft presented a positive endothrix result. (B) Dermoscopic examination revealed comma hair sign and large amount of corkscrew hair. [Copyright: ©2015 Sombatmaithai et al.]

Discussion

Tinea capitis is predominantly seen in prepubertal children. This patient was not in a common age group and partially treated with ketoconazole shampoo. Thus, the symptoms could be concealed, resulting in the delay of diagnosis. Generally, the diagnosis of tinea capitis must be confirmed by KOH preparation of infected hairs and a fungal culture. Although scalp biopsy provides high sensitivity, this procedure is invasive and unable to identify the species of pathogen. Therefore, the procedure is not in routine clinical use. Scalp skin biopsy is performed in order to make a differential diagnosis of unidentified alopecia or another alopecia that is recalcitrant to treatment [5]. Due to the obscure clinical presentation of tinea capitis in this patient, the definitive diagnosis was confirmed by biopsy and histopathology. The dermoscope, a non-invasive handheld device, could be useful for diagnosis. The appearance of lesional hair under the dermoscope were comma shape and corkscrew hairs, regardless of dermatophyte species [6,7].

Tinea capitis treatment is mainly oral antifungals, but a topical antifungal shampoo is suggested as an adjuvant therapy [8]. There is a report that successfully used a topical antifungal shampoo as a monotherapy [9]. This patient used antifungal shampoo for several years that prolonged the disease without complete cured. Using of antifungal shampoo probably caused the result to be negative in the first KOH examination. Additionally, this patient had been prescribed topical steroid medication, which caused a positive result in the following KOH examinations. Apart from treatment, physicians should consider disease prevention by screening for close-contact individuals and carriers especially in this particular case: the patient was a primary school teacher, who had contact with children [10].

Conclusion

This case demonstrated the unusual clinical manifestations of *T. tonsurans* tinea capitis. The patient had asymptomatic, dry and scaly patches of alopecia. Physicians could not make a diagnosis due to the unclear clinical features, until histopathologic exam of the hair shaft showed endothrix fungal infection. The patient had been using over-the-counter ketoconazole shampoo regularly for a long period of time, which caused tinea capitis signs and symptoms unclear and a negative result in the first KOH test. Consequently, physicians did not diagnose tinea capitis on this patient at first.

Acknowledgement

We acknowledge Dr. Manasmon Chairatchaneeboon, Division of Dermatopathology, Department of Dermatology, Faculty of Medicine Siriraj Hospital, Mahidol University, for the preparation of histopathological images and description and Dr. Nakaraj Pluetrattanabha for dermoscopic examination and pictures.

References

1. Mohrenschlager M, Bruckbauer H, Seidl HP, Ring J, Hofmann H. Prevalence of asymptomatic carriers and cases of tinea capitis in five to six-year-old preschool children from Augsburg, Germany: results from the MIRIAM study. *Pediatr Infect Dis J* 2005;24(8):749-50.
2. Ginter-Hanselmayer G, Weger W, Ilkit M, Smolle J. Epidemiology of tinea capitis in Europe: current state and changing patterns. *Mycoses* 2007;50:6-13.
3. Hay RJ, Clayton YM, De Silva N, Midgley G, Rossor E. Tinea capitis in south-east London—a new pattern of infection with public health implications. *Br J Dermatol* 1996;135(6):955-8.
4. Stein LL, Adams EG, Holcomb KZ. Inflammatory tinea capitis mimicking dissecting cellulitis in a postpubertal male: a case report and review of the literature. *Mycoses* 2013;56(5): 596-600.
5. Stefanato CM. Histopathology of alopecia: a clinicopathological approach to diagnosis. *Histopathology* 2010;56(1):24-38.
6. Pinheiro AM, Lobato LA, Varella TC. Dermoscopy findings in tinea capitis: case report and literature review. *An Bras Dermatol* 2012;87(2):313-4.
7. Shim WH, Jwa SW, Song M et al. Dermoscopic approach to a small round to oval hairless patch on the scalp. *Ann Dermatol* 2014;26(2):214-20.
8. Bookstaver PB, Watson HJ, Winters SD, Carlson AL, Schulz RM. Prophylactic ketoconazole shampoo for tinea capitis in a high-risk pediatric population. *J Pediatr Pharmacol Ther* 2011;16(3): 199-203.
9. Greer DL. Successful treatment of tinea capitis with 2% ketoconazole shampoo. *Int J Dermatol* 2000;39(4):302-4.
10. Elewski BE. Tinea capitis: a current perspective. *J Am Acad Dermatol* 2000;42:1-20.