

Comment on “‘Tape dermatoscopy’: constructing a low-cost dermatoscope using a mobile phone, immersion fluid and transparent adhesive tape”

Feroze Kaliyadan¹, KT Ashique²

¹ Department of Dermatology, King Faisal University, Hofuf, Saudi Arabia

² KIMS Al Shifa Super Specialty Hospital, Perinthalmanna, Kerala, India

Citation: Kaliyadan F, Ashique KT. Comment on “‘Tape dermatoscopy’: constructing a low-cost dermatoscope using a mobile phone, immersion fluid and transparent adhesive tape.” *Dermatol Pract Concept* 2016;6(1):8. doi: 10.5826/dpc.0601a08

Copyright: ©2016 Kaliyadan et al. This is an open-access article distributed under the terms of the Creative Commons Attribution License, which permits unrestricted use, distribution, and reproduction in any medium, provided the original author and source are credited.

Corresponding author: Feroze Kaliyadan, MD, DNB, MNAM, Department of Dermatology, King Faisal University, Hofuf, Saudi Arabia 31982. Tel. +966544710168. Email: ferozkal@hotmail.com

We read with interest the article published by Blum and Giacometti, describing the low-cost dermatoscope designed using a mobile phone, immersion fluid and transparent adhesive tape. The method described by the authors has the advantage that it does not require any magnifying device [1]. We earlier described a technique where a low-cost jeweler’s loupe can be used as a dermoscopy device [2], and a modification of this where the loupe can be attached to any mobile phone and be used for mobile dermatoscopic imaging [3]. We used a jeweler’s loupe with an inbuilt LED lighting system (Figure 1), and we used alcohol gel as the fluid, which is used to reduce the reflection from the stratum corneum. In our apparatus,

too, the imaging is done from a distance without actual contact with the fluid. The loupe is held at a distance of about 5 cm from the skin after a sufficiently thick layer of alcohol gel is applied over the skin (Figure 2). The technique is not “true” dermoscopy as such, but helps to visualize basic dermoscopic features. Compared to the technique described by Blum and Giacometti [1], we feel that the magnification actually adds to the quality of the image (and here it is true magnification, not



Figure 1. Jeweller’s loupe with inbuilt LED lighting attached to the camera of a Samsung Note 3® mobile phone. [Copyright: ©2016 Kaliyadan et al.]

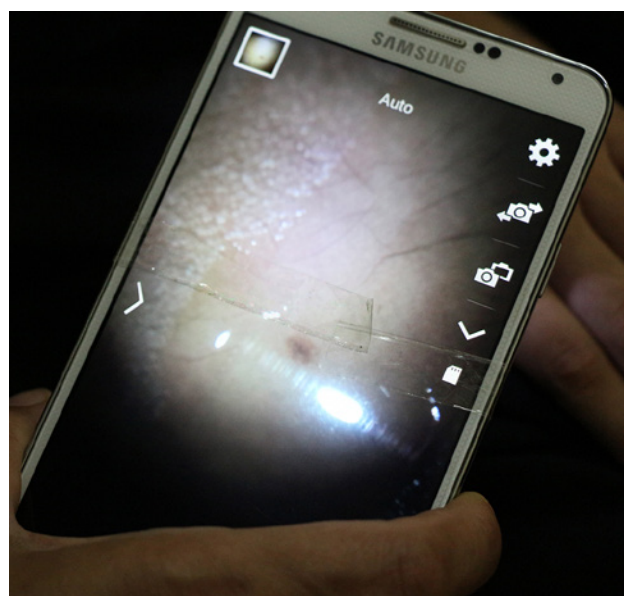


Figure 2. Imaging of the lesion with the mobile phone. [Copyright: ©2016 Kaliyadan et al.]

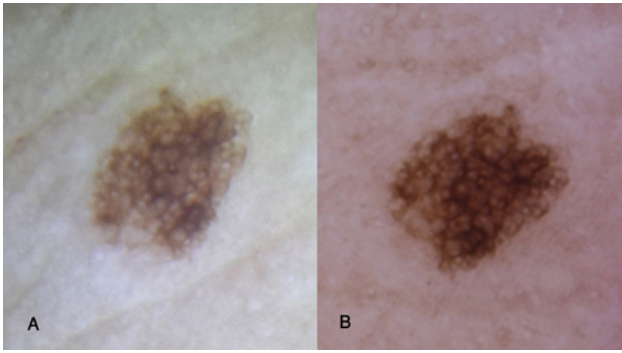


Figure 3. Melanocytic nevus dermoscopy. Contact fluid used was alcohol gel: (A) with a jeweler's loupe attached to a Samsung Galaxy Note 3 mobile phone camera and (B) standard dermoscopy (Derm-Lite Foto II Pro, 3 Gen Inc, San Juan Capistrano, CA). [Copyright: ©2016 Kaliyadan et al.]

digital zoom). The inbuilt lighting also makes it convenient, as we do not need to be dependent on an external light source or ambient lighting. Jeweler's loupes with inbuilt lights are easily available on online shopping platforms; these devices are quite cheap and it is very easy to assemble this apparatus using just simple adhesive tape. However, our method also has the same disadvantages as in the method described by Blum and Giacomel—focusing the camera is not very easy and there are limitations in analyzing finer details, especially vascular patterns (Figure 3). Better quality of lighting and adjusting the angle of the light in a jeweler's loupe might further improve the quality of the imaging.

We would like to emphasize that these low-cost techniques are in no way a substitute for standard dermoscopy.

All the same, these devices can definitely be used as a cost-effective means for understanding the basics of dermoscopy, especially for trainee dermatologists and medical students. There are probably two main factors which limit the regular use of dermoscopy as a diagnostic tool in many developing countries—one is a relatively lower incidence of skin cancers, specifically melanoma, and the other is the cost. Most standard dermoscopes are not easily affordable for medical students or residents. At the same time, dermoscopy is increasingly being used to aid in the diagnosis in general dermatology, especially trichology. Low-cost techniques, like the one described by us, can help in giving an initial hands-on exposure to residents and medical students regarding the basic physics of dermoscopy and also to understand the dermoscopic patterns of normal skin. More studies with a larger sample size are required to validate the actual effectiveness of these low-cost dermatoscopes vis-à-vis standard devices in the context of actual skin pathology. It would obviously not be prudent to use such a method for triaging in the context of conditions like melanoma.

References

1. Blum A, Giacomel J. "Tape dermoscopy": constructing a low-cost dermatoscope using a mobile phone, immersion fluid and transparent adhesive tape *Dermatol Pract Concept*. 2015;5(2):87-93.
2. Kaliyadan F. Using a simple jeweler's loupe as a dermoscopic instrument. *Indian J Dermatol Venereol Leprol*. 2011;77(5):617-20.
3. Kaliyadan F, Ashique KT. A simple and cost-effective device for mobile dermoscopy. *Indian J Dermatol Venereol Leprol*. 2013;79(6):817-9.