

Churg-Strauss syndrome and hemorrhagic vasculitis

Rui Moreira Marques,¹ Ana Rita Cabral,² Antonio Monteiro,¹ Pedro Henriques¹

¹Internal Medicine Department, Hospital São Teotónio-Viseu, ²Department of Dermatology, Coimbra University Hospital, Portugal

Abstract

Churg-Strauss syndrome (CSS) is a rare syndrome characterized by sinusitis, asthma and peripheral eosinophilia. This vasculitic syndrome affects medium and small-sized vessels, the lung being the most commonly affected organ, followed by the skin. The authors report a case of a 59-year-old male with a past history of asthma and allergic rhinitis. He presented necrohemorrhagic lesions in the distal phalanx of the 2nd, 3rd and 4th fingers of the left hand and petechial lesions in the plant of both feet, accompanied by asthenia, anorexia and weight loss. The analytical study revealed leukocytosis with eosinophilia, elevated inflammatory parameters and p-ANCA positive antibodies. The diagnosis of CSS was established based on clinical and histopathological data. Cutaneous manifestations of hemorrhagic vasculitis are rare in CSS syndrome but can be the first manifestation of the disease. The recognition of this presentation is important for the early diagnosis and treatment of this syndrome.

Introduction

Churg-Strauss syndrome (CSS) or allergic granulomatous angiitis is a rare syndrome first described in 1951, characterized by allergic rhinitis, asthma and peripheral eosinophilia.¹ CSS is classified as a vasculitis of medium- and small-sized vessels, affecting mainly the lung, followed by the skin. But this syndrome can affect multiple organs including the cardiovascular, gastrointestinal, renal and central nervous system.

From the three vasculitic syndromes that affect medium- and small-sized vessels, associated with antibodies to neutrophil cytoplasmic antigens (ANCA), CSS is the less frequent. CSS is slightly more common in males and the mean age of diagnosis of this disease is around 38 years. The age of onset varies from 15-70 years with pediatric cases rarely described.

The etiology is unknown, suggesting that the

presence of allergic rhinitis, asthma and positive skin tests may reflect a hypersensitivity reaction mediated by Th2 lymphocytes. On the other hand the presence of pulmonary angiocentric granulomatosis suggests a reaction mediated by Th1 cells.² The importance of the humoral immune response is suggested by hypergammaglobulinemia, mainly immunoglobulin E (IgE), ANCA and positive rheumatoid factor.

There have been reports of CSS after inhaled allergens, vaccination and drugs (leukotriene inhibitors, inhaled glucocorticoids and omalizumab).³⁻⁵

In 40-60% cases antibodies to neutrophil cytoplasmic antigens, perinuclear pattern (p-ANCA) are present which are associated with an increased risk of necrotizing glomerulonephritis, systemic symptoms, diffuse alveolar hemorrhage and multiplex mononeuropathy.⁶⁻⁸

Churg-Strauss syndrome has three distinct stages:^{1,9,10} i) prodromal phase, characterized by allergic symptoms (asthma, allergic rhinitis and sinusitis); ii) eosinophilic infiltrative phase, characterized by peripheral eosinophilia (affecting the lung, myocardium and gastrointestinal tract) and iii) vasculitic phase, characterized by involvement of peripheral nerves, kidney and skin with granulomatous inflammation.

The constitutional symptoms are weight loss, fatigue, fever, arthralgias and myalgias.

Asthma is present in 95% cases of CSS, and precedes the vasculitic phase in about 8-10 years. Physicians should take in to consideration this diagnosis in the presence of persistent asthma, difficult to control with inhaled corticosteroids or patients who often require treatment with systemic steroids.^{11,12} Allergic rhinitis is a common symptom in patients with CSS, but may include nasal obstruction, recurrent sinusitis and nasal polyposis.⁸ Chronic media secretory otitis and sensorineural deafness may occur. Unlike in Wegener granulomatosis, necrotizing lesions of the upper respiratory tract are unusual. Cutaneous manifestations are common (50-66%) in the vasculitic phase, usually like subcutaneous nodules on the extensor surfaces of the arms, hands and legs, but may also emerge as palpable purpura, erythematous maculopapular rash, necrotic bullae, digital ischaemia and hemorrhagic lesions.^{6,10,13,14} The cardiac manifestations are related to heart failure, myocarditis, pericarditis and acute myocardial infarction.^{15,16} The gastrointestinal involvement can lead to eosinophilic gastritis, colitis, abdominal pain, diarrhea and gastrointestinal bleeding. Mononeuritis multiplex is the most common neurological manifestation.¹⁷ The analytical changes are often normocytic normochromic anemia, eosinophilia, elevated erythrocyte sedimentation rate (ESR), elevated C reactive protein (CRP), hypergammaglobulinemia, ele-

Correspondence: Rui Moreira Marques, Medicine I Department, Hospital Sao Teotónio - Viseu, Avenida Rei D. Duarte, 3504-509 Viseu, Portugal. Tel. +351.232.420.500 - Fax: +351.232.420.591. E-mail: ruijm2@gmail.com

Key words: Churg-Strauss syndrome, vasculitis, asthma, eosinophilia, p-ANCA, polyneuropathy.

Funding: no funding sources supported the work.

Conflict of interest: the authors have no conflict of interest.

Contributions: all authors contributed to the acquisition of data, analysis and interpretation of data; elaboration of the article, critical revision and final approval.

Received for publication: 8 August 2011.

Revision received: 15 November 2011.

Accepted for publication: 18 November 2011.

This work is licensed under a Creative Commons Attribution NonCommercial 3.0 License (CC BY-NC 3.0).

©Copyright R.M. Marques et al., 2011
Licensee PAGEPress, Italy
Dermatology Reports 2011; 3:e49
doi:10.4081/dr.2011.e49

vated IgE, positive rheumatoid factor (low titers), p-ANCA positive, increased urea and creatinine values, gross hematuria and proteinuria and erythrocyte cylinders in urine sediment.^{1,7,8} The American College of Rheumatology (ACR) has established six criteria⁹ for the diagnosis of CSS in patients with vasculitis (Table 1). The presence of four of these six criteria has a sensitivity of 85% and specificity of 99.7% for the diagnosis. Another classification, the Lanham's classification^{9,13,14,18} implies the presence of three criteria to make a diagnosis of CSS: asthma, eosinophilia > 1500/ μ L and systemic vasculitis in two or more extrapulmonary sites. In the differential diagnosis clinicians have to consider atopy, parasitic infections, hypereosinophilic syndrome, eosinophilic leukemia, eosinophilic pneumonia and other small-vessel vasculitis. The systemic corticosteroid therapy induces remission in most patients.¹¹ In multisystemic disease a pulse of methylprednisolone 1 g/day in the first 3 days should be followed by prednisolone in the recommended doses.^{12,15-19} An immunosuppressive agent is added to the treatment in cases of advanced disease, refractoriness or relapsed disease.^{12,15-19} Without treatment, the 5-year survival is only 25%, however with proper treatment the survival rate is 90% at 1 year and 62% at 5 years. Most deaths result from complications of the vasculitic phase¹⁹ and result from heart failure, cerebral hemorrhage, renal failure, gas-

trointestinal bleeding and status asthmaticus. Based on this systemic involvement a score was developed taking into consideration five factors of mortality at 5 years:^{11,14,16,19} proteinuria >1 g/24h, serum creatinine >1.58 mg/dL, gastrointestinal tract involvement, cardiomyopathy and central nervous system involvement.

The mortality rate is 12% if there isn't any factor, 26% if there is a gravity factor and 46% if there are three or more factors of gravity.

Therapy with corticosteroids is usually adequate for the treatment of CSS. An immunosuppressive agent is added to the treatment in cases of advanced disease, refractoriness or relapsed disease.^{12,15-19} In patients controlled with lower doses of corticosteroids cyclophosphamide is not indicated for management of the immunosuppressive treatment.^{11,12}

Case Report

The authors report the case of a 59-year-old male with asthenia, anorexia and weight loss (10 kg in three months) with necrohemorrhagic lesions in the distal phalanges of the 2nd, 3rd and 4th fingers of the left-hand (Figure 1). He also presented petechial lesions at the foot plants

(two weeks of evolution) (Figure 2). The lesions did not disappear with pressure. There were no history of fever and involvement of the cardiovascular and gastrointestinal system. He had a previous history of allergic rhinitis and bronchial asthma diagnosed 15 and 7 years earlier, respectively. Laboratory tests showed leukocytosis ($14.5 \times 10^3/\mu\text{L}$); 40.3% of eosinophils ($5.8 \times 10^3/\mu\text{L}$), increased ESR (57 mm), CRP 3.84 mg/dL, IgE 1.5 IU/L, IgG polyclonal hypergammaglobulinemia.

In the immunologic study ANA's, ds-DNA, anti-SM, anti-SS-A, anti-SS-B, anti-RNP, anti-Histone, lupus anticoagulant, viral serology, VDRL, tumor markers, and cryoglobulins were all negative. p-ANCA value was positive 59 U/mL (0-10 U/mL). The skin biopsy of a cutaneous lesion of the hand revealed necrotizing vasculitis with abundant eosinophils (Figure 3). Pulmonary function tests showed a restrictive pattern and bronchoscopy with bronchoalveolar analysis revealed a high percentage of eosinophils (45%). CT scan of the sinuses was normal. The electromyogram revealed a sensorimotor polyneuropathy predominantly at the upper limbs. Bone marrow examination showed eosinophilia and no other abnormalities, bone biopsy revealed eosinophilic granulocytic hyperplasia. The parasitological examination of faeces, the gastrointestinal endoscopy, colonoscopy detected no alter-

ations. Treatment was started with prednisolone 1 mg/Kg/day (70 mg/dia), pregabalin 75 mg 12/12 hours, paracetamol 1 g 8/8 hours and ipratropium bromide and salbutamol (0.52 mg/3 mg) 8/8 hours. The patient had a good clinical and analytical response (eosinophilia, ESR and CRP) with improvement of constitutional symptoms, pain and paresthesias. By the third month of treatment it was added azathioprine 100 mg/day to prednisolone (50 mg/day) maintaining the reduction of steroids by 1 year. The patient showed clinical improvement with gradual improvement of skin lesions until their complete resolution.

Discussion

The CSS is a rare syndrome with a diversity of clinical manifestations, which are highlighted within the respiratory, dermatological, neurological, gastrointestinal, cardiac and musculoskeletal tracts. Cutaneous manifestations are present in 50-66% of cases. The presence of hemorrhagic lesions, like in the case reported are rare and can be the first manifestation of this disease.^{6,10,13,14} The electromyogram changes (that confirmed polyneuropathy), along with demonstration of cutaneous vasculitis with eosinophils on skin biopsy were decisive for the diagnosis of CSS. This patient had five of the six criteria defined by the American College of Rheumatology⁹ and only the migratory or transient opacities were not visible radiologically. The three criteria of Lanham are all present. None of the criteria of poor prognosis was present in our patient. The estimated mortality at 5 years is less than 12%.

Our patient had a rapid analytical response with resolution of the acute phase markers and reduction of peripheral eosinophilia, typical of the immunosuppressive response in CSS. The clinical response was slower, with resolution of the petechiae lesions at month 3 of treatment, with necrohemorrhagic lesions persisting. With the introduction of azathioprine, there was maintained good evolution of the dermatological lesions. Remission was maintained with steroid treatment up to 12 months (5 mg prednisolone/day). In the literature the introduction of azathioprine is recommended in patients requiring high doses of corticosteroids (>15 mg/day) for relatively long time.^{18,20}

The presence of antinuclear antibodies are present in 40-60% of patients with CSS,^{5,7,12} most patients (70-75%) have antibodies against myeloperoxidase (MPO-ANCA or p-ANCA). The presence or absence of p-ANCA seems to be associated with different systemic involvement but further studies are needed.^{9,10} The determination of these antibodies as markers of good outcome are contradictory and

Table 1. Classification of the American College of Rheumatology for Churg-Strauss syndrome.

Criteria of the ACR for CSS
Asthma
Eosinophils > 10%
Mononeuropathy (including multiplex) or polyneuropathy
Migratory pulmonary opacities
Disease of the sinuses

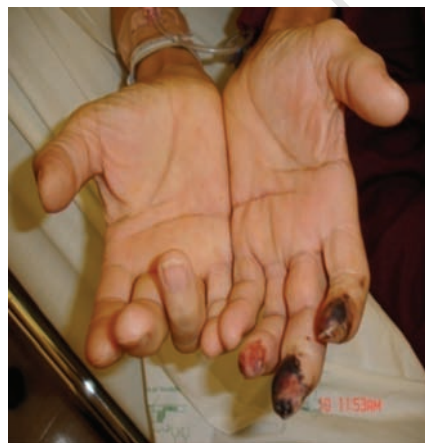

Figure 1. Necrohemorrhagic lesions in the distal phalanx of the 2nd, 3rd and 4th fingers.

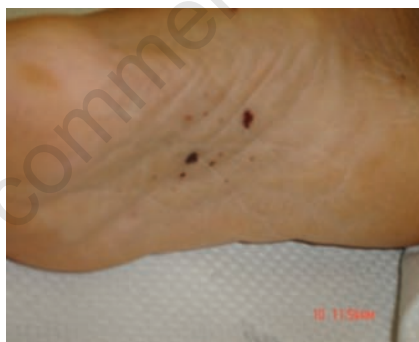

Figure 2. Petechial lesions in the plant of the right foot.

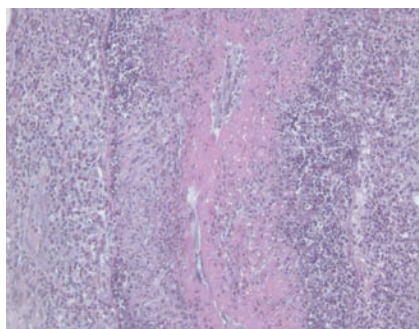


Figure 3. Skin biopsy of a finger lesion, showing necrotizing vasculitis with abundant eosinophils.

not helpful.⁷ The role of leukotriene modifying agents (LTMA) in CSS is uncertain but it is believed that LTMA may unmask this syndrome. This suspicion is regarded because glucocorticoid withdrawal is facilitated by LTMA therapy leading to CSS manifestations. On the other hand, in patients who have undiagnosed but escalating CSS the prescription of LTMA is insufficient to control the CSS and the disease becomes manifest.³ The early diagnosis, aided by the appearance of cutaneous manifestations can alter the prognosis of these patients, by the precocious introduction of specific treatment. The morbidity associated with heart, nervous system, gastrointestinal and renal involvement can also be decreased by this procedure, since the treatment with corticoids is effective preventing the complications of the vasculitic fase and stabilizing the disease.

References

1. Churg J, Strauss L. Allergic granulomatosis, allergic angiitis and periarteritis nodosa. *Am J Pathol* 1951;27:277-301.
2. Hellmich S, Ehlers E, Csernok WL, Gross. Update on the pathogenesis of Churg-Strauss syndrome. *Clin Exp Rheumatol* 2003;21:69-77.
3. Hauser T, Mahr A, Metzler C et al. The leukotriene receptor antagonist montelukast and the risk of Churg-Strauss syndrome: a case-crossover study. *Thorax* 2008;63:677-82.
4. Guillevin L, Lhote F, Gayraud M et al. Prognostic factors in polyarteritis nodosa and Churg-Strauss syndrome. A prospective study in 342 patients. *Medicine (Baltimore)* 1996;75:17-28.
5. Della Rossa A, Baldini C, Tavoni A, et al. Churg-Strauss syndrome: clinical and serological features of 19 patients from a single lian centre. *Rheumatology* (Oxford). 2002;41:12842.
6. Sinico RA, Di Toma L, Maggiore U et al. Prevalence and clinical significance of antineutrophil cytoplasmic antibodies in Churg-Strauss syndrome. *Arthritis Rheum* 2005;52:2926-35.
7. Sablé-Fourtassou R, Cohen P, Mahr A et al. Antineutrophil cytoplasmic antibodies and the Churg-Strauss syndrome. *Ann Intern Med* 2005;143:632-8.
8. Chumbley L, Harrison E, DeRemee R. Allergic granulomatous and angiitis (Churg-Strauss syndrome): report and analysis of 30 cases. *Mayo Clin Proc* 1977; 52:477-84.
9. Masi AT, Hunder GG, Lie JT et al. The American College of Rheumatology 1990 criteria for the classification of Churg-Strauss syndrome (allergic granulomatosis and angiitis). *Arthritis Rheum* 1990;33: 1094-1100.
10. Strauss L, Churg J, Zak F. Cutaneous lesions of allergic granulomatosis: histopathological study. *J Invest Dermatol* 1951; 17:349-59.
11. Guillevin L, Cohen P, Gayraud M, et al. Churg-Strauss syndrome: Clinical study and long-term follow-up of 96 patients. *Medicine (Baltimore)* 1999;78:26-37.
12. Cottin V, Khouatra C, Dubost R, et al. Persistent airflow obstruction in asthma of patients with Churg-Strauss syndrome and long-term follow-up. *Allergy* 2009; 64:589.
13. Schwartz RA, Churg J. Churg-Strauss syndrome. *Br J Dermatol* 1997;52:477-84.
14. Lestre S, Serrão J, Pinheiro S, Lobo L. Síndrome de Churg-Strauss-vasculite cutânea como forma de apresentação Clínica. *Acta Reumatol* 2009;34:281-7.
15. Neumann T, Manger B, Schmid M, et al. Cardiac involvement in Churg-Strauss syndrome: impact of endomyocarditis. *Medicine (Baltimore)* 2009;88:236.
16. Corradi D, Maestri R, Facchetti F. Postpartum Churg-Strauss syndrome with severe cardiac involvement: description of a case and review of the literature. *Clin Rheumatol* 2009;28:739.
17. Kawakami T, Soma Y, Kawasaki K, et al. Initial cutaneous manifestations consistent with mononeuropathy multiplex in Churg-Strauss syndrome. *Arch Dermatol* 2005;141:873-8.
18. Pagnoux C, Guillevin L. Churg-Strauss syndrome: evidence for disease subtypes? *Curr Opin Rheumatol* 2010;22:21.
19. Ribi C, Cohen P, Pagnoux C, et al. French Vasculitis Study Group. Treatment of Churg-Strauss syndrome without poor-prognosis factors: a multicenter, prospective, randomized, open-label study of seventy-two patients. *Arthritis Rheum* 2008;58:586.
20. Lhote F, Cohen P, Guilpain P, Guillevin L. Churg-Strauss syndrome. *Rev Prat* 2008; 58:1165.