

Particular Matter of Motor Vehicle Exposure and High-Fat Diet Effects on Kidney Histopathology, Creatinine, and Malondialdehyde (MDA) Levels in Wistar Rats

Rizka Veni^{1,2*}, Awal Prasetyo³, Muflihatul Muniroh⁴

¹Graduate School of Biomedicine, Faculty of Medicine, University of Diponegoro, Semarang 50275, Indonesia

²Department of Biomedic, Faculty of Medicine, University of Abdurrab, Pekanbaru 28291, Indonesia

³Department of Anatomical Pathology, Faculty of Medicine, University of Diponegoro, Semarang 50275, Indonesia

⁴Department of Physiology, Faculty of Medicine, University of Diponegoro, Semarang 50275, Indonesia

*Corresponding author e-mail: rizkaveni@yahoo.com

Abstract

This study aims to analyze the effect of combination of motor vehicle particular matter exposure and high-fat diet in kidney histopathology, creatinine levels, and MDA levels in Wistar rats. This study used a posttest-only control group design. Eighteen healthy male Wistar rats were divided into three groups. The intervention groups received motor vehicle fume exposure for 100 s with normal diet (X1) or high-fat diet (X2), and the control group received no exposure (C). Data analysis was processed with a SPSS 25.0 computer program by using the one-way ANOVA test followed by post hoc LSD. The degree of kidney histopathological damage showed significant differences between the X1 and X2 groups when compared with the control group ($p < 0.05$). The results of the creatinine level examination found a significant difference between the X2 and C groups ($p < 0.05$) and the treatment groups X1 and X2 ($p < 0.05$). The results of kidney MDA level examination showed a significant difference between the treatment groups (X1 and X2) and the control group ($p < 0.05$). The combination of particular matter of motor vehicle fumes exposure and high-fat diet could induce kidney damage through histopathological change and increased creatinine levels and kidney MDA levels in Wistar rats.

Keywords

Creatinine, High-Fat Diet, Histopathological Damage, Kidney, MDA, Particular Matter

Received: 4 June 2021, Accepted: 21 September 2021

<https://doi.org/10.26554/ijems.2021.5.3.124-128>

1. INTRODUCTION

Ambient air pollution is the biggest environmental health problem in the world, with the greatest toll in the Southeast Asian regions (WHO, 2016). In Indonesia, the number of motor vehicle increases every year. Based on data from the Central Statistics Agency the number of motor vehicles was 85,601,351 in 2011 and increased to 129,281,079 in 2016 (Agency, 2017). Air pollutants caused a strong impact on health, especially particulate matter (PM), ultrafine particles, ozone (O₃), nitrogen dioxide (NO₂), and sulfur dioxide (SO₂). One of the main sources of PM is motor vehicle fume (WHO, 2016). The main components of PM are heavy metals, carbon sources, sulfate, ammonium, nitrate, and various ions (Agency, 2017). PM (PM_{2.5}) has been shown to cause an inflammatory response and increase in free radical levels (Cho et al., 2018). Free radicals cause cell damage, lipid peroxidation, and protein oxidation. The

end result of lipid peroxidation is malondialdehyde (MDA) (Delfino et al., 2011; Birben et al., 2012; Ozbek, 2012).

Obesity is also be a problem in the Southeast Asian regions. The prevalence of obesity ranges from 2% to 10% (WHO, 2016; Hossain et al., 2007). Based on Riskesdas, the number of obese people in Indonesia increases every year. In 2018, the prevalence of obesity in Indonesia was 21.8%, which continued to rise since 2007 and 2013 with prevalence of 10.5% and 14.8%, respectively (Research, 2013). Consumption of a high-fat diet is thought to be the main cause of obesity, which is also known to cause oxidative stress generation (Delfino et al., 2011; Birben et al., 2012; Noeman et al., 2011).

The main human organ influenced by toxic substances is the kidney, especially in the glomerular filtrate and through the tubular cells. The impact of these toxic substances results in oxidative stress, which will affect the structure and function of the kidneys (Ozbek, 2012). A previous study

conducted by [Chen et al. \(2018\)](#) showed a link between lower estimated glomerular filtration rate (eGFR) caused by air pollution, higher prevalence of chronic kidney disease (CKD), and an increased risk of developing CKD in the elderly ([Chen et al., 2018](#)). In china, [Gong et al. \(2013\)](#) also reported increased MDA urine and exhaled breath condensate levels during and after the Beijing Olympics at which time air pollution increased ([Gong et al., 2013](#)).

An experimental study conducted by [Salim et al. \(2018\)](#) showed that a high-fat diet promotes obesity and can cause kidney abnormalities as a result of histopathological changes, including dilation, tubular defects, inflammation, and enlargement of the renal connective tissue ([Salim et al., 2018](#)). In a previous experimental research conducted by [Noeman et al. \(2011\)](#) obese rats being given a high-fat diet showed increased levels of MDA ([Noeman et al., 2011](#)). Research conducted by [Wardoyo et al. \(2017\)](#) on mice exposed to motor vehicle ultrafine smoke particles showed damage to rat organs with the highest severity for the lungs and then kidneys, erythrocytes, and liver ([Wardoyo et al., 2017](#)).

However, there are no in vivo experimental studies that investigate the effects of motor vehicle fumes especially about PM_{2.5} on the kidney organ. This study aims to analyze the effect of the combination of motor vehicle particular matter exposure and high-fat diet in kidney histopathology, creatinine levels, and MDA levels in Wistar rats.

2. EXPERIMENTAL SECTION

2.1 Motor Vehicle Samples

PM_{2.5} describes fine inhalable particles, with diameters that are generally 2.5 μm and smaller. In this research, motor vehicle fumes come from the exhaust of a 125-cc automatic motorbike fueled by pertalite output in 2017. The concentration of the number of smoke particles with a diameter of $\leq 2.5 \mu\text{m}$ was measured using Kanomax Model 3443.

2.2 Motor Vehicle Fumes Exposure

Motor vehicle fumes are exposed by placing the test animals in closed cages that have been given holes for fumes and for ventilation. The motor is started, and then the smoke is collected in the reservoir and connected to the cage with ventilation (Figure 1).

2.3 Experimental Animals

Animal management tries to follow “animal ethics”. This research was submitted to and approved by the Ethics Commission for Medical/Health Research, Faculty of Medicine, Sultan Agung Islamic University, Semarang, with a certificate No. 282/VIII/2020/Bioethics Commission dated August 30, 2020. Eighteen healthy male Wistar rats were used in this study. They were acclimatized for 3 days in a fumigation chamber measuring 77 × 52 × 35 cm with room temperature ranging from 25°C to 28°C and room humidity levels ranging from 70% to 75%. Light reception is set to

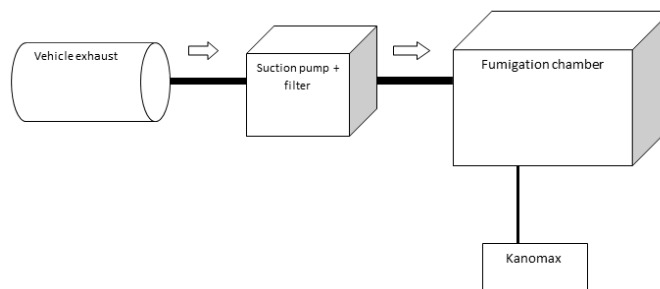


Figure 1. The Smoke Procedure (Modified) ([Wardoyo et al., 2017](#))

12-h bright/dark cycle. After acclimatization, the experimental animals were randomly divided into three groups. The intervention groups received motor vehicle fume exposure for 100 s with normal diet (X1) or high-fat diet (X2), and the control group did not get any exposure (C). Rats were given pellet type AD II, high-fat feed, and reverse osmosis drinking water, which were given ad libitum. On the fourth day, weight measurements were taken. Body weight was weighed using the Mettler Toledo digital scale with an accuracy level of 0.1 g. After a 28-day treatment period, a surgical sampling of kidney tissue was carried out. Previously, the rats were anesthetized by giving a ketamine injection of 60 mg/kgBW (i.m.).

2.4 Histopathological Analysis

The obtained kidney tissue is then fixed with a 10% neutral buffer formalin solution and left at room temperature for 48 h. Furthermore, histological preparations were made, and H&E staining was done according to the procedure. Cell damage is observed, which includes widening of the tubular lumen and necrotic cells. Each of these parameters was graded as follows: 0, no damage; 1, slight (25%); 2, moderate (50%) and marked (75%). The prepared kidney histopathology was observed in eight fields of view under a microscope with a 400× magnification. Observations were made by two observers with the double blind methods.

2.5 Statistical Analysis

All the obtained data were processed with a SPSS 25.0 computer program and analyzed using one-way ANOVA test followed by post hoc LSD. There was a significant difference if $p < 0.05$.

3. RESULTS AND DISCUSSION

3.1 Result

3.1.1 Degree of Kidney Damage

Table 1 presents the results of examining the degree of kidney damage at the end of treatment.

The negative and light degree of kidney damage were only in the C group. The X1 group that received motor vehicle fume exposure for 100 s with normal diet had various

Table 1. The Degree of Kidney Damage Among Treatment Group

Group	Degree of Kidney Damage					Sig	
	Negative	+	++	+++	Total	X1	X2
C	4	2	0	0	6	0.000*	0.000*
X1	0	1	4	1	6		0.056
X2	0	0	2	4	6		

C = the control group did not get any exposure, X1 = the intervention group received motor vehicle fume exposure for 100 s with normal diet, X2 = the intervention group received motor vehicle fume exposure for 100 s with high-fat diet.

Analysis was done using one-way ANOVA test. *significant difference $p < 0.05$.

degrees of kidney damage, that is, one in slight degree, four in moderate degree, and one in marked degree. In the X2 group that received motor vehicle fume exposure for 100 s with high-fat diet, two were in moderate degree, and four were in marked degree of kidney damage (Table 1; Figure 2).

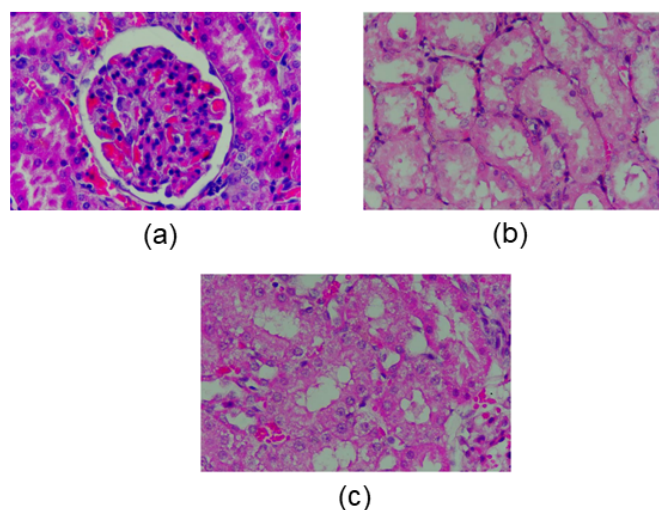


Figure 2. Histopathology Features of Rats' Kidney Tissue in Control Group (a), The X1 Group That Received Motor Vehicle Fume Exposure for 100 s with Normal Diet (b), and The X2 Group That Received Motor Vehicle Fume for 100 s with High-Fat Diet (c). The White Arrows Showed Edema Tubules of The Kidney.

The one-way ANOVA test results showed that there was a significant difference in kidney histopathological damage ($p < 0.05$). Furthermore, the post hoc LSD test was conducted to determine which groups had significant differences.

3.1.2 Creatinine and MDA Levels Results

Table 2 presents the results of checking creatinine and MDA levels at the end of treatment.

As presented in Table 2, the highest creatinine and MDA level was found in the intervention group that received motor vehicle fume exposure for 100 s with high-fat diet

(X2) compared to the control and X1 group. Creatinine and MDA level increased two times in the X2 group compared with the control. Furthermore, one-way ANOVA test results showed that there was a significant difference in the increase in creatinine levels ($p < 0.05$) and MDA levels.

3.2 Discussion

This study showed that kidney histopathological damage showed significant differences between the X1 and X2 groups when compared with the control group ($p < 0.05$). The highest result was found in the X2 group (Table 1). This kidney damage is caused by the pollutants produced by motorized vehicles containing the dangerous substance, namely, particulate matter, which causes oxidative stress. Moreover, the combination of particulate matter exposure with high-fat diet will cause oxidative stress generation, and oxidative stress increases free radical levels. Free radical will cause cell damage in the kidney (Delfino et al., 2011; Birben et al., 2012; Ozbek, 2012; Hanifah, 2008).

The results of this study are in line with the previous study conducted by Wardoyo et al. (2017) in which exposure to ultrafine particles of motor vehicle fumes resulted in damage to the organs of mice with the highest severity for the lungs, followed by kidneys, erythrocytes, and liver (Wardoyo et al., 2017). In addition, research by Salim et al. (2018) showed that high-fat diet triggers obesity and can cause abnormalities in the kidneys as a result of histopathological changes such as dilation, tubular defects, inflammation, and enlargement of the kidney connective tissue (Salim et al., 2018).

A decrease in glomerular filtration rate (GFR) indicates kidney damage by counting the amount of filtrate produced by the glomerulus (Simon et al., 2011; Van Bladel et al., 2012). To estimate the GFR of eLFG based on the formula from The Chronic Kidney Disease Epidemiology Collaboration (eLFGCKD-EPI) (Michels et al., 2010). eLFG CKD-EPI has better accuracy and uses four variables, namely serum creatinine levels, age, sex, and race (WHO, 2016; Ning et al., 2018).

The results of the creatinine level examination showed an increase in creatinine levels after exposure to motor vehicle fumes for 100 s/day for 28 days, and the highest increase in creatinine levels was found on the X2 group

Table 2. Results of The Creatinine and MDA Level Examination

Group	Creatinine Levels			MDA Levels		
	Mean ± SD	X1	Sig X2	Mean ± SD	X1	Sig X2
C	0.3000 ± 0.08944	0.261	0.001*	187.2593 ± 47.81480	0.007*	0.000*
X1	0.3667 ± 0.13663		0.011*	261.7037 ± 42.26703		0.000*
X2	0.5333 ± 0.05164			381.7037 ± 30.87743		

C = the control group did not get any exposure, X1 = the intervention group received motor vehicle fume exposure for 100 s with normal diet, X2 = the intervention group received motor vehicle fume exposure for 100 s with high-fat diet.

Analysis was done using one-way ANOVA test. *significant difference $p < 0.05$.

(Table 2). The results of the creatinine level examination found a significant difference between the X2 and C groups ($p < 0.05$) and the treatment groups X1 and X2 ($p < 0.05$). The increase in serum creatinine levels due to PM_{2.5} exposure is in accordance with the research conducted by Ning et al. (2018) in which exposure to PM_{2.5} directly or indirectly increases levels of creatinine, citric acid, succinic acid, malic acid, and maltose, affecting metabolic changes in the hippocampus area (Ning et al., 2018). Furthermore, the results of kidney MDA level examination showed a significant difference between the treatment groups (X1 and X2) and the control group ($p < 0.05$). Particulate matter contained in motor vehicle fumes and a high-fat diet cause an inflammatory response and the formation of free radicals, resulting in cell damage, lipid peroxidation, and protein oxidation. The end result of lipid peroxidation is malondialdehyde (MDA) (Delfino et al., 2011; Birben et al., 2012; Ozbek, 2012).

The results of this study are in line with the previous experimental research conducted by Noeman et al. (2011) which showed that obesity induced by a high-fat diet is accompanied by an increase in oxidative tissue of the liver, heart, and kidneys, characterized by a reduction in antioxidant enzyme activity and glutathione levels, correlated with increased levels of MDA and protein carbonyl (PCO) in most tissues (Noeman et al., 2011).

4. CONCLUSIONS

From the results of the study, it was found that the combination of particulate matter from motor vehicle fume exposure and high-fat diet could induce kidney damage by histopathological change and increased creatinine levels and kidney MDA levels in Wistar rats.

5. ACKNOWLEDGEMENT

This study was supported by Department of Biomedic, Faculty of Medicine Diponegoro University and Abdurrah University

REFERENCES

- Agency, C. S. (2017). Central Statistic Agency of the Republic Indonesia
- Birben, E., U. M. Sahiner, C. Sackesen, S. Erzurum, and O. Kalayci (2012). Oxidative Stress And Antioxidant Defense. *World Allergy Organization Journal*, **5**(1); 9–19
- Chen, S. Y., D. C. Chu, J. H. Lee, Y. R. Yang, and C. C. Chan (2018). Traffic-Related Air Pollution Associated with Chronic Kidney Disease Among Elderly Residents in Taipei City. *Environmental Pollution*, **234**; 838–845
- Cho, C. C., W. Y. Hsieh, C. H. Tsai, C. Y. Chen, H. F. Chang, and C. S. Lin (2018). In Vitro and in Vivo Experimental Studies of PM_{2.5} on Disease Progression. *International Journal of Environmental Research and Public Health*, **15**(7); 1380
- Delfino, R. J., N. Staimer, and N. D. Vaziri (2011). Air Pollution and Circulating Biomarkers of Oxidative Stress. *Air Quality, Atmosphere & Health*, **4**(1); 37–52
- Gong, J., T. Zhu, H. Kipen, G. Wang, M. Hu, P. Ohman-Strickland, S.-E. Lu, L. Zhang, Y. Wang, P. Zhu, et al. (2013). Malondialdehyde in Exhaled Breath Condensate and Urine As A Biomarker of Air Pollution Induced Oxidative Stress. *Journal of Exposure Science & Environmental Epidemiology*, **23**(3); 322–327
- Hanifah, L. (2008). *The Effect of Papaya (Carica Papaya. L) on Glomerular Epithelial Necrosis and Renal Tubules of Mice (Musmusculus) Induced by Carbon Tetrachloride (CCl₄) in the Faculty of Science and Technology*. Master's thesis, State University of Malang
- Hossain, P., B. Kawar, and M. El Nahas (2007). Obesity and Diabetes in The Developing World—A Growing Challenge. *New England Journal of Medicine*, **356**(3); 213–215
- Michels, W. M., D. C. Grootendorst, M. Verduijn, E. G. Elliott, F. W. Dekker, and R. T. Krediet (2010). Performance of The Cockcroft-Gault, MDRD, and New CKD-EPI Formulas in Relation to GFR, Age, and Body Size. *Clinical Journal of the American Society of Nephrology*, **5**(6); 1003–1009
- Ning, X., B. Li, T. Ku, L. Guo, G. Li, and N. Sang (2018). Comprehensive Hippocampal Metabolite Responses to PM_{2.5} in Young Mice. *Ecotoxicology and Environmental*

- Safety*, **165**; 36–43
- Noeman, S. A., H. E. Hamooda, and A. A. Baalash (2011). Biochemical Study of Oxidative Stress Markers in The Liver, Kidney and Heart of High Fat Diet Induced Obesity in Rats. *Diabetology & Metabolic Syndrome*, **3**(1); 1–8
- Ozbek, E. (2012). Induction of Oxidative Stress in Kidney. *International Journal of Nephrology*, **12**(1); 1–10
- Research, B. H. (2013). *Jakarta Health Research and Development Agency of The Ministry of Health of the Republic of Indonesia*
- Salim, H. M., L. F. Kurnia, T. W. Bintarti, et al. (2018). The Effects of High-Fat Diet on Histological Changes of Kidneys In Rats. *Biomolecular and Health Science Journal*, **1**(2); 109–112
- Simon, J., M. Amde, and E. D. Poggio (2011). Interpreting The Estimated Glomerular Filtration Rate in Primary Care: Benefits and Pitfalls. *Cleveland Clinic Journal of Medicine*, **78**(3); 189–195
- Van Bladel, E. R., R. L. de Jager, D. Walter, L. Cornelissen, C. A. Gaillard, L. A. Boven, M. Roest, and R. Fijnheer (2012). Platelets of Patients with Chronic Kidney Disease Demonstrate Deficient Platelet Reactivity in Vitro. *BMC nephrology*, **13**(1); 1–6
- Wardoyo, A. Y., U. P. Juswono, and J. A. Noor (2017). An Observation of Histological Evidence on Internal Organ Damages in Mice Caused by Repeated Exposures to Motorcycle Emissions. *AIP Conference Proceedings*, **1844**(1); 020007
- WHO (2016). Ambient Air Pollution: A Global Assessment of Exposure and Burden of Disease