

**Original Article**

**Histopathological and biochemical effects of Aqueous Fruit Extract of *Balanite aegyptiaca* on Selected Organs of Mice**

Solomon Matthias Gamde<sup>1</sup>, Usman Wali<sup>2</sup>, Aminu Garba<sup>3</sup>, Daniel Dansy Agom<sup>4</sup>, Haruna Mallah Ayuba<sup>5</sup>

**Abstract**

**Background:** *Balanites aegyptiaca* is a medicinal plant for diabetes, leukemia, and breast cancer. Unfortunately, it is hard to assume whether the plant is safe because substantial data are lacking. **Objective:** To determine the biochemical effects of aqueous fruit extract of *Balanite aegyptiaca* in selected organs of mice. **Methods:** The acute toxicity study was performed using the Up and Down method at an oral limit dose of 5000 mg/kg in mice while subacute oral doses of 200, 400, and 800 mg/kg were administered for 28 days. Animals were weighed on those days to assess possible weight changes. After exposure, animals were euthanized and blood samples were collected via cardiac puncture for biochemical analysis. **Results:** The acute toxicity study showed no major toxic effect and indicated an LD<sub>50</sub> greater than 5000 mg/kg. Subacute doses of 200, 400, and 800 mg/kg extract did not produce significant changes in the body weights of animals for 28 days. There were no pathological changes in animals at 200 mg/kg. However, the extract significantly raised liver transaminases AST, ALP, ASP, and potassium ions at 400 and 800 mg/kg. **Conclusion:** *Balanite aegyptiaca* fruit had an LD<sub>50</sub> greater than 5000 mg/kg, indicating its safety at the acute level. In the Subacute assessment, extract at 200 mg/kg was not toxic. However, 400 and 800 mg/kg extract was toxic to the liver and lungs. The toxicological effects suggest that *Balanite aegyptiaca* fruit would be safe when controlled.

**Keywords:** *Balanites aegyptiaca*, medicinal plant, biochemical effects, liver function test, kidney function test

International Journal of Human and Health Sciences Vol. 07 No. 01 January'23 Page : 54-59  
DOI: <http://dx.doi.org/10.31344/ijhhs.v7i1.497>

**Introduction**

Medicinal plants have a distinct therapeutic window on biological systems used all over the world as functional food and medicines for many diseases. Unfortunately, in attempts to improve health, plants are misused with no substantial information on their safety<sup>1,2</sup>. Besides, most herbal practitioners who engaged in prescription do so with no empirical data for their safe dose<sup>3</sup>.

Medicinal plants could cause damage to vital organs of the body even when considered safe<sup>4</sup>

*Balanites aegyptiaca* Del. (Family Balantiaceae) is one of the most substantial herbal medicine for many diseases including diabetes, leukemia, colon, and breast cancers in Nigeria folklore similar to South Asia<sup>5,6</sup>. Pharmacological studies reported all parts of *B. aegyptiaca* to be medicinal and opens new opportunities for treating several diseases that are

1. Department of Medical Laboratory Science, Bingham University, Karu, Nasarawa State, Nigeria
2. Department of Chemical Pathology, School of Medical Laboratory Sciences, Usmanu Danfodiyo University Sokoto, Nigeria
3. Department of Haematological, School of Medical Laboratory Science, Usmanu Danfodiyo University Sokoto, Nigeria.
4. National Health Insurance Scheme Authority, Sokoto State Office, Nigeria
5. Department of Medical Laboratory Technician, Nigeria Air Force School of Medical Sciences and Aviation Medicine, Kaduna, Nigeria

**Correspondence to:** Solomon Matthias Gamde, Department of Medical Laboratory Science, Bingham University, Karu, Nasarawa State, Nigeria. Email: [solomonmatthias85@gmail.com](mailto:solomonmatthias85@gmail.com)

hard to cure. The fruits are used for hyperglycemia and hyperlipidemia which are risk factors for developing cardiovascular diseases such as atherosclerosis, hypertension, and coronary heart diseases<sup>7,8</sup>. The fruits are also used in the treatment of intestinal worms<sup>9</sup>, jaundice<sup>9</sup>, leukemia<sup>10</sup>, colon<sup>11</sup>, and breast cancers<sup>12</sup>. Besides, cancer and its treatments are known risk factors for other malignant disorders<sup>8,13</sup>.

*B. aegyptiaca* contains glycosides, coumarins, flavonoids, 6-methyldiosgenin, and saponins<sup>14</sup>. Saponins are a large family of both steroids and triterpenes with wide-ranging pharmacological properties such as anti-inflammatory, antibacterial, and anti-viral activities<sup>15,16</sup>. Although *B. aegyptiaca* fruit provides therapeutic options for treating diseases for which current therapies are minimal, there is no guaranteed safety on its use. The plants could cause damage to consumer even when considered safe. We aimed to determine the histopathological and biochemical effects of aqueous fruit extract of *Balanite aegyptiaca* in selected organs of mice.

## Materials and Methods

**Reagents:** Standard assay rat kits for AST, ALT, AP, and E/U/Cr were purchased from Ali Shuaibu diagnostics, Sokoto Nigeria

**Plant material:** The plant was collected from the Garden of Medicinal Plants at the Department of Pharmacognosy, Faculty of Pharmaceutical Sciences, Usmanu Danfodiyo University, and air-dried in shade at room temperature, pulverized into a fine powder by using a Pestle and Mortar.

**Extraction of the plant:** A hundred grams of powdered plant material was macerated in 2000 ml of distilled water for 24 hours. The mixture was filtered with Whatman paper and evaporated to dryness under reduced pressure by using a rotary evaporator.

**Preparation of the extract dose:** Extract 5.0 g was dissolved in 20 ml distilled water as a vehicle to get extract solution, then administered via oral gavage according to the animal's body weight.

**Animals used:** Twenty white albino mice of both sexes weighing 20-30 g bred in Animal House, Faculty of Pharmaceutical Sciences, Usmanu Danfodiyo University, Sokoto, Nigeria were used for the study. Experimental procedures followed the National Institute of Health Guide for the care

and use of Laboratory Animals<sup>17</sup> as reported in the guidelines written by the National Committee for Research Ethics in Science and Technology (NENT), Norway.

**Acute toxicity study:** An oral acute toxicity study was carried out using the 'Up-and-Down' method of testing mice and a dose of 5000 mg/kg was administered via oral gavage following the Organization for Economic Development (OECD) guideline<sup>18</sup>. Animals were observed for 30 min for signs of toxicity and mortality. The same procedure was repeated for the remaining animals and observed for 14 days.

**Subacute toxicity study:** A subacute toxicity study was carried out according to the Organization for Economic Development (OECD) guideline<sup>18</sup>. Twenty animals were randomly divided into four groups of five animals, Group's I-III received 200, 400, and 800 mg/kg extract dissolved in distilled water while group IV received distilled water (ml/kg). Animals were dosed daily via oral gavage using a curved, ball-tipped stainless steel feeding needle for 28 days<sup>18</sup>. Animals were weighed on those days to assess possible weight changes. On day 29, animals were anesthetized in chloroform after an overnight fast, and blood was drawn by cardiac puncture into plain sample bottles for biochemical analysis while the liver, kidney, lung, heart, and testis were excised for histological study.

**Tissue sampling:** Withdrawn blood was allowed to clot and centrifuged for serum biochemical analysis while the liver, kidney, lung, heart, and testis were preserved in 10% formalin until the histopathological study was done.

**Biochemical analysis:** The spun serum was analyzed for liver transaminases alkaline phosphatase (ALP), aspartate aminotransferase (AST), alanine aminotransferase (ALT), as well as total protein (TP), albumin (Alb), total bilirubin (TB), direct bilirubin (DB), urea, creatinine (Cr) and electrolytes; potassium (K<sup>+</sup>), sodium (Na<sup>+</sup>), chloride (Cl<sup>-</sup>), and bicarbonate (HCO<sub>3</sub><sup>-</sup>) were analyzed using diagnostic kits from Randox laboratory.

**Histopathological analysis:** The liver, kidney, lung, heart, and testis were fixed in 10% buffered formalin for 24 h. Fixed tissues were dehydrated in three changes of ethanol, dealcoholized in

xylene, and embedded in molten paraffin wax. Tissue sections were cut using a rotary microtome (Surgcare Microtome, Model 335A USA), and stained with hematoxylin and eosin (H&E).

**Data Analysis:** Statistical values obtained were presented as mean  $\pm$  standard deviation (SD) and analyzed using Way Analysis of Variance (ANOVA) (SPSS Version 25.0 Software USA) followed by the Bonferroni post hoc test.  $P < 0.05$  were considered significant.

**Results**

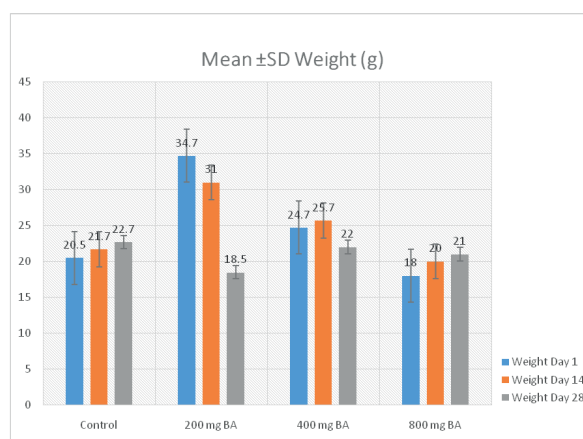
**Acute Toxicity Assessment:** Oral acute toxicity ( $LD_{50}$ ) of the aqueous fruit extract of *B. aegyptiaca Del* in mice was greater than 5000 mg/kg. No acute toxicity or mortality was recorded.

**Subacute toxicity Assessment:** There were no significant changes in the weights of animals treated with extract at 200, 400, and 800 mg/kg for 28 days compared to the control. However, the body weights of animals at 400 and 800 mg/kg significantly ( $P > 0.05$ ,  $P = 0.016$ ) increased at the 14<sup>th</sup> day of treatment (Table 1, Figure 1). The biochemical effect of *B. aegyptiaca* fruit extract at oral doses of 200, 400, and 800 mg/kg for 28 days are presented in Table 2. There was a significant ( $P < 0.05$ ) raised transaminase AST, AST, ALT, and potassium ions at 400 and 800 mg/kg. The conjugated and unconjugated bilirubin at all tested doses were also increased when compared with the control. However, the differences were not statistically significant. Furthermore, there were no significant differences in total protein and albumin in extract-treated animals compared with the control (Table 2, Figure 2 & 3).

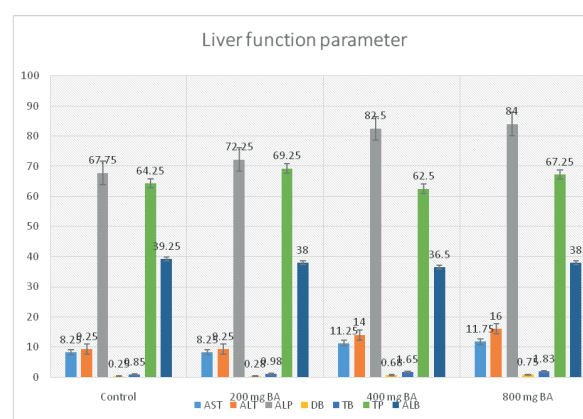
**Table 1:** Effect of the extract on body weights

Group	Weight Day 1	Mean $\pm$ SD Weight (g)	
		Weight Day 14	Weight Day 28
Control	20.50 $\pm$ 1.66	21.75 $\pm$ 1.55	22.75 $\pm$ 1.10
BA 200 mg	34.75 $\pm$ 2.18	31.00 $\pm$ 3.54	18.50 $\pm$ 6.46
BA 400 mg	24.75 $\pm$ 1.11	25.75 $\pm$ 1.49*	22.00 $\pm$ 1.58
BA 800 mg	18.00 $\pm$ 0.71*	20.00 $\pm$ 1.08*	21.00 $\pm$ 1.78
P-value	< 0.001	0.016	0.874

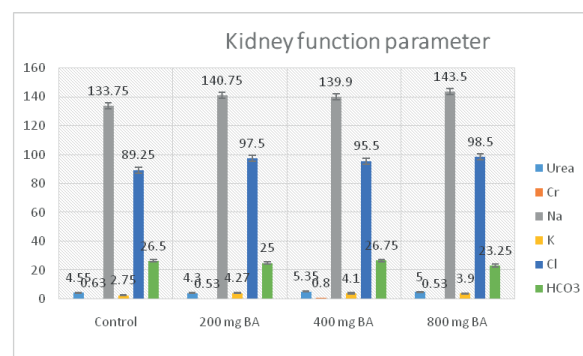
Data were expressed as mean  $\pm$  SD. The statistical analyses were performed using ANOVA and Bonferroni post hoc analysis. Significant at \* $P < 0.05$  compared with the control.



**Figure 1:** Effect of the extract on body weight



**Figure 2:** Effects of the extract on liver function parameters



**Figure 3:** Effects of the extract on kidney function parameters

**Discussion**

The oral acute toxicity test of aqueous fruit extract of *B. aegyptiaca* in mice at 5000 mg/kg body weight indicated no major toxic effect. According to the Organization for Economic Development Harmonized Classification System for chemical substances and mixtures, substances with  $LD_{50} > 2000 - 5000$  mg/kg are relatively safe<sup>18,19</sup>. This suggests that the extract may be relatively safe

**Table 2:** Effect of the extract on Biochemical Parameters

Parameter	Control	200 mg/kg BA	400 mg/kg BA	800mg/kg BA
ALT (IU/L)	9.25 ± 2.69	9.25 ± 0.95	<b>14.00 ± 4.76*</b>	<b>16.00 ± 4.83*</b>
AST (IU/L)	8.25 ± 1.65	8.25 ± 1.03	<b>11.25 ± 2.75*</b>	<b>11.75 ± 3.34*</b>
ALP (IU/L)	67.75 ± 5.23	72.25 ± 5.12	<b>82.50 ± 10.62*</b>	<b>84.00 ± 8.43*</b>
Albumin (mg/L)	39.25 ± 1.11	38.00 ± 0.71	36.50 ± 2.36	38.00 ± 0.58
Total protein (mg/L)	64.25 ± 1.65	69.25 ± 1.89	62.50 ± 0.87	67.25 ± 2.56
Total bilirubin (umol/L)	0.85 ± 0.07	0.98 ± 0.10	<b>1.65 ± 0.82*</b>	<b>1.83 ± 0.70*</b>
Direct bilirubin (umol/L)	0.25 ± 0.03	0.28 ± 0.03	<b>0.65 ± 0.45*</b>	<b>0.75 ± 0.42*</b>
Urea (µmol/L)	4.55 ± 0.55	4.30 ± 0.38	<b>5.35 ± 0.27</b>	<b>5.00 ± 0.28</b>
Creatinine(µmol/L)	0.63 ± 0.17	0.53 ± 0.09	0.80 ± 0.09	0.53 ± 0.13
Chloride (Cl-) (mmol/L)	89.25 ± 0.63	97.50 ± 4.44	95.50 ± 3.66	98.50 ± 3.07
Sodium (Na+) (mmol/L)	133.75 ± 4.72	<b>140.75 ± 1.93*</b>	<b>139.90 ± 4.66*</b>	<b>143.50 ± 2.84*</b>
Potassium (K+) (mmol/L)	2.75 ± 0.12	<b>4.27 ± 0.22*</b>	<b>4.10 ± 0.49*</b>	<b>3.90 ± 0.40*</b>
Bicarbonate (HCO <sub>3</sub> <sup>-</sup> ) (mmol/L)	26.50 ± 1.71	25.00 ± 2.12	26.75 ± 2.29	23.25 ± 1.80

Data were expressed as mean ± SD. Statistical analyses were performed using ANOVA followed by Bonferroni post hoc analysis. Significant at \* $P < 0.05$  compared with the control.

with an LD<sub>50</sub> greater than 5000 mg/kg. Besides, pharmaceutical compounds with LD<sub>50</sub> greater than 1000 mg/kg are considered to be of very low toxicity or safe<sup>20</sup>.

Subacute doses of *B. aegyptiaca* extract at 200, 400, and 800 mg/kg did not cause significant changes in the body weights of animals for 28 days when compared to the control. Body weight changes are a sensitive indicator of toxicity. An increased body weight suggests an episode of hypertrophy while a decrease suggests necrosis in the target organ<sup>21,22</sup>. Nonetheless, organ weight data must be interpreted in an integrated approach with the biochemical and histopathology assessments<sup>23</sup>. At 200 mg/kg, aqueous fruit extract of *B. aegyptiaca* did not cause any significant biochemical and histopathological changes in animals for 28 days. But, estimation of the serum biochemical parameters at 400 and 800 mg/kg extract indicated significantly raised liver transaminases AST, ALP, ASP, and potassium ions. Raised liver transaminases are classical laboratory findings in liver cell injury which measure the intracellular enzymes that have escaped into the blood circulation due to the

changes in the cell membrane integrity increased liver enzyme activities<sup>24</sup>.

The raised liver transaminases are in tandem with the histopathological changes which confirmed the presence of inflammatory cells in the liver and lung at 400 and 800 mg/kg extract. The findings were resembling those of Jane et al.<sup>19</sup> who reported increased liver enzymes following the administration of the stem bark extract of *B. aegyptiaca*.

Toxicological studies<sup>25,26,27</sup> reported that medicinal plants induced toxicities in the heart, kidney, and testis and as such could be an important tool in toxicological assessments. However, *B. aegyptiaca* did not cause any observable histopathological changes in the heart, kidney, and testis of animals. The maintenance of normal histological features of animals exposed to *B. aegyptiaca* may result from the extract metabolism before reaching distant tissues to the liver<sup>27</sup>. The toxicities observed in the liver and lung could be due to some phytochemical constituents that are present in *B. aegyptiaca*.

### Conclusion

*Balanite aegyptiaca* had an LD<sub>50</sub> greater than 5000

mg/kg, indicating its safety at the acute level. In the subacute assessment, extract at 200 mg/kg was not toxic. However, higher extract doses of 400 and 800 mg/kg were toxic to the liver and lungs with raised liver transaminases and potassium ions. The toxicological effects suggest *Balanite aegyptiaca* would be safe when controlled.

**Acknowledgment:** We acknowledged the technical support of Abdulrahman in the Animal's

House, Faculty of Pharmaceutical Sciences, Usmanu Danfodiyo University, Sokoto, Nigeria.

**Conflict of interest:** None declared.

**Funding:** Nothing to declare

**Authors' Contribution:** All authors were equally involved in data collection, analysis, manuscript preparation, revision and finalization.

---

### References:

1. Islam M, Sikder A, Rashid MA, Hossain K. Phytopharmacological Investigations of Leaves of *Cissus trifoliata* (L.). Dhaka Univ J Pharm Sci. 2022;21(1): 69-75.
2. Chowdhury V, Shristy NT, Rahman H, Chowdhury TA. Qualitative Phytochemical Screening, Fatty Acid Composition Analysis and Biological Studies of *Trianthemportulacastrum* L. Leaves. Dhaka Univ J Pharm Sci. 2022;21(1):33-43.
3. Emon NU, Rudra S, Alam S, Haidar A, Paul S, Richi FT, et al. Chemical, biological and protein-receptor binding profiling of *Bauhinia scandens* L. stems provide new insights into the management of pain, inflammation, pyrexia, and thrombosis. Biomed Pharmacother. 2021;143:112185.
4. Ukoha UU, Mbagwu SI, Ndukwe GU, Obiagbo C. Histological and Biochemical Evaluation of the Kidney following Chronic Consumption of *Hibiscus sabdariffa*. Hindawi Publishing Corporation. Adv Biol. 2015;1-5.
5. Sagna MB, Niang KS, Guisse A, Goffner D.

- Balanites aegyptiaca (L.) Delile: Geographical distribution and ethnobotanical knowledge by local populations in the Ferlo (North Senegal)/Balanites aegyptiaca (L.) Delile: Distribution géographique et connaissances ethnobotaniques des populations locales du Ferlo (nord Sénégal). Biotechnologie, Agronomie, Société et Environnement. 2014;18(4):503.
6. Ibrahim EE. Phytochemical, antioxidant activity, and cytotoxicity of methanolic extract of *Balanites aegyptiaca* (L.) DELILE. *Pharmacie Globale*. 2016;7(1):1.
  7. Hassan MD, Abdulkarim ZI, Mary M. Effects of *Balanites aegyptiaca* fruit pericarp on fructose-induced hyperglycemia and hyperlipidemia in rats. *Asian J Biotech*. 2020;12:87-96.
  8. Al-Ashaal HAS. Antidiabetic, cytotoxic, antioxidant and antitrematodal medicinal efficacy of polar and non-polar phytochemicals of *Balanites aegyptiaca* Del. *Asian Pac J Trop Dis*. 2017;7(12):797-805.
  9. Raushanara A, Raquibul HSM, Mokarram HM, Mariam J, Sultana SC, Mazumder MEH, et al. Antidiarrhoeal and Antioxidant Properties of *Curcuma alismatifolia* leaves. *Aust J Basic Appl Sci*. 2010;4(3):450-6.
  10. Putul M, Sunit C, Pritha B. Neovascularisation offers a new perspective to glutamine-related therapy. *Ind. J. Exp. Biol*. 2000;38:88-90.
  11. Elie BY, Shimon BS, Noa G, Bishnu PC, Rui H. Anti-proliferative activity of steroidal saponins from *Balanites aegyptiaca*—An in vitro study. *Phytol*. 2010;180.
  12. Gnoula C, Megaliz ZV, Neve ND, Sauvage S, Ribaucour F, Guissou P, et al. Balanitin-6 And -7: Diosgenyl Saponins Isolated From *Balanites Aegyptiaca* Del. Display Significant Anti-Tumor Activity In Vitro and In Vivo. *Int J Oncol*. 2008;32:5-15.
  13. Nelson KA, Walsh D, Abdullah O, McDonnell F, Homsy J, Komurcu S, et al. Common complications of advanced cancer. *Semin Oncol*. 2000;27(1):34-44.
  14. Raju J, Mehta R. Chemo-preventive and therapeutic effects of diosgenin, a food saponin. *Nutr. Cancer*. 2009;61(1):27–35.
  15. Salzman R, Pácal L, Tomandl J, Kanková K, Tóthová E, Gál B, Kostrica R, et al. Elevated malondialdehyde correlates with the extent of the primary tumor and predicts poor prognosis of oropharyngeal cancer. *Anticancer Res*. 2009;29(10):4227-31.
  16. Ramos-Vara, JA. Technical Aspects of Immunohistochemistry. *Vet Pathol*. 2005;42(4):405-26.
  17. National Institute of Health (NIH). Guide for the Use of Laboratory Animals DHHS, PHS NIH. 1985;85-23.
  18. Organization for Economic Development. Guideline for testing of chemicals. Guidance no. 425. Up and Down procedure, Adopted: 17th December 2001.
  19. Ugwah-Oguejiofor CJ, Okoli CO, Ugwah MO, Umaru ML, Ogbulie CS, Mshelia HE, et al. Acute and sub-acute toxicity of aqueous extract of aerial parts of *Caralluma adalzielii* N. E. Brown in mice and rats. *Heliyon*. 2018;5:e01179.
  20. Ibrahim H, Williams FE, Salawu KM, Usman AM. Phytochemical screening and acute toxicity studies of crude ethanolic extract and flavonoid fraction of *Carissa edulis* leaves. *Biokemistri*. 2016;27(1):39-43.
  21. Arthur FKN, Woode E, Terlabi EO, Larbie C. Evaluation of acute and subchronic toxicity of *Annona Muricata* (Linn.) aqueous extract in animals. *Eur J Exp Biol*. 2011;1(4):115-24.
  22. Teo S, Stirling D, Thomas S, Hoberman A, Kiorpes A, Khetani V. A 90-day oral gavage toxicity study of d-methylphenidate and d, l-methylphenidate in Sprague Dawley rats. *Toxicol*. 2002;179(3):183e196.
  23. Sellers RS, Morgan D, Michael B, Roome N, Johnson JK, Yano BL, et al. Society of Toxicologic Pathology position paper: organ weight recommendations for toxicology studies. *Toxicol. Pathol*. 2007;35(5):751e755.
  24. Gamde SM, Kabiru H, Abubakar A, Abubakar K, Musa A, Perede A. Histopathological and Biochemical Effects of Aqueous Leaf Extract of *Cadabafarinsa* on Liver of Adult Wistar Rats. *Int J Res Med Sci*. 2019;7(3):3716-21.
  25. Yakubu MT, Akanji, MA, Oladiyi AT. Hematological Evaluation in Male Albino Rats Following Chronic Administration of Aqueous Extract of *Fadogia agrestis* Stem. *Pharmacognosy Magazine*. 2007;3:34-38.
  26. Osigwe CC, Akah PA, Nworu CS. Biochemical and Hematological Effects of the Leaf Extract of *Newbouldia levis* in Alloxan-Induced Diabetic Rats. *J Biosci Medi*. 2017;5:18-36.
  27. Hassaan EF, Kadhim DJ, Younus MM. Safety Profile of Biological Drugs in Clinical Practice: A Retrospective Pharmacovigilance Study. *Iraqi J. Pharm. Sci*. 2022;31(1):32-42.