

## Case Report

### Is Hypereosinophilia A Sign of Underlying Tuberculosis? A Case Report and Review of Literature

Majed Abdul Basit Momin<sup>1</sup>, Abhijeet Ingle<sup>1</sup>, G Vamshi Krishna Reddy<sup>2</sup>, R Rahul Dev Singh<sup>1</sup>, Rubina Hassan<sup>1</sup>

#### Abstract

Eosinophilia is a common haematological problem that we see in our clinical practice. It is unusual to find hypereosinophilia at the onset of inguinal tuberculous lymphadenitis and hepatic non-granulomatous eosinophilic necrosis. We present the case of a 67-year-old man who complained of a dry cough for three months and a fever for one month. The right inguinal lymph node was palpable on clinical examination and initial haematological investigation revealed marked hypereosinophilia, mimicking myeloproliferative disorder. A thorough imaging workup revealed extensive thoracic lymphadenopathy as well as multiple liver lesions. Further liver mass core biopsy revealed hepatic, non-granulomatous necrosis with eosinophilic infiltration, whereas excision biopsy of inguinal lymph node revealed granulomatous inflammation with positive acid-fast bacilli on histopathological examination. The patient responded to anti-tubercular treatment with steroids and hydroxyurea. The case emphasizes the association of eosinophilia in tuberculosis with tendency to forming mass lesions in liver and also the role of eosinophilic proteins in tissue injury.

**Keywords:** Hypereosinophilia; inguinal tuberculosis; hepatic necrosis

*International Journal of Human and Health Sciences Vol. 07 No. 03 July'23 Page :262-266  
DOI: <http://dx.doi.org/10.31344/ijhhs.v7i3.584>*

#### Introduction

Eosinophilia is defined as a peripheral blood (PB) eosinophil count greater than 500 per microliter. Hypereosinophilia (HE) is defined by a marked increase in eosinophils in PB  $\geq 1.5 \times 10^9/L$ . The disorder would be categorized as hypereosinophilic syndrome (HES) if HE is persistent (lasting longer than 6 months)<sup>1</sup>. The consistent presence of a high number of eosinophils in the PB can eventually cause multiple organ tissue damage as these eosinophils infiltrate different tissues and cause inflammation. Consequently, identifying an underlying condition that requires effective treatment is a key goal of early HE assessment.

Tuberculous lymphadenitis remains a common extrapulmonary manifestation of tuberculosis

(TB). Tuberculous lymphadenitis most commonly involves cervical group of lymph nodes and involvement of inguinal group of lymph nodes is uncommon<sup>2</sup>. The precise function of eosinophils in the host immune responses in TB remains poorly understood. The function of eosinophils in the host protection and inflammatory pathology related to hypereosinophilia in TB is not well described in literature<sup>3</sup>.

#### Case Summary

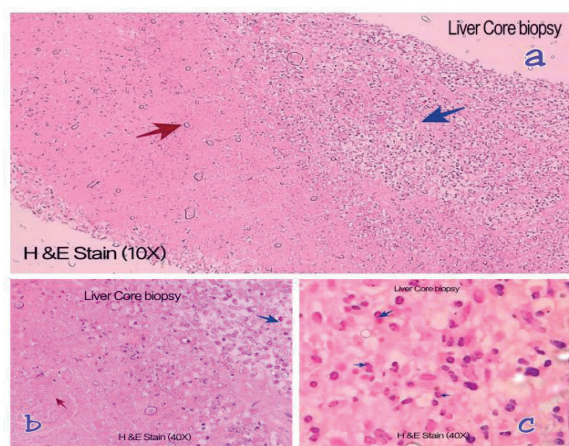
A 67-year-old male presented with complaints of dry cough for three months, fever for one month and one episode of bleeding per rectum. The cough was insidious in onset, dry in nature and not associated with sputum. The patient was hemodynamically stable except for a mild fever 100<sup>0</sup> F. On

1. Department of Laboratory Medicine, Yashoda Hospitals, Malakpet Branch, Hyderabad, Telangana State, India.
2. Department of Medical Oncology, Yashoda Hospitals, Malakpet Branch, Hyderabad, Telangana State, India.

**Correspondence to:** Dr. R. Rahul Dev Singh, Consultant Pathologist, Department of Laboratory Medicine, Yashoda Hospitals, Malakpet Branch, Hyderabad, Telangana State, India. Email: [rahuldevsingh16@gmail.com](mailto:rahuldevsingh16@gmail.com)

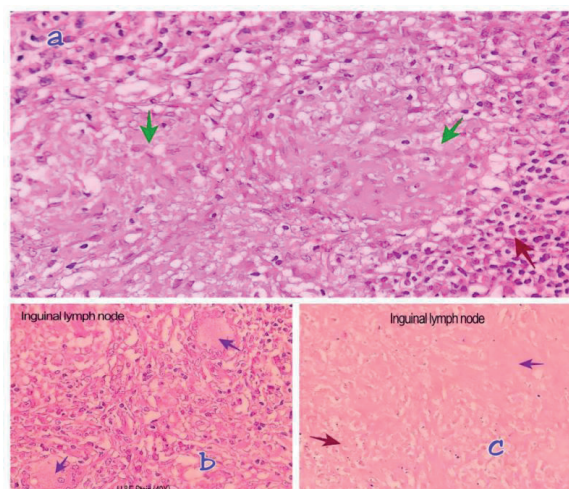
examination, the patient was thin built with no signs of anemia, icterus, cyanosis or clubbing. The deep right inguinal nodes were palpable, matted, non-tender and mobile, measuring 2.0 × 2.0 cm in size. The systemic examination was unremarkable. Initial lab investigation, hemogram revealed (Table 1) mild anemia, hyperleukocytosis with marked hypereosinophilia with 92% eosinophils on differential white blood cells count, Absolute eosinophil count was 3,63,400/cumm. The platelet count was normal in number and morphology. Peripheral blood film showed normocytic normochromic RBCs, mild anisocytosis and marked eosinophilia. Morphologically eosinophils were mature, bilobed, with few trilobed forms. Eosinophilic orange granulation with no evidence of dysplastic eosinophils (nuclear hypersegmentation or hypo segmentation, sparse granulation or cytoplasmic vacuolation) was seen. No blast cells or no hemoparasite were seen in peripheral smear. The liver function test revealed (Table 1) increased transaminases and alkaline phosphatase levels. Renal function tests were normal. Viral screening for HIV-1 and HIV-2, anti-hepatitis C antibody and hepatitis B surface antigen were negative. Erythrocyte sedimentation rate was 20 mm in the first hour. Complete urine examination was normal and stool examination did not reveal any ova or cyst. Bone marrow aspirate showed prominence of eosinophils and its precursors with no prominence of blast. Mantoux test was less than 10 mm. Stool culture after 48-hour aerobic incubation was negative. Serological tests for filarial antigen/antibody and test for ecchinococcus were also negative. Clonal cytogenetic or molecular genetic abnormality was not detected.

Chest radiograph showed normal findings except mild prominence of bronchovascular markings. PET-CT showed multiple enlarged nodes in pre, para tracheal, bilateral axillae, bilateral supraclavicular region and right inguinal lymph nodes. Patchy peripheral consolidation of superior segment lower lobe of right lung was also seen. Multiple nodular lesions were seen in liver with retro-peritoneal and peritoneal lymphadenopathy. Ultrasound guided liver nodule core biopsy was performed. On histological examination it showed large areas of necrosis with viable areas densely infiltrated by eosinophils. There were no atypical or malignant cells (Figure 1).



**Fig. 1:** (a) Liver core biopsy (H&E stain, ×10); (b & c) necrosis (red arrow) eosinophilic infiltration (blue arrow) (H&E stain, ×40).

Excision biopsy of right inguinal node on histological examination showed multiple, confluent epithelioid granulomata along with Langhan's type giant cells, areas of necrosis and hyalinization. Special stain (Ziehl-Neelsen) for acid-fast bacilli (AFB) highlighted few of the organisms (AFB).



**Fig. 2:** Inguinal lymph node (H&E stain) shows granuloma (green arrow), Langhan's giant cells (2b) (red arrow) and hyalinization and caseous necrosis (red arrow).

Overall histologic features were suggestive of Caseating granulomatous lymphadenitis of tuberculous etiology. Based on histological findings patient was treated with anti-tubercular drugs, steroids and hydroxyurea. Patient's fever and cough subsided, and eosinophils and absolute eosinophil count gradually decreased (Table 1).

**Table 1:** Laboratory test results

Sl. no.	Lab parameters	Test Results				Biological reference interval
		Day 1	Day 4	Day7	Day 10	
1	Hemogram					
	Hemoglobin	10.5	9.2	9.0	9.0	12-15 gm%
	White blood cells	3,951a khs	1,931a khs	86,900	40,800	4000-11000/cumm
	Eosinophils (%)	92%	95%	90%	84%	00%-06%
	Absolute eosinophil count	3,6340 0	1,838 25	78,210	34272	40-440/cumm
	platelets	2.0	2.2	2.0	1.90	1.5 -4.5 lacs/cumm
2	LFT					
	Total Bilirubin	1.3		0.4	0.8	0.2-1.3 mg/dl
	Direct	0.2		0.1	0.2	0-0.3 mg/dl
	Indirect	1.1		0.3	0.6	0-1 mg/dl
	SGOT	128		30	26	14-60 U/L
	SGPT	46		16	15	0-35 U/L
	Alkaline Phosphatase	501		364	296	38-126 U/L
	Total Proteins	8.1		5.5	5.0	6.3 - 8.5 gm/dl
	Albumins	3.1		2.2	2.0	3.5-5.0 gm/dl
	Globulins	5.0		3.3	3.0	2.3 -3.5 gm/dl
3	Serum Creatinine	0.5		0.8	0.7	0.7- 1.2 mg/dl

## Discussion

The case presented here is that of an elderly male who presented with a prolonged history of fever and dry cough. At the time of the initial hospitalization, the patient had severe eosinophilic leukocytosis and a high absolute eosinophilic count, which suggested chronic eosinophilic leukemia. However, clinically palpable inguinal lymph nodes and an imaging study that revealed multiple nodular lesions in the liver and extensive lymphadenopathy made distinguishing it from metastasis difficult. Further testing, including bone marrow aspiration cytology, stool routine, and culture examinations, ruled out all common secondary causes of hypereosinophilia and cytogenetic and molecular testing later ruled out clonal eosinophilia. Finally, histological

examination revealed that the patient had extrapulmonary tuberculosis (inguinal tuberculous lymphadenitis) with hepatic non-granulomatous eosinophilic necrosis.

Eosinophils comprise 1–3% of total leukocytes and the normal percentage of eosinophils in blood varies between 0.0 to 6.0%. Allergic and intestinal parasitic infections are considered among common causes of eosinophilia<sup>4</sup>. Table 2 lists the causes based on absolute eosinophil counts<sup>5</sup>. There is no mention of tuberculosis in medical literature as a cause of eosinophilia.

**Table 2:** Degree of eosinophilia

Severity of Eosinophilia	AEC levels per micro liter	Differential diagnosis
Mild	500-1000	Allergic diseases Atopy Asthma Drug allergy Bacterial and Viral infections
Moderate	1500- 5000	Parasitic Infections HES Churg-Strauss Syndrome Cancers Sézarys Syndrome
Severe	>5000	Hypereosinophilic Syndrome (HES) Eosinophilic leukemia Cancer

Tissue HE is defined as (1) eosinophils >20% of all nucleated cells in a bone marrow aspirate (2) tissue infiltration by eosinophils that, in the opinion of an experienced pathologist, is markedly increased; or (3) extensive extracellular deposition of eosinophil-derived proteins in tissue as demonstrated by immunostaining<sup>4</sup>. The hypereosinophilic syndromes (HES) are a group of disorders marked by the sustained overproduction of eosinophils, in which eosinophilic infiltration and mediator release cause damage to multiple organs including heart, gastrointestinal tract, liver, lungs, central nervous system and kidneys. Some HES remain idiopathic and some are associated with significant predisposition to myeloproliferative disorder and leukemia like syndrome.<sup>6</sup>

Hepatic involvement of hypereosinophilic syndrome is uncommon. The eosinophilic infiltration with hepatic necrosis is commonly seen in the case of visceral larvae migrans, in which many Charcot-Leyden crystals are also seen in liver histology. Other rare causes are drug induced hypersensitivity, primary biliary cirrhosis and primary sclerosing cholangitis<sup>7</sup>. The histological changes are because of cytotoxic effect of discharge of toxic biologically active proteins from eosinophils, including cationic proteins [such as major basic protein (MBP), eosinophil peroxidase (EPO), eosinophil cationic protein (ECP) and eosinophil-derived neurotoxin (EDN)], cytokines, chemokines and growth factors<sup>6</sup>. Imaging findings in these cases show multiple mass lesions which are difficult to differentiate from hepatocellular carcinomas, metastatic carcinoma or malignant lymphoma. Image guided core biopsy or Fine needle aspiration cytology plays a crucial role for histopathological or cytological confirmation in these cases<sup>7</sup>.

Eosinophil recruitment is common in TB infections, but their actual contribution to *Mycobacterium tuberculosis* growth is unknown. However, several studies have found that eosinophil cationic proteins

are mycobactericidal and promote lysis. Ray et al. proposed that in susceptible patients, an early hypersensitivity reaction to the mycobacterium antigen could cause florid tropical pulmonary eosinophilia and IL-5 has been identified as the most important cytokine responsible for the expansion of peripheral eosinophilia<sup>8</sup>. Peripheral eosinophilia in abdominal TB was described by Gill et al. He determined through a histological examination of the peritoneal biopsy<sup>9</sup>. Flores et al. reported a case of peripheral blood eosinophilia with tuberculosis in a patient with weight loss and lymphadenopathy, which was similar to our case. A lymph node biopsy revealed a granulomatous lesion<sup>10</sup>. Furthermore, Haftu et al. described a case of hepatic tuberculosis in a 9-year-old child who had hepatic nodules and peripheral blood eosinophilic leucocytosis<sup>11</sup>. The goal of hypereosinophilic treatment is to reduce eosinophil levels in blood and tissues, thereby preventing tissue damage. The treatment modalities includes glucocorticoids like prednisone and chemotherapeutic agents such as hydroxyurea, chlorambucil and vincristine<sup>9</sup>.

### Conclusion

To conclude, hypereosinophilia, as pronounced at diagnosis, is rare in patients with tuberculous inguinal lymphadenitis and should be considered in the differential diagnosis, especially when more common causes have already been ruled out. HE is one of the mass-forming diseases in the liver and liver biopsy is a useful diagnostic tool. Although the link between hypereosinophilia and tuberculosis is still being researched, eosinophil proteins have been proven to cause histological changes in tissues.

**Conflict of Interest:** None declared.

**Source of Fund:** Nil.

**Authors contribution:** Concept and design: MBM, AI, GVKR, RDS, RH; Major revision: MBM, RDS, RH, Final approval of the manuscript: MBM, AI, GVKR, RDS, RH.

## References

1. Gotlib J. World Health Organization-defined eosinophilic disorders – Update on diagnosis, risk stratification, and management. *Am J Hematol.* 2015;90:1077-89.
2. Farhad M, Arafat SM, Mazumder MK, Kabir MR, Mohaimenul Haq SM, Uddin MJ, et al. Persistence of granuloma or granulomatous inflammation after Six Months of CAT-1 anti tuberculosis therapy in tubercular lymphadenitis patients. *Bangladesh J Med Sci.* 2023;22(1):216-21.
3. Prakash Babu S, Narasimhan PB, Babu S. Eosinophil Polymorphonuclear Leukocytes in TB: What We Know so Far. *Frontier in Immunol.* 2019;10:2639.
4. Muhammad F Rozi, Dewi M Darlan, Rodiah Rahmawati, Dewi IS Siregar. Intestinal parasitic infections and eosinophilia: A cross-sectional Study among primary school-aged children in Medan, Indonesia. *Int J Hum Health Sci (IJHHS).* 2020;4(4):277-81.
5. Rothenberg ME, Hogan SP. The eosinophils. *Ann Rev Immunol.* 2006;24:147-74.
6. Lehrer RI, Szklarek D, Barton A, Ganz T, Hamann KJ, Gleich GJ. Antibacterial properties of eosinophil major basic protein and eosinophil cationic protein. *J Immunol* 1990;142:4428-34.
7. Keda H, Katayanagi K, Kurumaya H, Harada K, Sato Y, Sasaki M. Case of hypereosinophilia – associated multiple mass lesions of liver showing non-granulomatous eosinophilic hepatic necrosis. *Gastroenterol Res.* 2011;4(4):168-73.
8. Ray D, Abel R. Hypereosinophilia in association with pulmonary tuberculosis in a rural population in south India. *Indian J Med Res.* 1994;100:219-22.
9. Gill AM. Eosinophilia in tuberculosis. *Br Med J.* 1990;2:220-1.
10. Flores M, Merino-Angulo J, Tanago JG, Aquirre C. Late generalized tuberculosis and eosinophilia. *Arch Intern Med.* 1983;143:182.
11. Haftu H, Tadese K, Gebrehiwot T, Gebregziabher H. How common is eosinophilia in tuberculosis? case report. *Pediatric Health Med Ther.* 2020;11:59-63.