

Protective Effects of Safranal Against Selenite-Induced Cataract in RatsFarah A. Mahdi ^{*1} and Munaf H. Zalzal ^{**}^{*}Ministry of Health and Environment, Iraq.^{**}Department of Pharmacology and Toxicology, College of Pharmacy, University of Baghdad, Baghdad, Iraq.**Abstract**

Cataract, which is the opacity inside clear ocular lens of eye, result in the scattering of visible light as it passes via the lens and consequently deterioration in optical image. The aim of the present study was to investigate whether safranal, an active constituent of *Crocus sativus* L. stigmas, has a protective effect on the cataract in the rat's pups. The animals were randomly divided into five groups, each of which consisted of 7 rat pups. Group I served as normal control (vehicle administration). For testing cataract induction, animals of Groups II, III, and IV were administered a single subcutaneous injection of sodium selenite on postpartum day 12. After sodium selenite intoxication, Group II served as control selenite, Groups III-IV received intraperitoneal safranal at doses of 200, and 300 mg/kg, respectively from the 11th day through the 17th day, while group V receive only safranal (300 mg/kg). On postpartum day 30, the rat pups were examined for cataract formation, and the lenses were isolated for further analysis. This study found that selenite caused significant ($p < 0.05$) cataract formation. Through the effects of selenite on the level of lipid peroxidation (MDA) which was upregulated. Furthermore, the antioxidant enzymes levels GSH levels and Nuclear factor erythroid 2-related factor 2 (NRF2) protein were downregulated. In contrast, treatment with safranal could significantly ($p < 0.05$) ameliorate cataract formation and oxidative damage in the lens. Moreover, safranal administration significantly increased the protein expressions of NRF2 and the GSH level, in addition to reducing the level both the MDA and the level soluble proteins in the lens. Taken together, safranal is a prospective anti-cataract agent that probably delays the onset and progression of cataracts induced by sodium selenite.

Keywords: Cataract, Safranal, Sodium selenite, Oxidative damage

التأثير الوقائي للسفرنال ضد تولد الماء الابيض في العين المستحث بواسطة السيلينيت في الجرذان

فرح عبد الكريم مهدي ^{*1} و مناف هاشم زلزلة

^{*} وزارة الصحة والبيئة ، العراق
^{**} فرع الادوية والسموم ، كلية الصيدلة ، جامعة بغداد ، بغداد ، العراق .

الخلاصة

إعتام عدسة العين ، وهو التعتم داخل عدسة العين الصافية ، ينتج عنه تشتت الضوء المرئي أثناء مروره عبر العدسة وبالتالي تدهور في الصورة البصرية. كان الهدف من هذه الدراسة هو معرفة ما إذا كان السفرنال ، المكون النشط لنبات الزعفران ، له تأثير وقائي على الساد في صغار الفئران. تم تقسيم الحيوانات بشكل عشوائي إلى خمس مجموعات ، كل منها تتكون من ٧ صغار الجرذان خدمت المجموعة الأولى كعنصر مراقب. لاختبار تحريض الساد ، تم إعطاء حيوانات المجموعات الثانية والثالثة والرابعة حقنة واحدة تحت الجلد من سيلينيت الصوديوم في اليوم الثاني عشر بعد الولادة. المجموعة الثانية خدمت كنموذج للساد. المجموعة الثالثة والرابعة تلقت جرعة من السفرنال ٢٠٠ و ٣٠٠ مجم / كجم على التوالي من اليوم الحادي عشر حتى اليوم السابع عشر ، بينما تتلقى المجموعة الخامسة السفرنال فقط (٣٠٠ مجم / كجم). في اليوم ٣٠ بعد الولادة ، تم فحص صغار الفئران لتشكيل الساد ، وتم عزل العدسات لمزيد من التحليل. وجدت هذه الدراسة أن السيلينيت تسبب في تكوين إعتام عدسة العين بشكل كبير ($P < 0.05$). من خلال تأثيرات السيلينيت على مستوى بيروكسيد الدهون (المالوندي الديهايد). علاوة على ذلك ، تم تقليل مستويات إنزيمات مضادات الأكسدة ومستويات الكلوتاثيون والعمل النووي المتعلق بالكريات الحمر على النقيض من ذلك ، يمكن أن يؤدي العلاج باستخدام السفرنال إلى تحسين تكوين الساد والضرر التأكسدي في العدسة بشكل كبير ($p < 0.05$). علاوة على ذلك ، أدى تناول السفرنال إلى زيادة كبيرة في مستويات العمل النووي المتعلق بالكريات الحمر ومستوى فعالية الكلوتاثيون ، بالإضافة إلى تقليل مستوى كل من المالوندي الديهايد ومستوى البروتينات القابلة للذوبان في العدسة. إذا أخذنا معاً ، فإن السفرنال هو عامل محتمل مضاد لإعتام عدسة العين والذي من المحتمل أن يؤخر ظهور وتطور إعتام عدسة العين الناجم عن سيلينيت الصوديوم.

الكلمات مفتاحية: إعتام عدسة العين (الماء الابيض) ، سفرنال ، صوديوم سيلينيت ، مضادات الاكسده.

Introduction

Cataract, which is the opacity inside clear ocular lens of eye, result in the scattering of visible light as it passes via the lens and consequently deterioration in optical image ⁽¹⁾. Cataract is the world's leading blindness condition. WHO has valued that by the year 2020 there will be 54 million

blind individuals aged 60 years or older ⁽²⁾. It's causing a huge socio-economic burden ⁽³⁾. While cataract surgery has become one of the most common cataract therapies, many risks and complications still occur ⁽⁴⁾. If the onset of clinical cataract can be delayed for 10 years, it is estimated that half of the cataract surgery will not be necessary ⁽⁵⁾.

¹Corresponding author E-mail: munafzalzal@copharm.uobaghdad.edu.iq

Received: 24/ 9 /2020

Accepted: 24/ 11 /2020

The most powerful initiating factor for cataract development is the damage caused by the generation of reactive oxygen species (ROS), and exacerbated by oxidative stress / endoplasmic reticulum stress^(6, 7). Lens distortion is a direct result of oxidative stress, when aging occurs. Abnormalities in the normal state of redox cells can cause toxic effects by generating peroxides and free radicals which damage all cell components, including proteins, lipids and DNA. The redox cycles are important for maintaining lens transparency⁽⁸⁾.

Nuclear factor erythroid 2-related factor 2 (NRF2), a main antioxidant protection manager, can monitor gene expression of antioxidant; Nrf2 translocates a nucleus from cytoplasm and thus attaches to antioxidant response elements (AREs), stimulated by exogenous oxidative stress. A process that causes enhances the expression of antioxidant product, which finally strengthens the antioxidant defense mechanism intracellular. The development of lens opacification is evidently linked to the lack of action on antioxidant enzymes. When the development of the antioxidant enzyme increases, cataractogenesis may be stopped or postponed⁽⁹⁾.

The sodium selenite is a cataractogenic agent widely used since 1978 in animal models⁽¹⁰⁾. This causes cataract development when administered to young rats at nearly 16 days of age before the completion of the essential lens maturation duration⁽¹¹⁾. Biochemical processes, including modified epithelial metabolism, accumulation of calcium, proteolysis caused by calpain, precipitation of crystalline, phase transition, loss of the cytoskeleton, and NRF2 suppressors which inhibition the NRF2-dependent antioxidant protection in lenses occur during the cataract development can be induced by selenite^(11, 12). The reaction of selenite with reduced GSH has proven oxygen active production⁽¹³⁾. Various antioxidants such as vitamin C prevent this oxidative stress and the cataract induced by selenite⁽¹⁴⁾.

Safranal (2,6,6-trimethyl -1,3-cyclohexadiene -1-carboxaldehyde) is one of the organic compounds that isolated from saffron (*Crocus sativus*)⁽¹⁵⁾. *Crocus sativus* L. (Saffron) is utilized as a coloring and flavoring agent in the food preparation in numerous areas of the world, also as healing agents against several medicine disorders⁽¹⁶⁾. Safranal has reported to have several pharmacological activities involving antioxidant, anti-inflammatory, anti-apoptotic, anti-ischemic, anticonvulsant, antidepressant, and anxiolytic effects⁽¹⁷⁾. Safranal as an antioxidant in biological environments has benefited from its ability scavenge of free radical and reduce the oxidative stress of unsaturated phospholipid membrane⁽¹⁸⁾.

In this study, we evaluated if intraperitoneal safranal administration avoids cataract development in a selenite-induced

experimental cataract rat's model, and the status of GSH as antioxidant and malondialdehyde (MDA) as a lipid peroxidation indicator in extracted rat lenses.

Materials and Methods

Chemical and kits

All chemicals used within the experimental were available in the highest degree of purity. Safranal and sodium selenite obtained from (Sigma Chem. Co., St. Louis), diethylether and liquid paraffin from (BDH chemicals /England).

The kits used in this study include [rat glutathione (GSH) and Malondialdehyde (MDA) Elisa kit] were bought from (Sunlong Biotech Co. /China) while rat Nuclear Factor -E2 related factor 2 (Nrf2) Elisa Kit from (My Biosource /USA), and Bradford protein assay kit from (Gene Copoeia /USA).

Animal and experimental model

Neonatal rat's pups of Wister albino strain each one weighting 12-16 gm on postpartum 8 days. The pups were housed in polypropylene cages in rooms held at 25±1°C along with their mother. The rats were maintained on a standard laboratory animal diet, providing water ad libitum during the experimental period and a daily 12h cycle during the test period: 12 h mild-dark cycle. The animals were handled according to regulations approved by ethical committee in University of Baghdad for using the animals in research. A suckling rat pups and their mother were divided in to 5 group one control group and four experimental groups, each group consist of 7 animals as follows:

Group I (Control group): Rat pups injected subcutaneously with normal saline at day ten postpartum with intra-peritoneal injection of liquid paraffin at day 8 postpartum for 30 days.

Group II (Model group): Rat pups injected subcutaneously with single dose of sodium selenite at day ten postpartum with daily intra-peritoneal injection of liquid paraffin at day 8 postpartum for 30 days.

Group III: Rat pups injected subcutaneously with single dose of sodium selenite at day ten postpartum with daily intra-peritoneal injection of safranal 200 mg/kg at day 8 postpartum for 30 days

Group IV: Rat pups injected subcutaneously with single dose of sodium selenite at day ten postpartum with daily intra-peritoneal injection of safranal 300 mg/kg at day 8 postpartum for 30 days

Group V: Rat pups injected subcutaneously with normal saline at day ten postpartum with intra-peritoneal injection of safranal 300 mg/kg at day 8 postpartum for 30 days.

Morphological evaluation of rat pups lenses:

Using an ophthalmoscope or with a naked eye, the lenses were visualized starting from the day they opened their eyes (14-16 days after birth). The ophthalmoscope assessed opacity gradation weekly. The pupils were dilated to induce mydriasis using a topical tropicamide ophthalmic eye drop. The lens opacity score (using ophthalmoscope grading criteria) was performed classification⁽¹⁹⁾: Grad 0: clear normal lens; Grad 1: subcapsular opacity; Grad 2: nuclear cataract; Grad 3: strong nuclear cataract with perinuclear area opacity; Grad 4: matured nuclear cataract.

Preparation of lenses samples

On postpartum day 30, all animals were anesthetized and euthanized by cervical rupture. Lenses were isolated intracapsulay via incision 2mm posterior to limbus, lenses without their capsules were weight then separated pair of lenses were homogenized ten times their mass with phosphate buffer pH (7.4) by homogenizer. The Supernatant was obtained by 15 minutes centrifugation of homogenate at 5000 rpm. Supernatant was stored for analysis of GSH, MDA level and NFR2 activity and protein content at -80 C in aliquots. All these assays were done in standard condition⁽¹⁰⁾.

Statistical analysis

All the values in this study are recorded as the mean \pm standard deviation, and the statistically significant differences have been determined by unpaired student's t-test for comparisons between groups by Usage of the Statistical Package for Social Sciences SPSS (version 26.0) the program (SPSS, Chicago, IL,

USA). P-values below 0.05 have been considered statistically significant.

Results**Effect of safranal on the opacification and morphology of the lenses in the sodium selenite induced cataractogenesis**

Morphological examination of both eyes of each rat pup was done by ophthalmoscopically observation on the 30th day after birth (figure 1). All pups of rats in the cataract model group (which obtained S.C. sodium selenite injections) demonstrated an advanced opacification of the lenses (opacity grade 4). Interestingly, the study revealed that 4 out of 7 (57.1%) of rat pups pre-treated with 300mg/kg of safranal decreases the number of rat pups with lenses opacification to 2 out of 7 (28.5%). Those two pups showed moderate lenticular opacification grade 1 and grade 2; while the other five pups' lenses were appearing regular (grade 0). On the other hand, only 4 out of 7 (57.1 percent) in Group III rat pups (which provided I.P. safranal 200mg/kg injections + sodium selenite) showed lenticular opacification grade 1(n=2), grade 2 (n=1), and grade 3(n=1), while the other three pup lenses looking regular (grade 0, n=3). Moreover, all pups in Group I (which provided normal saline as control) showed full transparency of the lens (grade 0) as show in (Table 3-1).

All lenses were transparent in control group (group I). However, all lenses were developed cataract in model group (group II). No cataract occurred in the remaining lenses of the treated group as shown in (Table 1).

Table 1. Morphological examination on the opacification of rat lenses.

Group of Experimental	Pups number	The number of pups with varying grads of opacification					Number of pups with lenticular appearance
		Grads					
		0	1	2	3	4	
Group I (Control)	7	-	-	-	-	7	0
Group II (Sodium selenite)	7	7	-	-	-	-	(100%) All 7 pups
Group III (Sodium selenite + Safranal 200mg/kg)	7	3	2	1	1		4 out of 7 (57.1%)
Group IV (Sodium selenite + Safranal 300mg/kg)	7	5	1	1	-	-	2 out of 7 (28.5%)
Group V (Safranal 300mg/kg)	7	-	-	-	-	7	0

Group I rat pups received only saline; Group II rat pups received only selenite; Group III rat pups received selenite and safranal (200 mg/kg); Group IV rat pups received selenite and safranal (300 mg/kg); Group V received safranal only. The degree of opacification was graded as follows: Grade 0: was normal clear lens; Grade 1: subcapsular opacity; Grade 2: nuclear cataract; Grade 3: Strong nuclear cataract with perinuclear area opacity; Grade 4: Mature dense opacity involving the entire lenses.

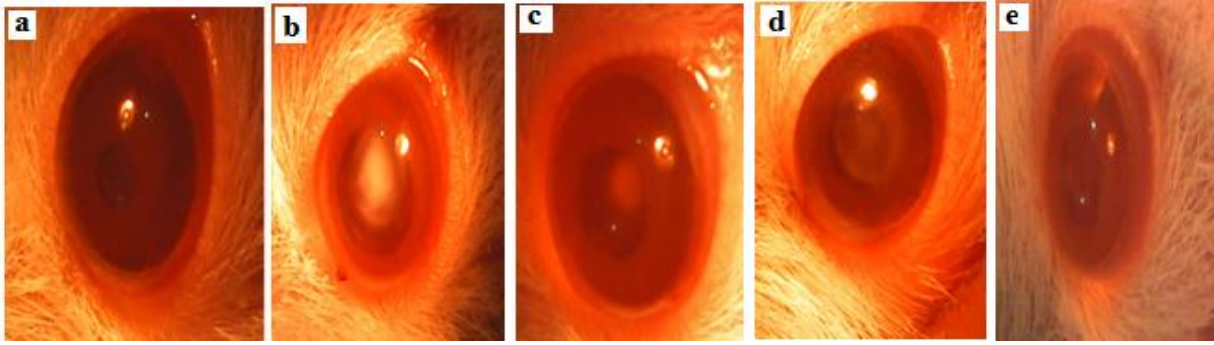


Figure 1. Figure represent pictures were taken at week 4 (1 day before sacrifice) of experiment.

Panel A: Clear lens with no identifiable opacity

Panel B: Lenses from Na_2SeO_3 group exhibited mature cataracts

Panel C: Lenses from safranal (200mg/kg) + Na_2SeO_3 group exhibited lower grade of cataracts.

Panel D: Lenses from safranal (300 mg/kg) + Na_2SeO_3 group exhibited lower grade of cataracts.

Panel E: Lenses from Safranal group exhibited similar results as that of control, with no detectable cataracts.

Effect of safranal on the GSH and MDA level in the sodium selenite induced rat's cataract model.

In this study, we measured the activities of the antioxidant enzyme GSH and MDA levels in the lenses, and the results are shown in Figures 2 A and B. Glutathione is an important nonenzymatic antioxidant in the detoxification pathway that downgrades the reactive toxic metabolites of selenite. The value of GSH in the lenses of selenite-treated group were significantly lower ($p < 0.05$) than in the normal control group. Conversely, treatment with safranal at doses of 200 mg/kg or 300 mg/kg increased the percentages of GSH significantly by 32% and 56% respectively, compared with the selenite- treated group (Figure 2A). Moreover, safranal only treatment at doses of 300 mg/kg significantly increase the level of GSH in rat's pups by 14 % compared to the control group ($p < 0.01$). (Figure 2A).

Additionally, the MDA is the general biomarker that appears during the lipid peroxidation of polyunsaturated fatty acids in the biological membrane. The results of the MDA examinations of the lenses are also shown in figure 2B. The MDA concentrations in the selenite-treated group were significantly higher than in the control group ($p < 0.001$). However, the administration of safranal significantly reduced selenite-induced lipid peroxidation in the lenses. The MDA concentrations in both groups of safranal- treated with a dose of 200 mg/kg or 300 mg/kg were at least 25% and 31 % respectively; which are highly significantly lower than they were in the selenite-treated control group ($p < 0.001$). These results suggested that the lipid peroxidation indicator induced in the lens were effectively inhibited by safranal.

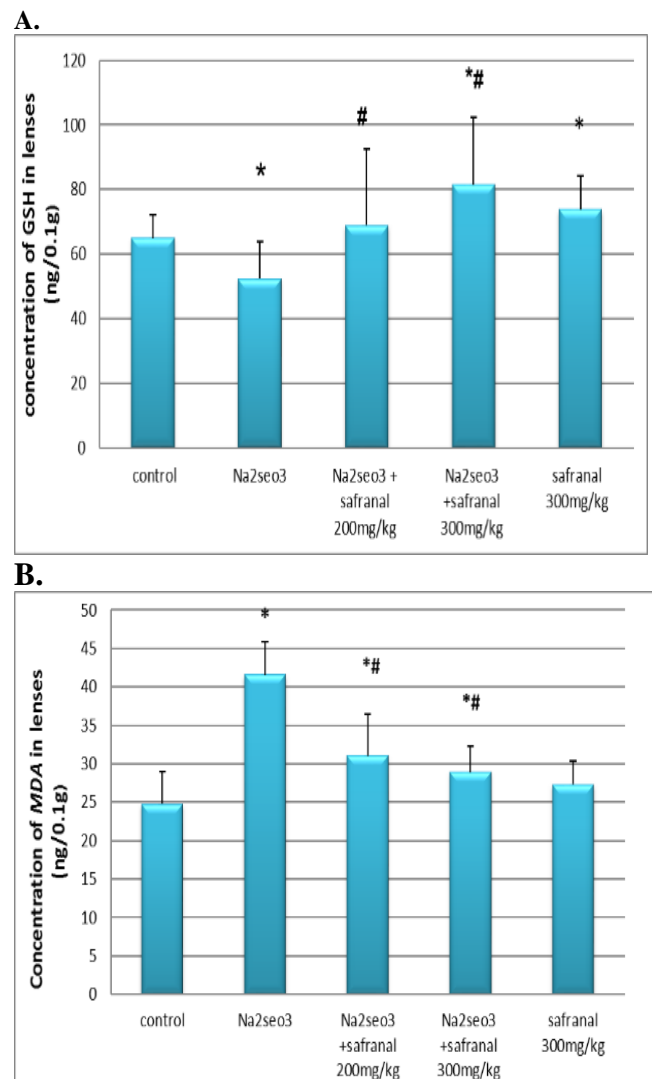


Figure 2. Effects of safranal on lens GSH and MDA in lenses of rat pups treated with sodium selenite.. (A) GSH (B) MDA. Data are presented as the mean \pm standard error of the mean for 7 rat pups. * $p < 0.05$ compare with control group; # $p < 0.05$ compare with sodium selenite-treated group.

Effect of safranal on the NRF2 level in the sodium selenite induced rat's cataract model.

Next, we studied the Nrf2 level after safranal treatment in the sodium selenite induced rat's cataract model. The Nrf2-Keap1 system is known as one of the main cellular defense mechanisms against oxidative stresses.

As shown in figure 3, The value of NRF2 in the lenses of selenite-treated control group were significantly lower ($p < 0.05$) than in the normal control group. Conversely, treatment with safranal at doses of 200 mg/kg or 300 mg/kg increased the percentages of NRF2 significantly by 18 % and 19% respectively, compared to the selenite- treated control group ($p < 0.05$). (Figure 3).

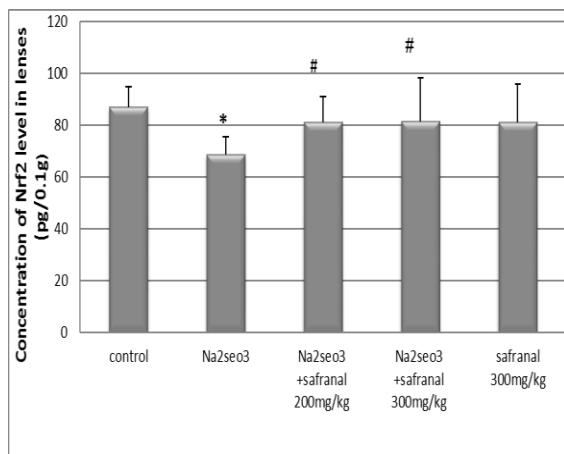


Figure 3. Effects of safranal on lens NRF2 in lenses of rat pups treated with sodium selenite. Data are presented as the mean \pm standard error of the mean for 7 rat pups. * $p < 0.05$ compare with control group; # $p < 0.05$ compare with sodium selenite-treated group.

Effect of safranal on the soluble protein level in the sodium selenite induced rat's cataract model

At the end of the experiment, the level of soluble protein was measured. As shown in figure 4, a significant decrease ($p < 0.05$) in the amount of soluble protein in selenite treated group was observed, as compared to the normal control. Furthermore, treatment with safranal (200 mg/kg or 300 mg/kg) in the sodium selenite intoxicated rat pups significantly increased ($p < 0.05$) the soluble protein content by 9% and 10 % respectively.

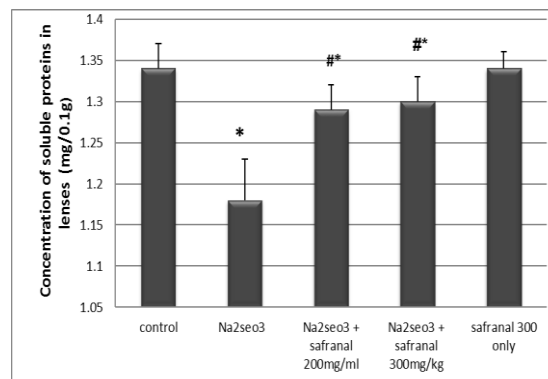


Figure 4. Effect of safranal on the soluble protein level in lenses of rat pups treated with sodium selenite.

Data are presented as the mean \pm standard error of the mean for 7 rat pups. * $p < 0.05$ compared to control group; # $p < 0.05$ compared to sodium selenite-treated group.

Discussion

The lens is extremely sensitive to attack from ROS. A number of researches indicate that antioxidant-potential medicinal herbs may protect the system against ROS toxicity. Previous findings suggest ROS is responsible for the formation of selenite cataracts⁽²⁰⁾.

The crystalline of the lens contains a huge amount of GSH, which prevents oxidant degradation of the lens and impairment in redox cycle. The level of GSH reduces in nearly all forms of cataracts. It can, therefore be proposed that GSH shows an essential impact in maintaining the clarity and consistency of the lens and this relates to both in the defense against the protein sulfhydryl groups from oxidation and it preserves cytoskeletal proteins and avoids the crosslinking of soluble crystalline^(21, 22).

Approaches have been investigated in recent years to determine the possible positive effects of safranal in ophthalmology, despite the increasingly growing literature on the neuroprotective effect of safranal in retinal degeneration through inhibiting photoreceptor cell degeneration^(23, 24), no studies have been performed to determine its potential effects on cataract development.

In this study, morphological analysis showed that the development of cataracts induced by selenite administration had been attenuated by safranal administration, indicating its potential for treatment of cataract. In addition, biochemical analyzes were carried out to support the clinical study.

The depletion of GSH in the selenite cataract is a non-enzymatic reaction of GSH with selenite forming a derivative, selenodiglutathione (GS-Se-SG), superoxide anion is produced as an intermediate in oxidation⁽²⁵⁾. Maintenance of GSH level in lens may help to maintain its defensive

ability against oxidative damage and delay the onset of cataract⁽²⁶⁾.

In the current study, the GSH content was significantly lower in lenses of rat pups that exposed to sodium selenite compared to the control. In comparison, rat pups treated with safranal showed significantly higher GSH content in their lenses than untreated pups (Figure 2). These findings show that safranal reduces selenite-induced cataractogenesis in rat pups, suggesting that safranal pretreatment maintains the lens GSH at acceptable rates and attenuates the production of superoxide and more oxidative against oxidative stress. Consistent with these data, previous studies found safranal elevates the plasma GSH level which could increase the ratio of GSH / GSSG and decline lipid peroxidation in different tissues⁽²⁷⁻³¹⁾.

In addition, cataractogenesis involves oxidative stress-mediated lipid peroxidation, because the accumulated peroxidation products caused fragmentation of the soluble lens protein and damage the structure of membrane, correlating with increased opacity of the lens^(32, 33). Accordingly, both MDA (the principal metabolite formed by lipid oxidation) and soluble proteins levels were evaluated next in the current study.

As shown in (figure 2 B), the level of MDA was significantly increased in the selenite cataract group as compared to control group. That may be related to the lipid membrane degradation induced by sodium selenite. Interestingly, in both of the safranal treated group, amount of MDA was reduced in a dose dependent manner suggesting its defensive effect against cataractogenesis. Our finding are compatible with the previous studies that stated safranal was seen as preventing both a decline in antioxidant enzyme activity and lipid peroxidation in different disease models⁽³⁴⁻³⁷⁾. Subsequently, our data indicates that safranal maintained the lens' architectural and thus avoided opacification of lenticular.

Furthermore, the soluble protein content of the lens was found to be significantly lower in rat pups that were exposed to sodium selenite compared rat pups in the control, as shown in Figure 3, because sodium selenite responsible for the formation of insoluble high molecular weight misfolded proteins that suggest an intermediate level of water-soluble conversion to water-insoluble proteins. In contrast, rat pups that treated with safranal showed significantly more soluble protein content in its lenses than selenite induced group, Pre-treatment with safranal will prevent the oxidation of these proteins and protein aggregates in a dose dependent manner, so cataract progression can be delayed⁽³⁴⁾.

Furthermore, the current study evaluate NRF2 level because it is a central factor in nuclear transcription that regulates over 200 genes related to stress which include 20 antioxidant genes.

Therefore, Nrf2 inducer may also serve as an anticataract compounds⁽³⁸⁾.

As shown in figure 3, Mean levels of Nrf2 significantly lower in rat pups that exposed to sodium selenite- group, compared to rat pups in the control. However, the safranal treatment showed a significant raise of the protein expression of Nrf2 in a dose dependent manner compared to sodium selenite induced cataract group, suggesting that safranal could maintain the activity of GSH directly or indirectly via NRF2 expression and Kelch-like ECH-associated protein 1(Keap) modification in sodium selenite-damaged lens.

Previous findings from previous research found that safranal defends against rotenone-induced neurotoxicity via Nrf2 signaling pathway and assumed that safranal may serve as a potent therapeutic drug in the treatment Parkinson's disease⁽³⁹⁾. Accordingly, the current study shows that Nrf2 induced by safranal helps maintain glutathione levels, which act as a buffer to accumulate reactive oxygen species during the unfolded protein response.

Conclusion

This study revealed that safranal possess a potent anticataractogenic effect, which may be due to its excellent antioxidant ability. This preliminary analysis is promising, however further researches are needed to evaluate if safranal treatment could have a similar promising effects on the cataractogenesis in humans.

References

1. Rowan, S., Bejarano, E., & Taylor, A. (2018). Mechanistic targeting of advanced glycation end-products in age-related diseases. *Biochimica et biophysica acta. Molecular basis of disease*, 1864(12), 3631–3643.
2. Nartey A. The Pathophysiology of Cataract and Major Interventions to Retarding Its Progression: A Mini Review. *Adv Ophthalmol Vis Syst.* 2017;6(3):4–7.
3. Salm M, Belsky D, Sloan FA. Trends in cost of major eye diseases to Medicare, 1991 to 2000. *Am J Ophthalmol.* 2006;142(6):976–82.
4. C L, Afshari NA. Ever-evolving technological advances in cataract surgery: can perfection be achieved? *Curr Opin Ophthalmol.* 2012;23(1):1–2.
5. Brian G, Taylor H. Cataract blindness: challenges for the 21st century. *Bull World Health Organ.* 2001;79:249–56.
6. Tang H, Yang L. Activation of the unfolded protein response in aged human lenses. *Mol Med Rep.* 2015;12(1):389–93.
7. Sagdik HM, Ucar F, Tetikoglu M, Aktas S, Ozcura F, Kocak H, et al. Investigation of dynamic thiol–disulphide homeostasis in age-related cataract patients with a novel and

- automated assay. *Int Ophthalmol.* 2018;38(2):655–61.
8. Lou MF. Redox regulation in the lens. *Prog Retin Eye Res.* 2003;22(5):657–82.
 9. Shichi H. Cataract formation and prevention. *Expert Opin Investig Drugs.* 2004;13(6):691–701.
 10. Oštádalová I, Babický A, Obenberger J. Cataract induced by administration of a single dose of sodium selenite to suckling rats. *Experientia.* 1978;34(2):222–3.
 11. Shearer TR, Ma H, Fukiage C, Azuma M. Selenite nuclear cataract: review of the model. *Mol Vis.* 1997;3(8).
 12. Palsamy P, Bidasee KR, Shinohara T. Selenite cataracts: activation of endoplasmic reticulum stress and loss of Nrf2/Keap1-dependent stress protection. *Biochim Biophys Acta (BBA)-Molecular Basis Dis.* 2014;1842(9):1794–805.
 13. Seko Y, Saito Y, Kitahara J, Imura N. Active oxygen generation by the reaction of selenite with reduced glutathione in vitro. In: *Selenium in biology and medicine.* Springer; 1989. p. 70–73.
 14. Devamanoharan PS, Henein M, Morris S, Ramachandran S, Richards RD, Varma SD. Prevention of selenite cataract by vitamin C. *Exp Eye Res.* 1991;52(5):563–568.
 15. Abdullaev FI, Espinosa-Aguirre JJ. Biomedical properties of saffron and its potential use in cancer therapy and chemoprevention trials. *Cancer Detect Prev.* 2004;28(6):426–432.
 16. Bolhassani A. *Bioactive Components of Saffron and Their Pharmacological Properties [Internet].* 1st ed. Vol. 58, *Studies in Natural Products Chemistry.* Elsevier B.V.; 2018. 289–311 p. Available from: <http://dx.doi.org/10.1016/B978-0-444-64056-7.00010-6>
 17. Zhang C, Ma J, Fan L, Zou Y, Dang X, Wang K, et al. Neuroprotective effects of safranal in a rat model of traumatic injury to the spinal cord by anti-apoptotic, anti-inflammatory and edema-attenuating. *Tissue Cell.* 2015;47(3):291–300.
 18. Papandreou MA, Tsachaki M, Efthimiopoulos S, Cordopatis P, Lamari FN, Margarit M. Memory enhancing effects of saffron in aged mice are correlated with antioxidant protection. *Behav Brain Res.* 2011;219(2):197–204.
 19. Muranov K, Poliansky N, Winkler R, Rieger G, Schmut O, Horwath-Winter J. Protection by iodide of lens from selenite-induced cataract. *Graefe's Arch Clin Exp Ophthalmol.* 2004;42(2):146–151.
 20. Tsai, C. F., Wu, J. Y., & Hsu, Y. W. (2019). Protective Effects of Rosmarinic Acid against Selenite-Induced Cataract and Oxidative Damage in Rats. *International journal of medical sciences,* 16(5), 729–740.
 21. Reddy VN. Glutathione and its function in the lens-An overview. *Exp Eye Res.* 1990;50(6):771–778.
 22. Harding JJ. Free and protein-bound glutathione in normal and cataractous human lenses. *Biochem J.* 1970;117(5):957–960.
 23. Fernández-Sánchez L, Lax P, Esquivia G, Martín-Nieto J, Pinilla I, Cuenca N. Safranal, a saffron constituent, attenuates retinal degeneration in P23H rats. *PLoS One.* 2012;7(8):e43074.
 24. Fernández-Sánchez L, Lax P, Noailles A, Angulo A, Maneu V, Cuenca N. Natural compounds from saffron and bear bile prevent vision loss and retinal degeneration. *Molecules.* 2015;20(8):13875–13893.
 25. Cantin AM, White TB, Cross CE, Forman HJ, Sokol RJ, Borowitz D. Antioxidants in cystic fibrosis: conclusions from the CF antioxidant workshop, Bethesda, Maryland, November 11–12, 2003. *Free Radic Biol Med.* 2007;42(1):15–31.
 26. Lim, V., Schneider, E., Wu, H., & Pang, I. H. (2018). Cataract Preventive Role of Isolated Phytoconstituents: Findings from a Decade of Research. *Nutrients,* 10(11), 1580.
 27. Samarghandian S, Afshari R, Sadati A. Evaluation of lung and bronchoalveolar lavage fluid oxidative stress indices for assessing the preventing effects of safranal on respiratory distress in diabetic rats. Vol. 2014, *The Scientific World Journal.* 2014.
 28. Samarghandian S, Azimi-Nezhad M, Samini F. Preventive effect of safranal against oxidative damage in aged male rat brain. *Exp Anim.* 2015;64(1):65–71.
 29. van den Born I. Safranal, a constituent of *Crocus sativus* (saffron), attenuated cerebral ischemia induced oxidative damage in rat hippocampus. *J Pharm Pharm Sci.* 2005;8(3):394–399.
 30. Hosseinzadeh H, Modaghegh MH, Saffari Z. *Crocus sativus* L.(Saffron) extract and its active constituents (crocin and safranal) on ischemia-reperfusion in rat skeletal muscle. *Evidence-Based Complement Altern Med.* 2009;6(3):343–350.
 31. Kianbakht S, MOZAFARI K. Effects of saffron and its active constituents, crocin and safranal, on prevention of indomethacin induced gastric ulcers in diabetic and nondiabetic rats. 2009;
 32. Qanungo S, Sen A, Mukherjea M. Antioxidant status and lipid peroxidation in human fetoplacental unit. *Clin Chim acta.* 1999;285(1–2):1–12.
 33. Siddhuraju P, Mohan PS, Becker K. Studies on the antioxidant activity of Indian Laburnum (*Cassia fistula* L.): a preliminary assessment of

- crude extracts from stem bark, leaves, flowers and fruit pulp. *Food Chem.* 2002;79(1):61–67.
34. Makri OE, Ferlemi A-V, Lamari FN, Georgakopoulos CD. Saffron administration prevents selenite-induced cataractogenesis. *Mol Vis.* 2013;19:1188.
35. Farahmand SK, Samini F, Samini M, Samarghandian S. Safranal ameliorates antioxidant enzymes and suppresses lipid peroxidation and nitric oxide formation in aged male rat liver. *Biogerontology.* 2013;14(1):63–71.
36. Hosseinzadeh H, Sadeghnia HR. Safranal, a constituent of *Crocus sativus* (saffron), attenuated cerebral ischemia induced oxidative damage in rat hippocampus. *J Pharm Pharm Sci.* 2005;8(3):394–399.
37. Samarghandian S, Borji A, Delkhosh MB, Samini F. Safranal treatment improves hyperglycemia, hyperlipidemia and oxidative stress in streptozotocin-induced diabetic rats. *J Pharm Pharm Sci.* 2013;16(2):352–362.
38. Santos CXC, Tanaka LY, Wosniak J, Laurindo FRM. Mechanisms and implications of reactive oxygen species generation during the unfolded protein response: roles of endoplasmic reticulum oxidoreductases, mitochondrial electron transport, and NADPH oxidase. *Antioxid Redox Signal.* 2009;11(10):2409–2427.
39. Pan PK, Qiao LY, Wen XN. Safranal prevents rotenone-induced oxidative stress and apoptosis in an in vitro model of Parkinson's disease through regulating Keap1/Nrf2 signaling pathway. *Cell Mol Biol.* 2016;62(14):11–17.

