

Surgery of the Dulaa in the Camel (*Camelus dromedarius*)

Ramadan O. Ramadan

Department of Clinical Studies, College of Veterinary Medicine and Animal Resources,
King Faisal University, PO Box 1757, Kingdom of Saudi Arabia

جراحة اللهاة في الجمال

رمضان عمر رمضان

الخلاصة: أجريت هذه الدراسة على 45 من الجمال التي أدخلت للمستشفى البيطري التعليمي لجامعة الملك فيصل بسبب آفة مرضية في اللهاة. وكان سبب التردد للمستشفى إما عدم القدرة على تناول الطعام أو لصعوبة البلع وقد خضعت هذه الجمال للفحص الإكلينيكي ثم استخدام الأشعة السينية في بعض الحالات. أوضحت الدراسة أن 24 جملاً (53.33%) لا تستطيع الهدير أو طرد الهدارة خارج تجويف الفم. كما كانت تشكو من انتفاخ منطقة الحنجرة. وكانت هدارة 15 من الجمال (33.33%) خارج الفم ولا تستطيع الجمال إعادتها لمكانها الطبيعي وأزيلت لها أربعة من الجمال (18.9%) بناء على رغبة صاحب الحيوان وما تبقى (2) من الفحول (4.44%) تم استئصال الهدارة بواسطة بيطار وطلب صاحب الفحل إعادة الجراحة لإكمال العلاج. وتم علاج الجمال حسب نوع المرض. ففي حالة تلبك اللهاة تم تهدئة الحيوان بمهدئ الرميون ثم فتح الفم باستخدام عكامة (فاحة فم) مناسبة ومن ثم إدخال اليد داخل فم الجمل وتفريغ الهدارة ثم إزالتها حسب رغبة صاحب البعير. أما عندما كانت الهدارة موجودة خارج الفم فقد تمكننا من تهدئة الجمل ثم تسريب البنج الموضعي عند قاعدة اللهاة ثم إزالتها. وإذا تعذر ذلك تم تخدير الجمل ثم إدخال الأنبوب الرغامي داخل القصبة الهوائية. وفي عملية جراحية أخرى في نفس اليوم تم شق الجلد بين فرعي الفك السفلي ثم استئصال اللهاة من قاعدتها. وأعقب العملية الجراحية حقن الحيوان بمضاد حيوي عريض الطيف وتغذية الجمل بسوائل ومواد يسهل هضمها. وتنوعت إصابات اللهاة الأقل خطورة لتشمل الورم، والقرحة، والقيلة الدموية، والجروح، وتلبك أو تهتك اللهاة أو وجود خراج داخلها. وقد تم دراسة رأس ورقبة جمل نافق بالرنين المغناطيسي للاستدلال على المرض بالنواحي التشريحية ومنظر الرقبة تحت هذه التقنية الحديثة.

كلمات مفتاحية: اللهاة، سقف الحلق، جراحة جمال ذات النام الواحد - الأشعة المقطعية

ABSTRACT: The present study was carried out on 45 native adult dromedary camels suffering from disorders of the dulaa. Clinical signs were those of dysphagia and or dyspnoea. Twenty-four camels (53.33%) were unable to inflate or extrude their dulaas. These signs were associated with pharyngeal swelling. Therefore the animals were examined radiographically. Fifteen (33.33%) camels suffered from collapsed and persistent protrusion of the dulaas. Four (8.9%) camels had previous episodes of dysfunction of the dulaa and the owner requested elective surgical excision. The remaining 2 (4.44%) animals had previous excision by healers and developed granulation tissue. Surgical management was achieved after light sedation using xylazine (2% Rompun, Bayer) supplemented with local infiltration analgesia or followed by induction of anaesthesia using ketamine hydrochloride (Ketamidore). The operations were carried out either through the oral cavity or following a pharyngostomy incision at the inter-mandibular region. In the latter instances, temporary tracheotomy was needed. The prevalent surgical affections were impaction with food material associated with ulcer or echymosis or abscesses. Less severe maladies were those of persistent protrusion accompanied with edema, haematoma, lacerations, small foci of abscesses and gangrene. The prognosis was favourable. The study included surgical anatomy, magnetic resonance imaging (MRI), as well as radiography of the dulaa in health and disease.

Keywords: Dulaa, soft palate, dromedary camel surgery, MRI.

Introduction

The dulaa is a unique diverticulum on the ventro-rostral part of the soft palate of the dromedary camel (Hegazi, 1949; Mukasa-Mugerwa, 1981). It is extruded from the bucal cavity during the rut or under excitation (Arnautovic and Abdel Magid, 1974; Wilson, 1988). A small minority of camels do not protrude the dulaa throughout their lifetime. The presence of dulaa outside the bucal cavity makes it

vulnerable to trauma (Cross, 1917). Several reports describe the affections of the dulaa in Arabian camels (Bhargava, 1973; Vashishta *et al.*, 1980; Gahlot, 1993; Ramadan, 1994; Barvalia *et al.*, 1998; Rollefson *et al.*, 2001; Gahlot *et al.*, 2007). These reports have shown that minor ulcerations with subsequent flaccidity of the dulaa may lead to its impaction with feed (Ramadan and Abdin-Bey, 1987; Bolbol and

Shazly, 1992). Furthermore, neglected injuries may lead to gangrene of the organ with subsequent dysphagia and dyspnoea (Gahlot *et al.*, 1988). Despite the importance of the dulaa, its radiographic findings, and surgical management is rarely documented (Ramadan, 1990; Ramadan, 1994).

This review is intended to provide details of the clinical appearance of the dulaa and focus on its surgical management.

Materials and Methods

Clinical Animals

A prospective study was performed of camels admitted to the Veterinary Teaching Hospital. Each camel was examined clinically and radiographs were taken on the lateral view whenever needed.

Forty-five animals were subjected to surgical interference as follows: Group I: (=4; 8.90%) - Elective excision of dulaa; Group II: (=2; 4.33%) - Re-Excision of remnant of dulaa because the healer was unable to achieve complete excision; Group III: (=15; 33.33%) - Animal was unable to return the dulaa back into the mouth. The dulaa was edematous, engorged, showing signs of haematoma and one case contained remnant of food particle. It was thus hanging at mouth commissure (Fig. 1); and Group IV (=24; 53.33%) - The animals were showing discomfort when swallowing; dysphagia, dyspnea were present and the animals were unable to extrude the dulaa (Fig 2). The reasons were lacerated wounds (5), gangrene (4), ulcers (7), abscesses (2) or impaction with feed material (6).

Cadaver

The head and neck of a 13-year-old male camel, which died for reasons not related with dulaa, was disarticulated at c3-c4 and subjected to MRI. Three dimensional pulse sequence were performed (T1-w; T2-w ; STIR) using a human 1.5 Tesla MR scanner. The stored plates were studied for understanding the imaging anatomy.

Surgical Technique

Elective excision

The camel was secured on the sternal position. It was then sedated using 2% xylazine hydrochloride given intravenously at the dose of 0.2 mg/kg body weight. A further injection of ketamine hydrochloride was given at the dose of 0.5 mg/kg body weight. The mouth was widely opened using a Varnell mouth gag while the tongue was pulled through the interdental space. An assistant introduced his hand into the mouth in a cone manner to grasp the dulaa. Once in position, it was fixed with a long thread of non-absorbable suture material (Perlon no: 7 metric) to prevent it from accidental slipping. The dulaa was pulled as far as possible. The blood vessels were double clamped and cut between the clamps. Further pairs of haemostats were applied across the dulaa and




Figure 1. A camel protruding an impacted dulaa.

the organ was cut between them using a pair of surgical scissors. The stump of the dulaa was sutured using a No; 5 metric polyglactin 910 on atraumatic needle. The animal received a local and a systemic course of broad-spectrum antibiotics as well as a course of Vitamin K3. The owner was advised to feed the animal 5 liters of milk mixed with honey for one week.



Figure 2. A camel suffering from impaction of dulaa, note distended pharynx and extension of neck.

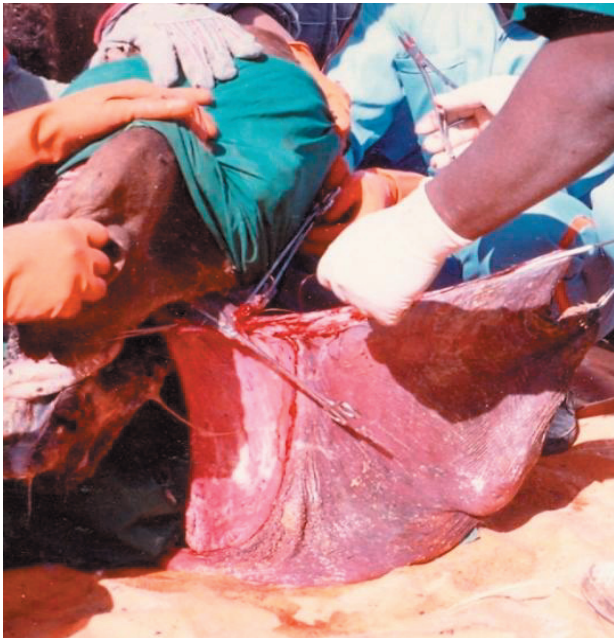

Figure 3. Excision of extruded dulaa.

Excision of a dulaa hanging between mouth commissure

The animal was secured in the sternal position and sedated with 2% xylazine hydrochloride (0.2 mg/kg body weight) together with 10% ketamine hydrochloride at the dose of 1 mg/kg body weight given intravenously. The dulaa was pulled as far as possible (Fig. 3). Local analgesic (2% lignocaine hydrochloride) was also injected at the base of the organ. The operation was completed as for the elective technique described above.

Management of the Dulaa which Remains Inside the Pharynx

Evacuation followed by excision of the dulaa

The animal was sedated and provision of a temporary tracheotomy was undertaken by preparing the ventral

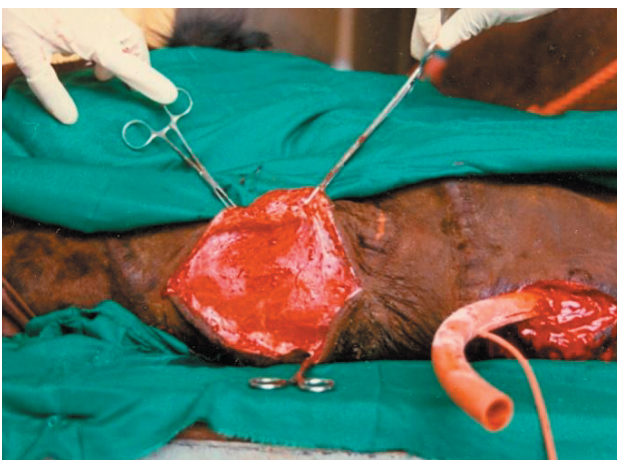

Figure 4. Ventral part of a camel pharynx during surgery.

part of the neck for an aseptic operation. A hand was gently introduced into the mouth as for elective procedure. The dulaa was pulled out and cleaned off any debris, thereafter resection was undertaken according to owner's desire. When it was not possible to pull the dulaa outside the mouth, the animal was rolled to its side for pharyngostomy.

Excision of the dulaa through the ventral part of the pharynx

The animal was lightly sedated and the ventral part of the neck was approached aseptically. A 10 cm long skin incision was made at the level of the third cervical vertebrae. The incision was deepened by blunt dissection to expose the ventral cervical muscles. The fused bellies of the sternothyrohyoideus muscle were separated. The trachea was pulled to the operative field and the annular ligament was incised. A temporary tracheotomy tube or a suitable endotracheal tube was inserted down the trachea.

Now the ventral pharynx was prepared for an aseptic operation. A 15 cm long skin incision was made at the mid inter-mandibular space starting from the cricoids cartilage rostrally. The incision was continued below the belly of the left sternothyrohyoideus. The muscle was retracted dorsally. The pharynx was thus entered. Care was exercised to avoid damaging the blood vessels. The hand was pushed rostrally to grasp the dulaa. The latter was primarily evacuated before resection (4 animals) or pulled out through the wound with its content and resected (Figs. 4 and 5).

Results and Discussion

Of primary interest in this study is the use of radiography for detection of pharyngeal lesions when the dulaa cannot be extruded by the animal. Radiographs illustrate the larynx, proximal trachea, esophagus, the naso and oropharynx but are unable to delineate a normal dulaa or a dulaa showing non-opaque lesion (Figs. 6 and 7). Under such a situation, the dulaa is collapsed and covered by the

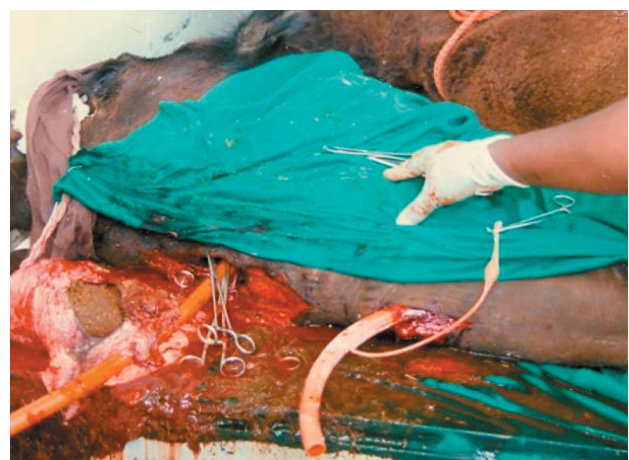

Figure 5. Ventral part of a camel pharynx after resection of dulaa.

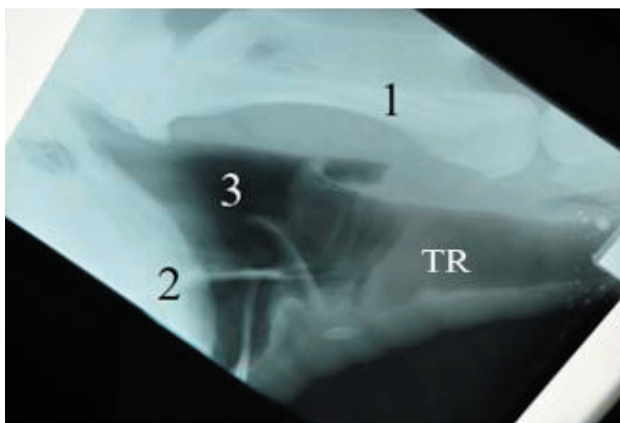


Figure 6. Lateral radiograph of the pharynx of a camel normal 1= 2nd Cervical vertebra; 2= end of dulaa; 3= pharynx.

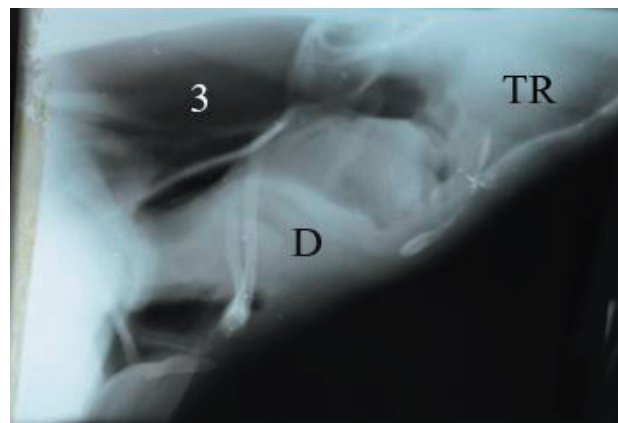


Figure 7. Lateral radiograph of a camel with impaction of dulaa. Note radio-opacity cranial to larynx (D) and trachea (TR).

vertical ramus of the mandible. Also subtle radiolucent lesions predisposing to dysphagia could not be diagnosed with certainty. However, when the dulaa was impacted with feed particles its size and density increases. It pushed caudally to press against the epiglottis thus interfering with breathing.

Elective resection of the normal dulaa is not infrequently carried out by healers. Their technique is fraught with complications such as hemorrhage, infection or fibrous hyperplasia due to incomplete resection. The latter situation gave us an opportunity to re-excite the dulaa which was responsible for dysphagia and respiratory distress.

The present investigation provides evidence that it is possible to treat affections of the dulaa through two surgical routes (the intra-oral and pharyngostomy incision). The intra-oral method is simple, less time consuming and does not subject the animal to the risk of general anaesthesia

However, it may be applied to a severely impacted or indurate dulaa. Simple amputation has been attempted by some authors (M'zah *et al.*, 1993; Ramadan, 1994). The main complication of the conventional surgical resection is post-operative bleeding and possible infection (Gahlot, 1988). Surgical resection showed drastic progress over the years and recently thermocautery provides quick and efficient amputation of the organ (Reece and Chawla, 2001).

Persistent protrusion of the dulaa in most instances occur on its own (Cross, 1917; Ali, 1993; Gahlot, 1993), but in the present study, it was associated with impaction in one animal and with bilateral fracture of the mandible in two other camels.

There have been questions raised concerning the inability of some camels to extrude their dulaa. In two animals studied by the present author, the dulaas were shorter and less elastic than normal. This may be a congenital anomaly.

In the present study, disorders of the dulaa occur between the ages of 4-13 years (average 8 years). Other authors reported that injuries should never occur in camels less than 9 years (Dioli *et al.*, 1992). Impaction, ulcers and abscess were observed more commonly in older animals.

MRI is a useful modality, providing excellent image contrast and resolution that allows excellent visualization of anatomic details (Fig. 8). To date MRI studies are restricted to cadavers or newborn camels (Arincebia *et al.*, 2005).

Acknowledgments

Thanks to my colleagues and house surgeons at the Veterinary Teaching Hospital, King Faisal University for their help during the study.

References

Ali, M.A., A.S. Saleh, and H.A. Yousef. 1993. Unexpected soft palate hanging in a dromedary. *Assiut. Veterinary Medical Journal* 28:272-276.

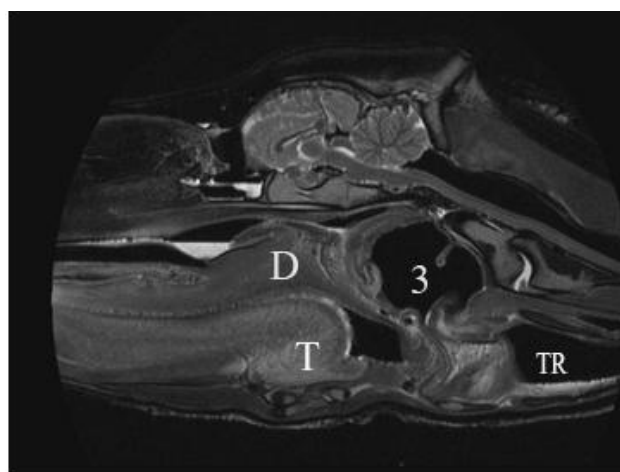


Figure 8. MRI image of normal pharynx T2W/TSE/SAG TR: 5000 TE: 100 TSE Factor: 17 Note Dulaa (D), Tongue (T), Pharynx (3), Trachea (TR).

- Arencibia, A., M.A. Riverol, F. Gil, J.A. Rami' rez, J.A. Corebera, G. Rami' rez, and J.M. Va' zquez. 2005. Anatomy of the cranocephalic structures of the camel (*Camelus dromedarius*) by imaging technique Magnetic Resonance Imaging Study. *Anatomia Histologia Embryologia* 34:52-55.
- Arnautovic, I. and A-M. Abdel Magid. 1974. Anatomy and mechanism of distension of the dulaa of the one humped camel. *Acta Anatomica* 88:115-124.
- Barvalia, D.R., S.C. Choudhay, V. Singh, and S.C. Ojha. 1998. Soft palate fibroma in a camel (*Camelus dromedarius*). *Journal Camel Practice and Research* 5:313.
- Bhargava, A.K. 1973. Infection of soft palate in camels. *Indian Veterinary Journal* 50:1213-1214.
- Bolbol A.E. and M.D. El Shazly. 1992. Impaction of the dulaa *Palatine diverticulum* in the dromedary. In: *Proceedings of the 5th Scientific Congress Faculty*, 193-202. Veterinary Medicine. Assiut University.
- Cross, H.E. 1917. *The Camel and its Diseases*. Steel, Baillierand Cox, London.
- Dioli, M., H.J. Schwartz, and R. Stimmelmayer. 1992. In: *The One-humped Camel in Africa*. Ed; H.J. Schwartz and M. Dioli (Editors), p75. Weikersheim: Margraf, Germany.
- Gahlot, T.K., D.S. Chouhan, and R.J. Choudhary. 1988. Soft palate gangrene in camels (*Camelus dromedarius*). *Indian Veterinary Journal* 65:527-528.
- Gahlot, T. K. 1993. Surgical affections of soft palate in camels. *Camel Newsletter* 10:28-29.
- Gahlot, T.K., P.R. Dudi, N.R. Purohit, C.K. Sharma, P. Bishnoi, and S. Purohit. 2007. Surgeries of head and neck region of dromedary camel in India. In: *Proceedings of International Camel Conference*. Bikaner, 16-17 February 2007.
- Hegazi, A.H. 1949. The soft palate of the camel. *British Veterinary Journal* 105:325-328.
- M' zah, A., M.S. Ben Said, A. Matoussi, and M.K. Bayoumi. 1993. Ablation of the soft palate in a male dromedary. *Revue d' Elevageet de Medecine Veterinaire des Pays Tropiceaux* 144:885-890.
- Mukasa-Mugerwa, E. 1981. The camel (*Camelus dromedarius*), a bibliographical review. International Livestock Centre of Africa, Ethiopia, p17.
- Ramadan, R.O. 1990. Tracheotomy in camels. In: *Proceedings of the 4th Scientific Congress*. Faculty Veterinary Medicine. Assiut University, 2:339-343.
- Ramadan, R.O. 1994. Surgery and radiology of the dromedary camel. King Faisal University.
- Ramadan, R.O. and M.R. Ahdin-Bey. 1987. Impaction of the distensible part of the soft palate (dulaa) in the camel. *Veterinary Medical Revue* 1:72-74.
- Reece, J.E. and S.K. Chawla. 2001. Prolapse of the soft palate in a male Arabian camel (*Camelus dromedarius*). *Veterinary Record* 21:656-657.
- Rollefson, I-K., P. Mundy, and E. Mathias. 2001. A Field Manual of Camel Diseases. ITDG Publishing, London, UK.
- Vashishta, M.S., R.P. Singh, and C. Kala. 1980. A rare abscess on pharyngeal surface of a camel. *Livestock Advisor* 5:68.
- Wilson, R.T. 1988. *The Camel*. London Longman House, Essex, U.K.

Received: March 16, 2013

Accepted: December 3, 2013