

Assessment of Cox2 and CMV in patients with chronic HCV infection

Heba F. Hassan,^a Basim M. Khashman,^b Omer A. Abdul Qader,^c Alaa W. Izzat^d

^aDepartment of Basic Sciences. College of Dentistry. University of Baghdad, Iraq.

^bIraqi national cancer research center (INCRC), University of Baghdad, Iraq.

^cKulliyyah of Dentistry oral medicine and oral pathology Department, International Islamic University Malaysia, Malaysia.

^dCollege of Dentistry, University of Baghdad, Iraq.

Correspondence to Heba F. Hassan (email: heba_micro08@yahoo.com).

(Submitted: 19 December 2017 – Revised version received: 11 January 2017 – Accepted: 20 February 2017 – Published online: 27 March 2017)

Objective This study was established to determine the expression of COX-2 and CMV in patients with chronic C infection.
Methods A total of 30 formalin-fixed of paraffin-embedded liver samples obtained from patients with chronic hepatitis C infection. In addition, 30 apparently normal liver autopsies were used as control group used for immunohistochemistry technique (IHC) to study the expression of cyclooxygenase (COX-2) and cytomegalovirus (CMV) in these samples.
Results In current study, the results of expression of COX-2 were found in 25 cases (83.3%) of chronic HCV were strongly positive with a significant increase at $P < 0.001$, while the result of CMV expression was detected as brown cytoplasmic membranous staining of cells with positive CMV expression demonstrated in 21 (70.0%) out of 30 cases of chronic HCV infection cases. All control groups were negative for the expression of COX-2 and CMV.
Conclusion This study concludes that COX-2 and CMV participates in the pathogenesis of chronic HCV infection.
Keywords chronic HCV infection, cyclooxygenase (COX-2), cytomegalovirus (CMV)

Introduction

Hepatitis C virus (HCV) is a serious global health trouble that affects 130-170 million people worldwide.^{1,2} Data from WHO estimate that 3–4 million individuals are infected with HCV every year.³ Its complex disease persistent infection leading to cirrhosis, fibrosis, hepatocellular carcinoma (HCC) and liver transplantation.⁴ HCV is classified as Flaviviridae family and genus Hepacivirus. A single-stranded positive-sense RNA genome enveloped virus with a ~ 9.6 kb.⁵ There are seven genotypes of HCV, each with many subtypes depend on antigenic variability and geographical differences in distribution, transmission, disease progression and respond differently to treatment.⁶ HCV genome encodes large polyprotein of 3010 amino acids which is processed co-translationally into three structural and seven nonstructural (NS) polypeptides.^{7,8} Cyclooxygenase (COX) is the rate limiting enzymes in the production of prostanoids from arachidonic acid.⁹ There are two COX isoforms present in human that share more than 60% identity at the amino acid level identified. COX-1 is constitutively expressed both in normal cell types and in cirrhotic livers and is involved in the homeostatic functions of PGs.¹⁰ Whereas COX-2 is induced by different stimuli such as hormones, cytokines, growth factor and mitogens, COX-2 was not seen in normal liver, but showed de novo synthesis and pronounced upregulation in liver cirrhosis.¹¹ High COX-2 expression has been reported to be relationship with liver damage and the liver cell pathologies such as the degree of inflammation, the viral infections, the development of fibrosis and HCC in human.^{12,13} This was illustrated by the effect of COX-2 on the secretion of matrix metalloproteinases (MMPs) by liver cells that be implicated in carcinogenesis and fibrinogenesis occurring in HCV-induced liver disease.¹⁴ CMV is the largest member of the virus family Herpesviridae belong to human herpes virus-5 and is ubiquitous virus that infects most all humans at some time in their lifetime,¹⁵ is a double-strand DNA virus 235-kb that encodes more than 200 proteins.¹⁶ Approximately 70-100% of the world's populations are carriers

to this virus,¹⁷ the prevalence of infection are estimated 100% in Asia and Africa, and approximately 80% in USA and Europe depending on socioeconomic status.¹⁸ It has become the most common cause of severe disease with high morbidity and mortality in immune compromised individuals.¹⁹ Primary human CMV infection is occurred in early life and the virus persistence in a latent state, and reactivation may occur later in life.²⁰ Therefore, reactivation of the virus is due to periods of down-regulation of the immune system, such as illness-related stress drug treatment, or during on-going activation of the immune system such as infection with other pathogens and inflammatory diseases.²¹ CMV can infect all organ and tissues, but manifestations of organ involvement generally include symptoms from the liver, the intestine, CNS and lung.²²

Materials and Methods

Patients and control samples: This study was carried on 30 liver biopsy specimens that diagnosed with chronic HCV infection in 22 males and 8 females were collected at random from the pathology archive at the Liver and Digestive System Technical Hospital in Baghdad during the period from February 2010 to November 2012. The liver biopsy samples were estimated by a single pathologist, and the stage of fibrosis was depend on Ishak scores fibrosis from 0 to 6 where a score of 2 is defined as fibrous expansion of most portal areas, with or without short fibrous septa; three fibrous expansion of most portal areas with occasional portal-to-portal bridging; four fibrous expansion of most portal areas with marked bridging; five incomplete cirrhosis and 6 definite cirrhosis.²³ All patients were confirmed to HCV infection by Elisa test. Control group of liver specimens were obtained from 30 autopsies (21 males and 9 females). From each tissue block, a series of 4 μ m sections were cut and stained with hematoxylin and eosin for pathological evaluation and immune histochemistry.

Immunohistochemical Staining

The antibodies used in this study included anti-COX-2 antibody and anti-CMV antibody. The sections were dewaxed in xylene then rehydrated in graded alcohol. Endogenous peroxidase activity and non-specific binding were blocked by incubation with 3% hydrogen peroxide and protein block, respectively. Peroxidase blocking reagent for 10 min. Slides were pre-treated in microwave oven in citrate buffer (pH 6). Subsequently, slides were incubated with mouse monoclonal anti-COX-2 and anti-CMV antibody and slides were then incubated sequentially with primary antibodies for 1 hour at 37°C and secondary antibody for 10 minutes at room temperature followed by incubation with the Streptavidine-HRP antibodies for 10 minutes at 37°C. Diaminobenzidinehydrochloride (DAB) was used as the chromogen to visualize peroxidase activity. The sections were counterstained with hematoxylin and overlaid with cover slips.

Assessment of Immunohistochemistry Results

Positive reading was detected when the cells display a brown cytoplasmic pigmentation of immunostaining, while negative reading was detected by the absence of immunostaining. Assessment of anti-Cox2 antibody and anti-CMV antibody Immunoreactivity. The scoring system of immunostaining antibodies was assessed the positively stained cells, which counted at five representative random fields (40X) by using light microscope, the scoring of the antibodies with the criteria combined intensity with the rate of positive cell. The percentage of positive cells for the protein of interest were scored as 1 = (0–25%), 2 = (26–50%), 3 = (51–75%) and 4 = (76–100%)[8].

Statistical Analysis: Evaluation of the statistical significance of the data was performed by using the *t*-test and Chi-square test.

Results

Distribution of Patients and Control Group According to Gender

Distribution of patients and control group according to gender was listed in Table 1. The results of this study showed that chronic HCV infection in the male was more predominance among patients, where 22 males (73.4%) and 8 females (26.6%) out of total cases. There was no statistically significant difference ($p > 0.05$) in gender between both studied groups. The mean age of patients was 44.9 years compared with control group was 46.9.

Results of Immunohistochemical

COX2 Expression

The current study showed strong brown staining was seen in most cells with positive COX2 expression by Immunohistochemical (IHC) staining was found in 25 cases (83.3%) of chronic HCV were strongly positive with a significant increase at $P < 0.001$ (Table 2, Fig. 1). On the other hand there was no positive result among control group.

CMV Expression

The result of this study showed CMV expression was detected as brown cytoplasmic membranous staining of cells with

positive CMV expression by Immunohistochemical (IHC) staining demonstrated in 21 (70.0%) out of 30 cases of chronic HCV infection cases. There was highly significant statistically differences found between the patients and healthy control group at $P < 0.001$ (Table 3 and Fig. 2).

Discussion

The present study showed that high over expression of COX-2 (83.3%) in liver tissue in patients with chronic HCV infection with different stage of fibrosis. COX-2 is concerned in anti-apoptosis, inflammation and carcinogenesis. This result agreed with Nunez et al.²⁴ was found COX-2 is over expressed in the

Table 1. Distribution of patients and control group according to gender

			Studied groups		Total
			Chronic HCV	Control	
Gender type	Male	Count	22	21	43
		%	73.4%	70.0%	71.7%
	Female	Count	8	9	17
		%	26.6%	30.0%	28.3%
Total	Count	30	30	60	
	%	100.0%	100.0%	100.0%	
Mean of age			44.9	46.9	
Range of age			14-65	29-68	
Median of age			45.5	42.5	
P value			0.984 ^{NS}		

Table 2. Expression of COX2 in patients with chronic HCV infection and healthy control group

			Studied groups	
			Chronic HCV	Control
COX2	Negative	Count	5	30
		%	16.7%	100.0%
	Positive	Count	25	0
		%	83.3%	0.0%
Total	Count	30	10	
	%	100.0%	100.0%	
P value			< 0.001**	

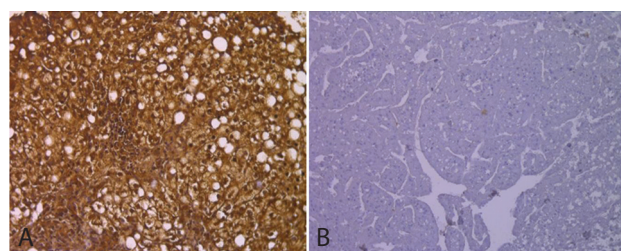


Fig 1. (A) Human liver tissue stained by immunohistochemistry for COX2 in patients with chronic HCV infection stained by DAB chromagen is showing as brown in positive cases at magnification 200X (B) Negative expression.

Table 3. **Expression of CMV in patients with chronic HCV infection and healthy control group**

			Studied groups	
			Chronic HCV	Control
CMV	Negative	Count	9	30
		%	30.0%	100.0%
	Positive	Count	21	0
		%	70.0 %	0.0%
Total		Count	30	32
		%	100.0%	100.0%
P value			< 0.001**	

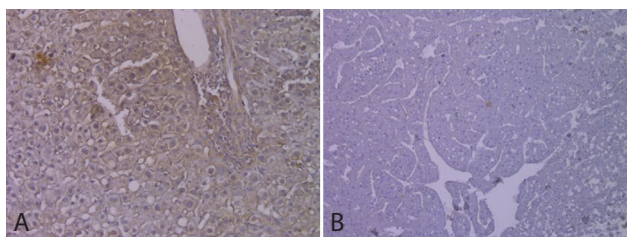


Fig 2. (A) Human liver tissue stained by immunohistochemistry for CMV in patients with chronic HCV infection stained by DAB chromagen is showing as brown in positive cases at magnification 200X (B) Negative expression.

liver tissue in patients with chronic HCV infection and that the COX-2 hepatic upregulation was present especially at areas of active inflammation. These results were explained by the major action of COX-2 as factor in inflammation with the final induction of COX-2 in necro-inflammatory injury of the liver²⁵ Bassiouny et al.²⁶ reported that the up-regulation of COX-2 expression was apparent in patients with chronic HCV infection Regardless of the presence of cirrhosis while 80% of cirrhotic cases showed marked COX-2 expression. Cheng and Hada²⁷ was proved that up-regulation of COX-2 expression was present in cirrhotic tissues relative to HCC as well as in well-differentiated HCC. over-expression of COX-2 in cirrhosis was apparent in a study that assess in patients with cirrhosis due to HBV and HCV infection while our series inclusive HCV infection patients Mohamed et al.²⁸ Another study, we were able to express a significant relation found between overall COX-2 expression and viral load of the HCV-RNA.²⁹ while Waris and Siddiqui³⁰ was found the increase in Cox-2 mRNA expression in cells containing the HCV replicon, indicate that HCV gene expression control Cox-2 activity at the stage of transcription. Holt and Adams³¹ who indicated that COX-2-derived mediators have special functions at various times in the pathogenesis of chronic hepatitis. Yosry et al.²⁹ suggest that COX-2 expression seems to be correlated between inflammatory activity of the liver of patients with chronic HCV infection and the

response to antiviral treatment which was clear by the reduction of COX-2 expression. Also Manning et al.³² indicated that reduction of liver Cox-2 level after giving INF as treatment. Gomaa et al.³³ show upregulation of COX-2 in HCV infection, which is related with poor virological response. CMV is more widespread in developing countries and can affect 70–100% of the human population. In the current study showed high expression of CMV (70.0%) in the liver tissue in patients with HCV infection in different with stage of fibrosis. The infection by CMV was depended on the detection of CMV replication in the blood. reactivation of CMV infection was occurred in the absence of an effective immune response.³⁴ CMV reactivated in immunosuppression^{35,36} and by directly increasing HCV replication is unknown. This is the result of explosion of high levels of CMV replication.³⁷ Bayram et al.³⁸ was shown that CMV was diagnosed in HBV or HCV patients as a dual infection and that it can increase the risk of the disease. In Egypt, Tabl et al.³⁹ were examined the potential role that CMV plays in chronic HCV progression. Also Bader El din et al.,⁴⁰ demonstrate higher rate of CMV co-infection in chronic HCV patients in Egypt than other patient populations. Whether CMV infection predisposes patients to HCV or HCV infection predisposes patients to CMV is not known. Various studies indicated that CMV causes hepatitis with fibrosis of liver cells and inflammation That means CMV influence the liver and overall immunological condition of the body.^{38,40,41} High level of liver enzymes and remarkable histological changes in the liver of CMV-HCV co-infected patients.³⁸ The serum levels of AST and ALT enzymes showed elevated in CMV, thus indicating a role of CMV in pathogenesis of the liver. Rafael et al.,⁴² indicated that CMV infection interacted with HCV and raised the effect on the liver enzymes and cause hepatitis. Considering the fact that HCMV viruses contribute an immunomodulatory effect resulting in developed of immunosuppression^{43,44} and dysregulation of cytokine which could fast HCV pathogenesis of patients in critical condition.³⁹ CMV infection promotes HCV pathogenesis by prohibition the normal mechanisms responsible for HCV elimination, thus playing vital role in HCV existence and pathogenicity.⁴⁵

Conclusion

COX-2 and CMV seem to be related to the inflammatory activity and participate in the pathogenesis in patient with chronic HCV infection.

Acknowledgment

I would like to express my thanks and my gratitude to all who contributed in this study.

Conflicts of Interest

There are no conflicts of interest. ■

References

- McCombs J, Matsuda T, Tonnu-Mihara I, et al. The risk of long-term morbidity and mortality in patients with chronic hepatitis C results from an analysis of data from a department of veterans affairs clinical registry. *JAMA Intern Med.* 2013;12505.
- Hassan H: The Correlation of HCV, HLA-DR typing and endothelin level with Oral Lichen Planus, PhD thesis. Medical Microbiology. Al-Nahrain University, 2015.
- World Health Organisation. Available at: <http://www.who.int>. Accessed September. 1,2012.
- Kwon YC, Ray RB, Ray R: Hepatitis C virus infection: establishment of chronicity and liver disease progression. *EXCLI J.* 2014;13:977–996.
- Leftkowitz E, King A, Adams M, et al. *Virus Taxonomy - Ninth Report of the International Committee on Taxonomy of Viruses.* 2011; London: Elsevier.

6. Simmonds P, Becher P, Collett MS, et al. Flaviviridae. In: King AMQ, Adams MJ, Carstens EB, Lefkowitz EJ (eds) *Virus taxonomy*. Elsevier, Oxford. 2011; pp 1003–20.
7. Kwon YC, Ray RB, Ray R. Hepatitis C virus infection: establishment of chronicity and liver disease progression. *EXCLI Journal*. 2014;13:1611–2156.
8. Hussein A, Khashman B, Hussain S: Role of Tgf- β 1 and Gremlin-1 in the pathogenesis of chronic hcv infection and hepatocellular carcinoma. *Indian J Appl Res*. 2013;3.
9. Little D, Samuel LJ, Anthony TB. Cyclooxygenase (COX) Inhibitors and the Intestine. *J Vet Intern*. 2007;21:367–377.
10. Cheng AS, Chan HL, Leung WK, Wong N, Johnson PJ, Sung JJ: Specific COX-2 inhibitor, NS-398, suppresses cellular proliferation and induces apoptosis in human hepatocellular carcinoma cells. *Int J Oncol*. 2003;23:113–119.
11. Giannitrapani L, Soresi M, Ingraob S, et al. Response to antiviral therapy and hepatic expression of cyclooxygenases in chronic hepatitis C. *Eur J Gastroenterol Hepatol*. 2007;19:927–933.
12. Martinez N, Ricote C, Manzon C, et al. Role of COX-2 in the pathogenesis of chronic liver disease. *Med Clin*. 2003;29:743–748.
13. Nuñez O, Fernández-Martínez A PL, Majano PL, et al. Increased intrahepatic cyclooxygenase 2, matrix metalloproteinase 2, and matrix metalloproteinase 9 expression is associated with progressive liver disease in chronic hepatitis C virus infection: role of viral core and NS5A proteins. *Gut*. 2004;53:1665–1672.
14. Ching JL, Chun WC, Fang SW, et al. Anti-hepatitis C virus activity of *Acacia confusa* extract via suppressing cyclooxygenase-2. *Antiviral Research*. 2011;89:35–42.
15. Ross S, Novak Z, Pati S, Boppana S. Diagnosis of cytomegalovirus infections *Infect Disord Drug Targets*. 2011;11:466–474.
16. Boeckh M, Geballe AP. Cytomegalovirus: Pathogen, paradigm, and puzzle. *J Clin Invest*. 2011;121:1673Y80.
17. Scholz M, Doerr HW, Cinalt J. Human cytomegalovirus retinitis: pathogenicity, immune evasion and persistence. *Trends Microbiol*. 2003;11:171–178.
18. Cannon MJ, Schmid DS, Hyde TB. Review of cytomegalovirus seroprevalence and demographic characteristics associated with infection. *Rev Med Virol*. 2010;20:202–213.
19. Gandhi MK, Khanna R. Human cytomegalovirus: clinical aspects, immune regulation, and emerging treatments. *Lancet Infect Dis*. 2004;4:725–738.
20. Görzer I, Kerschner H, Redlberger-Fritz M, Puchhammer-Stöckl E. Human cytomegalovirus (HCMV) genotype populations in immunocompetent individuals during primary HCMV infection. *J Clin Virol*. 2010;48:100–103.
21. Gredmark S, Jonasson L, Van Gosliga D, Ernerudh J, Söderberg-Nauclér C. Active cytomegalovirus replication in patients with coronary disease. *Scand Cardiovasc J*. 2007;41:230–234.
22. Cecilia S, Jay A Nelson. Human cytomegalovirus latency and reactivation a delicate balance between the virus and its Host's immune system. *Intervirology*. 1999;42:314–321.
23. Brunt EM. Grading and staging the histopathological lesions of chronic hepatitis: the Knodell histology activity index and beyond. *Hepatology*. 2000;31:241–246.
24. Nunez O, Fernandez-Martínez A, Majano PL, et al. Increased intrahepatic cyclooxygenase 2, matrix metalloproteinase 2 and matrix metalloproteinase 9 expression is associated with progressive liver disease in chronic hepatitis C virus infection: role of viral core and NS5A proteins. *Gut*. 2003;53:1665–1672.
25. Cheng AS, Chan HL, Leung WK, et al. Specific COX-2 inhibitor, NS- 398, suppresses cellular proliferation and induces apoptosis in human hepatocellular carcinoma cells. *Int J Oncol*. 2003;23:113–119.
26. El-Bassiouny AE, Zoheiry MM, Nousseir MM, et al. Expression of cyclooxygenase-2 and transforming growth factor-beta1 in HCV-induced chronic liver disease and hepatocellular carcinoma. *Med Gen Med*. 2007;9:45–51.
27. Cheng J, Hada T. The significance of COX-2 and COX-2 Inhibitors in liver fibrosis and liver cancer current medicinal chemistry. 2005;4:199–206.
28. Mohammed NA, El-Aleem SA, El-Hafiz HA, et al. Distribution of constitutive (COX-1) and inducible (COX-2) cyclooxygenase in postviral human liver cirrhosis: a possible role for COX-2 in the pathogenesis of liver cirrhosis *J Clin Pathol*. 2004;57:350–354.
29. Yosry A, El-Hendawy A, EL-Sahhar M, Esmat G, et al. Over-Expression of Hepatocyte Cyclooxygenase-2 in Egyptian Chronic Hepatitis C-Infected Patients and the Effect of Interferon-based Therapy. *Kasr El Aini Med J*. 2012;18.
30. Waris G, Siddiqui A. Hepatitis C virus stimulates the expression of cyclooxygenase-2 via oxidative stress: role of prostaglandin E2 in RNA replication. *J Virol*. 2005;79:9725–9734.
31. Holt AP, Adams DH. Complex roles of cyclo-oxygenase 2 in hepatitis. *Gut*. 2007;56:903–904.
32. Manning DS, Sheehan KM, Byrne MF, Kay EW, Murray FE. Cyclo-oxygenase-2 expression in chronic hepatitis C and the effect of interferon alpha treatment. *J Gastroenterol Hepatol*. 2007;22:1633–1637.
33. Gomaa WM, Ibrahim MA, Shatat ME: Overexpression of cyclooxygenase-2 and transforming growth factor-beta 1 is an independent predictor of poor virological response to interferon therapy in chronic HCV genotype 4 patients. *Saudi J Gastroenterol*. 2014;20:59–65.
34. Gandhi MK, Khanna R. Human cytomegalovirus: clinical aspects, immune regulation, and emerging treatments. *Lancet Infect Dis*. 2004;4:725–738.
35. Noraz N, Lathey JL, Spector SA: Human cytomegalovirus-associated immunosuppression is mediated through interferon-alpha. *Blood*. 1997;89:2443–2452.
36. Rook AH. Interactions of cytomegalovirus with the human immune system. *Rev Infect Dis*. 1988;10:5460–5467.
37. Sia IG, Wilson JA, Groettum CM, Espy MJ, Smith TF, Paya CV: Cytomegalovirus (CMV) DNA load predicts relapsing CMV infection after solid organ transplantation. *J Infect Dis*. 2000;181:717–720.
38. Bayram A, Ozkur A, Erkilic S: Prevalence of human cytomegalovirus coinfection in patients with chronic viral hepatitis B and C: A comparison of clinical and histological aspects. *J Clin Virol*. 2009;45:212–217.
39. Tabll A, Shoman S, Ghanem H, et al. Assessment of human cytomegalovirus coinfection in Egyptian chronic HCV patients. *Virol J*. 2011;8:343.
40. Bader el-Din NG, Abd el-Meguid M, Tabll AA, et al. Human cytomegalovirus infection inhibits response of chronic hepatitis-C-virus-infected patients to interferon-based therapy. *J Gastroenterol Hepatol*. 2011;26:55–62.
41. Humar A, Kumar D, Raboud J, Caliendo AM, Moussa G, Levy G, et al: Interactions between cytomegalovirus, human herpesvirus-6, and the recurrence of hepatitis C after liver transplantation. *Am J Transplant*. 2002;2:461–466.
42. Rafael E, de la Hoz A, Stephens G, Christopher S: Diagnosis and treatment approaches to CMV infections in adult patients. *J Clin Virol*. 2002;25:51–512.
43. Lee SO, Razonable RR: Current concepts on cytomegalovirus infection after liver transplantation. *World J Hepatol*. 2010;27:325–336.
44. Varani S, Landini MP: Cytomegalovirus-induced immunopathology and its clinical consequences. *Herpesviridae*. 2011;7:2:6.
45. Chakraborty A, Patil K, Dasgupta S, et al. Incidence of CMV-HCV coinfection in renal transplant recipient. *BMJ*. 2012; Case Reports. doi:10.1136/bcr.2011.5314.

This work is licensed under a Creative Commons Attribution-NonCommercial 3.0 Unported License which allows users to read, copy, distribute and make derivative works for non-commercial purposes from the material, as long as the author of the original work is cited properly.