

Leiomyosarcoma of the maxilla: a rare challenging case

Sedigheh Rahrotaban,^a Pouyan Aminishakib,^a Samira Derakhshan^a & Sara Mehrabi^b

Leiomyosarcoma (LMS) is a rare malignant lesion of head and neck region. It usually arises from smooth muscle cells of blood vessel wall in this area. Clinically, the tumour often presents as a slow-growing, painless destructive mass with a relatively firm consistency. It usually involves adults, and is rarely reported in children.

Here, we report a case of LMS of maxilla in a 73-year-old male with a destructive behaviour and also discuss the diagnostic procedure proposed to make a definitive diagnosis in such unusual cases.

Keywords maxilla, leiomyosarcoma, neoplasm

Introduction

Soft tissue sarcomas are rare neoplasms in the head and neck as only 10% of all soft tissue tumours occur in this region.¹ There are many histopathologic difficulties in the diagnosis of various subtypes of sarcomas.²

Leiomyosarcoma (LMS) is a malignant tumour of smooth muscle origin and is frequently seen at sites with large amount of smooth muscles such as female genital tract and gastrointestinal region.^{3,4} Its occurrence in head and neck is rare accounting for 4% of all sarcomas in this area⁵⁻⁸ but head and neck LMS behave more aggressive clinically and have poor prognosis.⁴ The clinical appearance of this neoplasm is usually like benign conditions so it can be mistaken for non-malignant lesions.⁵ Aggressive primary treatment after early diagnosis is very important for improving prognosis.⁵

In this article, we represent a case of primary LMS of the maxilla and describe the differential diagnosis of this tumour.

Case Presentation

A 73-year-old man was referred to the Department of Oral and Maxillofacial Pathology, Tehran University of Medical Sciences, in April 2015 with a single ulcerated swelling of the posterior right area of upper jaw under complete denture about 1 month ago. Clinical examination of the affected area revealed that alveolar bone was totally replaced by an exophytic ulcerated mass. No other intra/extra oral sign was observed following comprehensive clinical examination.

Also, the past medical/dental history of the patient was unremarkable.

The panoramic view of the maxilla showed an ill-defined radiolucent lesion of the right, posterior area which seemed to invade into right maxillary sinus (Fig. 1). Therefore, a cone beam computed tomography (CBCT) image was taken to determine the exact margin and destructive behaviour of the lesion. The imaging features of the lesion confirmed the destruction of the whole thickness of alveolar bone and infiltration to the maxillary sinus (Fig. 2). Then, an incisional biopsy was performed by an oral and maxillofacial surgeon, and hematoxylin and eosin (H&E) stained histopathologic slides were examined using light microscopy. The sections

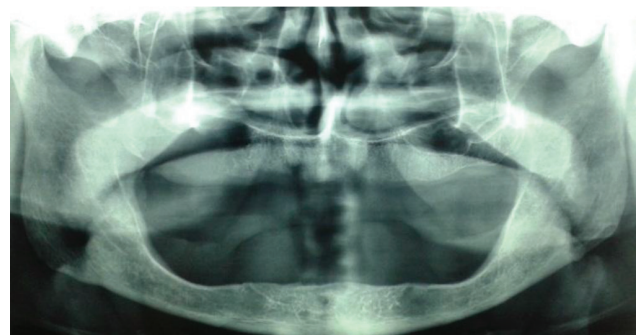


Fig. 1 Panoramic view of a radiograph showing destruction of the floor of the right maxillary sinus.

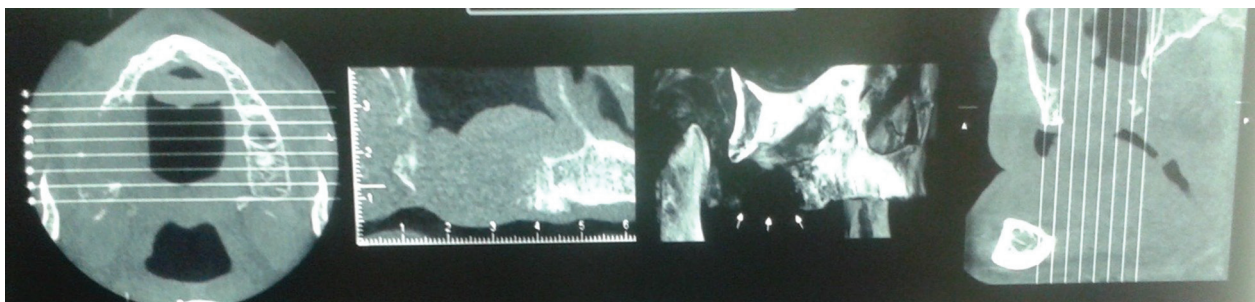


Fig. 2 Cone beam computed tomography (CBCT) showing destruction of buccal and palatal plate of the maxillary bone.

^aDepartment of Oral and Maxillofacial Pathology, School of Dentistry, Tehran University of Medical Sciences, Tehran, Iran.

^bDepartment of Oral and Maxillofacial Pathology, School of Dentistry, Zanjan University of Medical Sciences, Zanjan, Iran.

Correspondence to Sara Mehrabi (email: saramehr22@gmail.com).

(Submitted: 22 March 2015 – Revised version received: 13 April 2015 – Accepted: 27 April 2015 – Published online: Summer 2015)

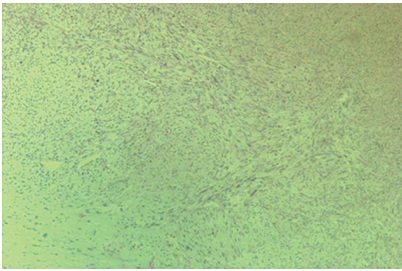


Fig. 3 Fascicles of spindle shaped tumoural cells (Hematoxylin and Eosin stain; 40×).

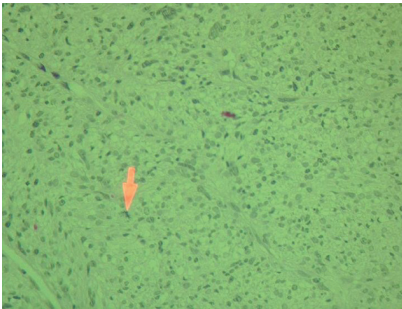

Fig. 4 Tumoural cells showing atypia and atypical mitotic figures (Hematoxylin and Eosin stain 100×).

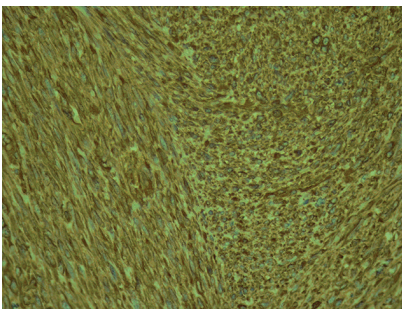


Fig. 5 Immunohistochemical stain for desmin showing positivity in cytoplasm of tumoural cells.

revealed highly cellular fascicles of neoplastic spindle cells with pleomorphic features and scant cigar-shaped nuclei (Fig. 3). Numerous mitotic figures and also atypical tri-polar and ring-shaped mitotic figures were observed (Fig. 4). Also, scattered foci of necrosis were seen among tumoural cells.

So, a primary diagnosis of “malignant spindle cell tumour” was rendered and the specimen was submitted for immunohistochemical (IHC) staining to recognise the origin of the neoplastic cells. Positive IHC staining of vimentin (Fig. 5), desmin, smooth muscle actin (SMA) (Fig. 6) and Ki67 (more than 20%) (Fig. 7) led to make a definitive diagnosis of LMS. Later, the patient was

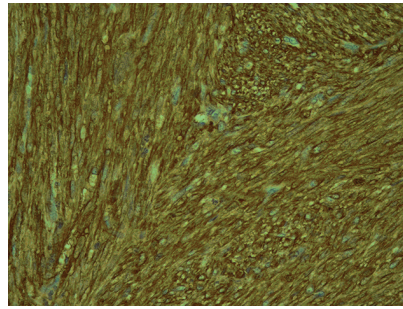


Fig. 6 Immunohistochemical stain for smooth muscle actin (SMA) showing positivity in cytoplasm tumoural cells.

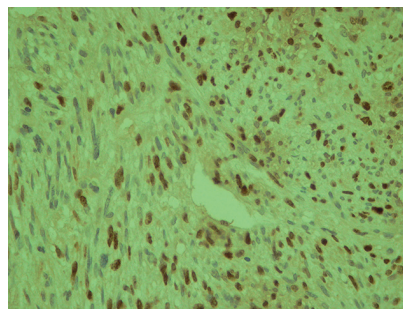


Fig. 7 Immunohistochemical stain for Ki67 showing more than 50% proliferation index in tumoural cells nuclei.

referred to an oncologist to begin the therapeutic process.

Discussion

LMS is a very rare entity in oral cavity.⁹ As far as we searched, there were only 12 case reports of primary maxilla LMS presented in English literature during the past 15 years.^{1,5-8,10,11} LMS may originate from sparse smooth muscles in wall of blood vessels, circumvallate papilla and myoepithelial cells of the salivary glands.¹² Scarcity of smooth muscles in oral cavity explains the low occurrence of this neoplasm in this region, but it also may be associated with misdiagnosis of lesion and delay in diagnosis.⁹ Another origin for LMS is pluripotential mesenchymal cells and metastasis from other body sites.⁵

There is no age predilection for LMS¹² but its frequency increases with age.⁹ It is more common in females.¹³ In our case the patient was a male, who was 73 years old at the time of diagnosis.

The most frequent site of involvement of primary LMS in oral cavity is mandible followed by maxilla, tongue, buccal mucosa, lip, floor of the mouth, hard palate, soft palate and maxillary sinus.¹²

Computed tomography and magnetic resonance imaging (MRI) are needed after clinical examination. Especially, MRI is useful for the evaluation of vascular involvement.¹⁴ In this case, CBCT revealed an ill-defined mass in the posterior part of maxilla perforating buccal and palatal cortical plates and invading the right maxillary sinus. According to imaging, maxilla was the primary arising region of the lesion but determining the exact origin of the tumour of maxillary soft tissue or bone was not possible.

Most often, LMS is a painless mass firmly attached to the surrounding structures and sometimes may be ulcerated.¹² Usually signs and symptoms are dependent to the location of the lesion where it arises, and are non-specific.⁵ In clinical evaluation, the lesion was about 3 cm with ulceration without pain, and was located under complete denture prosthetics. Although pain and tenderness are relatively prominent features in leiomyoma, they are rare presentation in LMS.⁵

The diagnosis of LMS may be challenging in some cases and should be confirmed by IHC study.¹⁵ In our case, histopathologic evaluation revealed interlacing fascicles of spindle cells scantily having blunt-end nuclei with malignant features such as prominent nucleoli and mitotic activity. The tumour was moderately differentiated and there was a list of spindle cell sarcomas for differential diagnosis such as myofibrosarcoma, fibrosarcoma, malignant peripheral nerve sheath tumour (MPNST), malignant fibrous histiocytoma and rhabdomyosarcoma.

So, we recommended a panel of IHC markers including vimentin, desmin, smooth muscle actin, S100 and Ki67. Vimentin and desmin are intermediate filament proteins. Vimentin is related to mesenchymal origin of tumour and desmin is associated with skeletal and smooth muscle cells and is the most sensitive marker for skeletal and smooth muscle differentiation, but it is not specific and can be expressed in some other non-myogenous tumours. Our case showed positivity for vimentin and desmin in cytoplasm of tumoural cells.^{13,16}

Special isoforms of actin like SMA is useful for differentiation between smooth and skeletal muscle cells, although it can be expressed by myofibroblasts too, but the pattern of expression is different. SMA is expressed in cytoplasm periphery in myofibroblasts, but uniformly in

cytoplasm of smooth muscle cells. In this case SMA was uniformly positive in cytoplasm of tumoural cells.¹⁶

S100 is a neurogenic marker, and in our case it was used for rolling out MPNST¹³ and it was mild or focally positive.

CK and EMA positivity may be seen in some of the LMSs.^{5,13} The Ki67 index was more than 50% in this case. Some histopathologic characteristics are suggested for diagnosis between leiomyoma and LMS including cellular density, necrosis, cell atypia and nuclear mitotic

figures. Mild atypia may be seen in leiomyoma but it has a very low mitotic index, so for confirming the diagnosis of LMS 5, mitosis/10 HPF is needed. Presence of necrosis can be useful for the diagnosis of LMS just as in our case.¹⁶

The usual route of metastatic spread for LMS is bloodstream to the lungs.⁵ This patient had localized disease and no palpable neck nodes at the time of presentation. The initial method for treatment was wide surgical excision. Neck dissection usually is not necessary because of rarity of metastasis to lymph

nodes.⁵ Prognosis of LMS is related to the site of involvement. In the head and neck area, anatomic structures limits complete resection of tumour so some difficulties in tumour management is present.² Therefore, local recurrence is under expectation especially in the first two years of treatment.

Further studies and case presentations would be helpful for early detection of the lesions and accurate guide for diagnosis, which both have influences on tumour management and improving survival rate. ■

References

- Ikram M, Ahmed I, Ahmed D, Ahmed YI. Leiomyosarcoma of the maxilla with spinal metastasis: a case report. *Ear Nose Throat J.* 2003 Jun;82(6): 458–60. doi: <http://dx.doi.org/10.3748/wjg.v13.i7.1135> PMID: 12861874
- Tejani MA, Galloway TJ, Lango M, Ridge JA, Von Mehran M. Head and neck sarcomas: a comprehensive cancer center experience. *Cancers (Basel).* 2013 Jul 15;5(3):890–900. doi: <http://dx.doi.org/10.3390/cancers5030890> PMID: 24202325
- Mesquita RA, Migliari DA, de Sousa SO, Alves MR. Leiomyosarcoma of the buccal mucosa: a case report. *J Oral Maxillofac Surg.* 1998;56:504–7. doi: [http://dx.doi.org/10.1016/s0278-2391\(98\)90723-6](http://dx.doi.org/10.1016/s0278-2391(98)90723-6) PMID: 9541354
- Gustafson P, Willén H, Baldetorp B, Fernö M, Akerman M, Rydholm A. Soft tissue leiomyosarcoma. A population-based epidemiologic and prognostic study of 48 patients, including cellular DNA content. *Cancer* 1992 Jul 1;70(1):114–9. doi: [http://dx.doi.org/10.1002/1097-0142\(19920701\)70:1%3C114::aid-cnrc2820700119%3E3.0.co;2-u](http://dx.doi.org/10.1002/1097-0142(19920701)70:1%3C114::aid-cnrc2820700119%3E3.0.co;2-u) PMID: 1606532
- Yadav J, Bakshi J, Chouhan M, Modi R. Head and neck leiomyosarcoma. *Indian J Otolaryngol Head Neck Surg.* 2013 Jul;65(Suppl 1):1–5. doi: <http://dx.doi.org/10.1007%2Fs12070-011-0305-8> PMID: 3718933
- Wada S, Yue L, Furuta I, Takazakura T. Leiomyosarcoma in the maxilla: a case report. *Int J Oral Maxillofac Surg.* 2002 Apr;31(2):219–21. doi: <http://dx.doi.org/10.1054/ijom.2001.0149> PMID: 12102424
- Sandhu SV, Sodhi SP, Rai S, Bansal H. Primary leiomyosarcoma of the maxilla: an investigation loom-report of a challenging case and review of literature. *J Oral Maxillofac Pathol.* 2014;18(3):453–9. doi: <http://dx.doi.org/10.4103/0973-029X.151350> PMID: 25949006
- Taghipour Zahir S, Sharahjin NS. Leiomyosarcoma of the maxilla in a 24-year-old man who initially presented with odontalgia, and suffered from tumour mismanagement. *BMJ Case Rep.* 2013 Dec;5:2013, pii. doi: <http://dx.doi.org/10.1136/bcr-2013-200933> PMID: 24311413
- Eppsteiner RW, De Young BR, Milhem MM, Pagedar NA. Leiomyosarcoma of the head and neck: population-based analysis. 2011 Sep;137(9):921–4. doi: <http://dx.doi.org/10.1001/archoto.2011.147> PMID: 21930982
- Montgomery E, Goldblum JR, Fisher C. Leiomyosarcoma of the head and neck: a clinicopathological study. *Histopathology* 2002 Jun;40(6):518–25. doi: <http://dx.doi.org/10.1046/j.1365-2559.2002.01412.x> PMID: 12047762
- Riaz N, Warriach RA, Aftab A. Massive leiomyosarcoma of the maxilla. *J Ayub Med Coll Abbottabad.* 2011 Apr-Jun;23(2):180–3. PMID: 24800376
- Nagpal DK, Prabhu PR, Shah A, Palaskar S. Leiomyosarcoma of buccal mucosa and review of literature. *J Oral Maxillofac Pathol.* 2013 Jan;17(1):149. doi: <http://dx.doi.org/10.4103/0973-029X.110732> PMID: 23798856
- Weiss SW, Goldblum JR. *Enzinger and Weiss's soft tissue tumors*, 6th ed. Philadelphia: Mosby; 2014.
- Skoulakis C, Chimona TS, Tsirevelou P, Papadakis CE. Subcutaneous leiomyosarcoma of the neck: a case report. *Cases J.* 2010 Feb 3;3:52. doi: <http://dx.doi.org/10.1186/1757-1626-3-52> PMID: 20205848
- Rodini CO, Pontes FS, Pontes HA, Santos PS, Magalhães MG, Pinto DS Jr. Oral leiomyosarcoma: report of two cases with immunohistochemical profile. *Oral Surg Oral Med Oral Pathol Oral Radiol Endod.* 2007;104(4):e50–5. doi: <http://dx.doi.org/10.1016/j.tripleo.2007.05.005> PMID: 17706443
- Rosi J. *Rosai and Ackerman's surgical pathology*, 10th ed. Philadelphia: Mosby; 2011.