

Cerebellar Tubercular Abscess

Adil Aziz Khan¹, Shafiq Umar² and Huma Mushtaq³

¹Senior Registrar, Department of Neurosurgery, Hoy Family Hospital Rawalpindi

²Registrar Department of Neurosurgery, Holy Family Hospital Rawalpindi

³Associate Prof. Department of Pathology, Islamabad Medical & Dental College, Islamabad

Abstract

Tubercular brain abscess is an uncommon lesion and tubercular cerebellar abscess is rarely reported. Almost all case reports of tuberculous abscess are described in HIV-infected or immunocompromised patients. We report a case of presented with an immunocompetent patient who was diagnosed with probable tuberculous brain abscess of the cerebellum. She complained of headache, neck pain and unsteadiness of gait since two months and associated diplopia on clinical examination. She did not have any history of pulmonary tuberculosis. Diagnosis was made by CT scan/MRI of brain. She responded well to anti tuberculous treatment and her symptoms resolved without any surgical intervention.

Keywords: Immunocompetent adult, Solitary cerebellar abscess, Tuberculous abscess,

Introduction

In the CNS, tuberculosis is usually presented as meningeal infection or as tuberculoma; rarely is it an abscess.¹ For this reason, tuberculous abscess should be considered in patients with preexisting extracranial tuberculosis presenting with brain abscess especially individuals from areas where tuberculosis is endemic.² Tuberculous brain abscess is a focal collection of pus containing abundant acid fast bacilli (AFB), surrounded by a dense capsule consisting of vascular granulation tissue.² This condition is more commonly seen in immunocompromised patients who are unable to mount a granulomatous inflammatory response.^{3,4} The pathogenesis of tuberculous brain abscess is similar to other forms of CNS tuberculosis. It is postulated to be a hematogenous dissemination from the lung. The appearance of tuberculomas on CT scan usually reveals small rings or nodular-enhancing lesion with only mild edema and mass effect, and on magnetic resonance imaging (MRI), they often have an isointensity or hypointensity center on T-2

weighted images.³ Tuberculous abscess of the posterior cranial fossa risks rapid deterioration from brainstem compression, obstructive hydrocephalus and tonsillar herniation, thus necessitating surgical intervention.⁵ Other reports, however, have suggested that treatment with prolonged antituberculous therapy may be adequate especially in patients who have relatively early lesions with poorly formed capsules, such as in our case.⁵

Case Report

A 19-year-old girl presented with a 4-week history of headache, gradually increasing in intensity, associated with persistent vomiting. There was no history of previous medication. On admission, the patient was found to have temperature of 37.4 °C, pulse rate of 76 beats/min, respiratory rate of 20 breaths/min, blood pressure of 110/80 mmHg. The neurological examination revealed an alert patient with diplopia, truncal ataxia, impaired finger-to-nose test with dysdiadochokinesia of the left side. She had neither nuchal rigidity nor abnormality of the cranial nerves. Laboratory examinations showed normal serum electrolyte levels, renal and liver function tests. Complete blood cell count showed: Hb13.0 g/dl, TLC:5600/mm³ (66% Neutrophils, 18% Lymphocytes, 12% Monocytes, 4% Eosinophils) and 275,000 platelets/mm³. A chest roentgenogram was unremarkable.

MRI brain showed two ring enhancing lesions in the left cerebellum, with perilesional edema (Figure 1). The mass resulted in compression over the adjacent cerebellar parenchyma and dorsal brain stem. The fourth ventricle was effaced while rest of the ventricles were prominent. The sulci and cisterns were unremarkable. No significant shift of midline structures was observed. The findings revealed ring enhancing lesions in the left cerebellum, suggestive of tubercular abscess. Antituberculous treatment including rifampicin, isoniazid, streptomycin and pyrazinamide was given and in 15 days the patient's headache along with vomiting was relieved. The follow-up MRI after 4 months of ATT, revealed resolution of cerebellar abscess (enhancing nodules) (Figure 2). The patient made an uneventful recovery with resolution of her neurological deficits and is being continued on antituberculous chemotherapy.

Corresponding Author

Dr Huma Mushtaq

E mail:dr_kat18@hotmail.com

Received: September 5,2016; Accepted: Oct 15, 2916

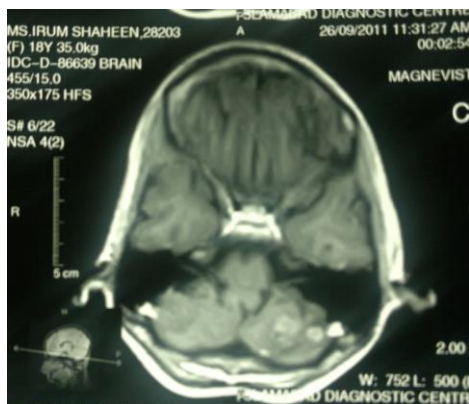


Figure 1: MRI axial view with contrast, with enhancing nodules

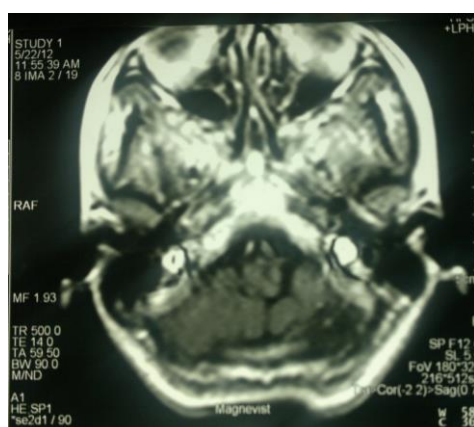


Figure 2: MRI axial view with contrast, resolution of the enhancing nodules

Discussion

Tuberculous brain abscess (TBA) is one of the rare forms of central nervous system tuberculosis. Cerebellar abscess due *Mycobacterium tuberculosis* is extremely rare even in a country where tuberculosis is an alarming public health problem. It is usually associated with foci of infection either in the lung or with an immunocompromised state. An isolate or primary TBA with no evidence of tuberculosis elsewhere is even rarer, as seen in our case with no evidence of pulmonary tuberculosis. The criteria for diagnosis include pus within the brain, the presence of acid fast bacilli (AFB) in the pus and the absence of caseation and granuloma formation.⁶

Tuberculous meningitis (TBM) is the most common form of tuberculosis of brain; however solitary or multiple intracranial tuberculomas, in particular occur less frequently.⁷ In the differential diagnosis of intra-cranial tuberculosis (ICTS), images on the radiological findings should be differentiated from other causes of space occupying lesions, which include malignant diseases such as glioma or lymphoma, pyogenic abscess, toxoplasmosis,

neurocysticercosis, sarcoidosis, hydatid cysts. and late syphilitic involvement of CNS.⁷

Cerebral tuberculosis manifests predominantly as tuberculous meningitis, followed by tuberculomas, other forms of CNS tuberculosis include, cerebral abscess, cerebral miliary tuberculosis, tuberculous encephalopathy, tuberculous encephalitis and tuberculous arteritis. Tuberculous abscess of the brain is very uncommon. Though tuberculosis in CNS occurs due to hematogenous spread of *Mycobacteria* from elsewhere; TBM may occur via lymphatic spread from cervical lymph nodes. Tubercle bacilli are immobilized in end-arteries, which leads to formation of sub-meningeal tubercular foci, which may further lead to various presentations of tuberculosis.⁸ In tuberculoma, bacilli get lodged in brain and once tuberculoma is formed, it evokes secondary reaction, leading to capsule formation. The surrounding brain edema and gliosis may resemble low-grade astrocytoma. In rare cases, there may be central caseation, liquefaction and formation of an abscess. This phenomenon is very rare, tuberculous abscess commonly occurs in patients with abnormal cell mediated immunity and are mostly focal.⁸ These lesions usually occur secondary to lung disease, but in our patient it was a primary tuberculoma. The presentation is reported mostly in 3rd or 4th decade. There may be supratentorial abscess and rarely in cerebellum as observed in the present case.^{7,8}

Tuberculomas of the brain are isolated foci of caseous or proliferative tuberculosis. They may remain silent for a long time and later create symptoms. They routinely respond to antituberculous treatment. Surgical management is very rarely needed.⁹

References

1. Nathoo N, Nadvi SS, van Dellen JR, Gouws E. Intracranial subdural empyemas in the era of computed tomography: a review of 699 cases. *Neurosurgery* 1999; 44:529-36.
2. Mathisen GE, Johnson JP. Brain abscess. *Clin Infect Dis*. 1997; 25:763-81.
3. Farrar DJ, Flanagan TP, Gordon NM, Gold RL, Rich JD. Tuberculous brain abscess in a patient with HIV infection: case report and review. *Am J Med* 1997; 102:297-301.
4. Elder NC. Extrapulmonary tuberculosis. A review. *Arch Fam Med* 1992; 1:91-8.
5. Tangviriyapaiboon T, Suwansirikul S. Mycobacterial brain abscess of the cerebellum. *Journal of Infectious Diseases and Antimicrobial Agents*. 2005;22(2):71-6.
6. N Okacha, B Omar, E Mostapha, A Ali, G Miloudi, E Brahim, B Mohamed. Primary Tuberculous Cerebellar Abscess in an Immunocompetent Adult. *Inter Med* 2010; 49:875-876.
7. Oncul O, Baylan O, Muttu H, Cavulsu S, Dogan L. Tuberculous meningitis with multiple intracranial tuberculomas mimicking neurocysticercosis. *Clinical & radiological findings*. *Jpn J Infect Dis* 2005; 58:387-9.
8. Babu ML, Shavindar. Tuberculous brain abscesses. *JK-Practitioner* 2002; 9:262-63.
9. S.K. Ajay, B.B. Lakhkar N. Bhaskaranand. Intracranial Tuberculoma Manifesting During Treatment. *Indian paediatrics* 1996; 33: 231- 233