

# Management of Ingested Foreign Bodies

Muhammad Asad Chughtai<sup>1</sup>, Safdar Nawaz Malik<sup>2</sup>, Imran Ul Haq<sup>3</sup>, Muhammad Jamal Ullah<sup>4</sup>

<sup>1</sup>Assistant professor, Department of ENT, Wah Medical College

<sup>2</sup>Associate professor, Department of ENT, Islamabad Medical and Dental College

<sup>3</sup>Associate professor/HOD, Department of Anesthesia, Wah Medical College

<sup>4</sup>Professor, Department of ENT, Al-Nafees Medical College and Hospital, Islamabad

## Abstract

**Objective:** To determine the likelihood of spontaneous passage of esophageal coins in stomach, to see the effect of initial coin location on spontaneous passage and to design management strategies.

**Material and Methods:** This prospective interventional study was conducted from March 2011 to March 2016, in the department of ENT POF Hospital Wah Cantt. In all patients of coin ingestion history and radiological findings were recorded. They were evaluated after 24 hours for either spontaneous passage of coin to stomach or needed surgical intervention with either Magill forceps or oesophagoscopy. Base line investigations and repeat X-ray were done before surgical procedure.

**Results:** Out of 25 patients of coin ingestion, 60% (n=15) were boys and 40% (n=10) were girls with age range from 2 to 6 years. Total 84% patients (n=21) had coin at cricopharyngeus level, while 8% (n=2) at mid esophagus and 8% (n=2) at lower esophagus level. After 24 hours, total of 36% (n=9) patients had spontaneous passage of coin. Among them two patients were with coin at lower esophageal level while two and five patients were with coin at middle esophagus level and at cricopharyngeus level respectively. Among the remaining 16 patients only 20% (n=5) needed to go for esophagoscopy and rest 44% (n=11) had removal of coin by using direct laryngoscopy and Magill forceps.

**Conclusion:** A trial of 24 hours for spontaneous passage of coin irrespective of the site of impaction is recommended. If the coin does not pass spontaneously, then upper esophageal level coins should be attempted with Magill forceps. For Left over cases oesophagoscopy should be done.

**Key Words:** Coins, Direct Laryngoscopy, Esophagus, Magill Forceps.

## Introduction

Foreign body (FB) ingestion is a common ENT emergency, occurring mostly in children. Most of these FBs are coins while less common are buttons, bone pieces and pins.<sup>1</sup> FB ingestion in USA accounts for over 100, 000 cases per year.<sup>2</sup> Its peak incidence in pediatric population is between

6 months to 3 years.<sup>3,4</sup> In addition to young children, mentally retarded patients and developmentally delayed individuals are also at greater risk. Presently a vast variety of coins of different sizes, ranging from 4 mm to 85 mm are in use all over the world.<sup>5</sup> Mostly they are made of silver or zinc and are not causing much of the FB reaction.

There are three notorious sites for impaction of FB in esophagus. First and most common one is level of Cricopharyngeus which is at the level of sixth cervical vertebra. This place offers maximum resistance for passage of FBs. Second less common site is the mid esophagus, in the region where the aortic arch and carina overlap the esophagus. The third site is the lower esophageal sphincter that is at gastroesophageal junction.<sup>6</sup> In addition, obstruction may also occur at pathologically narrowed parts of the esophagus like stricture, tumor etc.

Coin impaction in esophagus is not life threatening condition. It can easily be removed by simple procedure. Successful removal depends upon many factors, including its location, size, experience of physician, patient cooperation, and equipment available. Mostly watchful waiting is fruitful. Since majority of the esophageal coins in children pass spontaneously to the stomach which may ultimately eliminate the need for any invasive procedures.<sup>7,8</sup> Once the coin gets impacted in the upper esophagus then it's become necessary to remove it. Prolong retention may end up with complications like mediastinitis, perforation, mucosal ulceration, extra luminal coin migration, pneumonia mediastinum and very rarely fatal complication like aortoesophageal fistula. Though minor problem like esophageal edema has also been noted with coin ingestion even with duration of impaction less than 24 hours.<sup>9</sup> Dominant signs and symptoms of impaction are dysphagia, increased salivation, vomiting and regurgitation. A thorough history coupled with plain radiography is sufficient to diagnose all coins and most of other FBs.

Different methods are in practice for removal of FB esophagus. The classical method of removal of FB with rigid endoscopy still remains the gold standard procedure.<sup>10</sup> It is done under general anesthesia and is the most favorite procedure done by otorhinlaryngologist. Other commonly practiced procedure is flexible endoscopy which is done

### Corresponding Author:

Dr Muhammad Asad Chughtai

E-mail: doctorasad.chughtai@yahoo.com

Received: August 15, 2016; Accepted: Sept 23, 2016

without general anesthesia, and is preferred by medical specialist. Magill forceps is also used as alternative methods of FB removal. Magill forceps is commonly used for coins which are placed at cricopharyngeus. This procedure is preferred by anesthetists.<sup>11,12</sup> Foley's catheter has also been used for removal of coin from esophagus. It has the advantage of being done without general anesthesia, and is more simple and economical.<sup>13</sup> Coins impacted at distal end of esophagus has also been removed successfully with the use of snares and protective endoscopy cover.<sup>14</sup> Bougies has also been used to advance the coin into the stomach.<sup>15</sup> Conservative management that includes waiting for spontaneous passage is worth mentioning. When more than one option is available, selection for an appropriate treatment option becomes difficult. The aim of our study is to share our experience of removal of coin from esophagus. In all cases first step was to wait for 24 hours for spontaneous removal of coin, followed by removal of coin with Magill forceps. Rigid oesophagoscopy was reserved for failure cases.

## **Material and Methods**

This prospective study was carried out in the department of ENT POF hospital Wah Cantt, from March 2011 to March 2016. We included 25 cases having coins impacted in the esophagus. POF Hospital is a tertiary care teaching hospital which provides health care to the employees of POF and their families as well as the private patients. Patient with positive history of coin ingestion having duration less than 24 hours were included in the study. After the initial examination; patients with history of any esophageal disease, previous history of coin impaction and those who underwent earlier attempts of removal of coin, were excluded from the study.

Age, sex, time of occurrence, location of the FB and treatment option used were recorded. In all patients, X-ray neck (AP and lateral view) was performed. The FB locations were marked as pharyngeal, proximal esophagus, middle and distal esophagus. Most common presenting symptoms were refusal to take food, vomiting, neck or chest pain, drooling of saliva, dysphagia and cough.

X-Ray was repeated in every case before taking the patient to operation theatre (OT), to see the latest location of impacted coin. Three step treatment was planned for all patients. In first stage all cases were kept waiting for 24 hours. If no spontaneous passage of coin was observed than in second phase they were taken to OT for removal with Magill forceps. In third phase all left over cases were given general anesthesia for esophagoscopy.

All the patients were briefed about the advantages and possible complications (rare) of 24 hours wait. Informed written consent was obtained from parents on a printed paper. Patients were kept nil per oral till coin removal. Vital

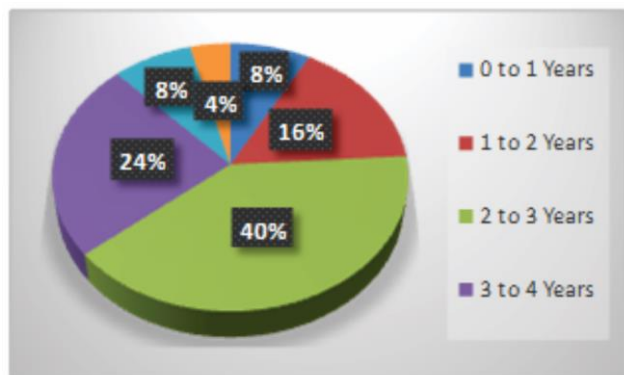
signs observation was done 8 hourly. Patients were given I/V fluid for 24 hours. After 24-hour, fresh X-rays were done to see the change of position of coin. All the cases with spontaneous passage of coin were discharged with proper informative briefing and reassurance. Rest were taken to OT for removal of coin.

The patients were sedated with injection propofol 2mg/kg body weight. They were ventilated on spontaneous breathing with hundred percent oxygen via face mask. Laryngoscope was passed in Sniff's position where coin edge was visible at cricopharyngeal level. It was grasped and removed with the Magill force. In cases where edge of coin was not visible and cricopharyngeal opening was found close, Magill forceps was inserted gently in esophagus with blades/prongs close while prongs of forceps were kept horizontal. Immediately after introducing the Magill forceps with close prongs in cricopharyngeus, prongs were opened while moving it forward, coin was grasped by closing the blades and then removed. In case of failure second attempt was made and coin was removed. In case of failure with second attempt, patients were intubated after giving the muscle relaxant. Rigid endoscopy was then the option left. After removing the coin second look oesophagoscopy was performed in all cases. Every patient was kept nil by mouth till fully conscious. There was no anesthesia related complications. Data analysis was done by using SPSS version 20. Variables were categorized, compiled and represented on tables, pie charts.

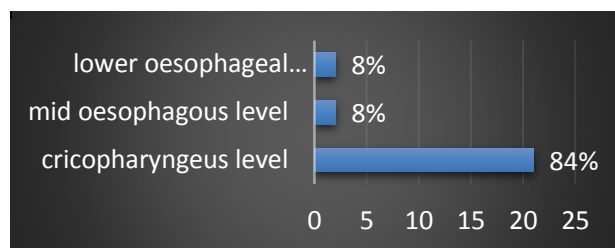
## **Results**

Total 25 cases of FB (coin) ingestion were managed. Out of 25 children, 84% (n=21) had coin at first narrowing, followed by the 8% (n=2) at second level and rest 8% (n=2) with coin at lower esophageal level, among them 60%(n=15) were male and 40% (n=10) were female. The age range of the patients was 2 to 6 years with mean age of 4 years. Five-rupee coin was most commonly found in our study. Five-rupee coin was impacted in 48% (n=12), two-rupee coin in 32% (n=8) and one-rupee coin in 20% (n=5) (Table 1). Age of patients at which coin impaction occur is shown in Fig 1, site of coin impaction in Fig 2 and common symptoms like dysphagia, refusal to take food, neck/chest pain, vomiting and drooling in Fig 3. Final radiography was done in all case before taking the patient to OT. Spontaneous passage of the coin to the stomach noted in 36% (n=9) patients. Total 44% (n=11) patients had coin removal successfully with the help of Magill forceps. Coins edge was visible on laryngoscopy in 28% cases (n=7). Rest 20% (n=5) patients had removal of coin with esophagoscopy under general anesthesia. Mean post op stay in the hospital was 6 hours and ranged from 4 to 10 hours. There were no complications of anesthesia and the procedures adopted.

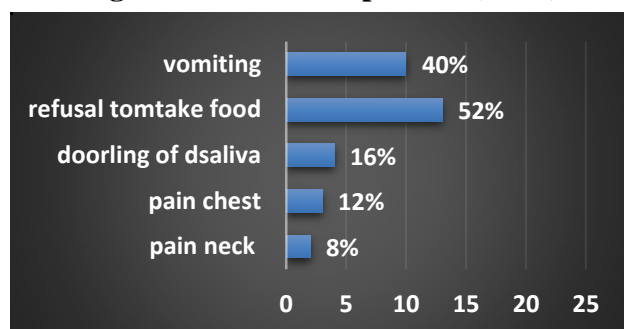
Type of coins	Number	%
5 Rupee	12	48
2 Rupee	8	32
1 Rupee	5	20



**Fig 1: Age of patients showing coin impaction (n=25)**



**Fig 2: Site of coin impaction (n=25)**



**Fig 3: Symptoms of coin impactions (n=25)**

### Discussion

FB ingestion is a common problem in children. Coins are the most common FB ingested in the esophagus in Pakistan.<sup>16,17</sup> The incidence of ingestion of FB in children is high. It could be due to their natural propensity to gain the knowledge by putting things in the mouth, inability to masticate well and inadequate control of deglutition. The majority of the pediatric patient had foreign body lodge at the level of cricopharynx, which is the narrowest part of the

pediatric gastrointestinal tract and is the site where a significant number of ingested FBs lodge.

We divided our patients in three groups depending upon the location of coin in esophagus. All individuals with positive history of ingestion and with positive radiological finding were included in the study. In our study we have 84% of coin at the level of the cricopharynx, 8% at the level of the aortic cross over and 8% were found at of the lower esophageal level. Kay M et al mentioned almost similar results.<sup>18</sup> Vivek V et al also found coin as the commonest FB and cricopharynx was the commonest site of impaction in children.<sup>19</sup>

Besides history and physical examination, radiology is a very important diagnostic tool for identification of the nature of the FB and its location. In pediatric population, 60-80% of objects caught at the level of the cricopharyngeus muscle in the proximal esophagus, 10-20% become trapped at the level of the aortic cross over and 5-20% were found at the level of the lower esophageal sphincter. Tadesse A et al in their study showed 78.8% impaction in proximal esophagus and 12.9% in mid esophagus. However, they did not have any individual with FB in distal esophagus.<sup>20</sup> Digoy GP and Connors et al also found most of their cases with impaction of coin at first narrowing of the esophagus, which is similar to our finding.<sup>21</sup>

In our study of 25 cases, 36% (n=9) patient had their coin passed spontaneously to the stomach. Among them 5 patients found FB at upper esophagus and 02 at middle and 02 at lower esophagus. This showed that the initial location of the coin in the esophagus did not affect the spontaneous passage of coin. Robert E et al recommended a repeat radiograph immediately before the endoscopy, because up to one fourth of esophageal coins pass spontaneously within 8 to 16 hours.<sup>22</sup> Most FBs leave the body spontaneously without leading to any mortality or morbidity.<sup>23</sup> Stringer et al found that 33% of esophageal coins passed spontaneously to the stomach which is more close to our results. Study conducted by Connors et al revealed that coins impacted at distal location (60%) passed spontaneously and patients (48%) in which coin found at proximal or middle esophagus did not show spontaneous passage of the coin.<sup>8</sup> They recommended a 12 to 24 hour wait and see period, in patients with coins lodged at distal esophagus only. Their results differ with our study in respect to location of coin. In our study spontaneous passage of coin was observed irrespective of site of location of coin. Chua AH in his study found spontaneous passage of 27 out of 136 coins in pediatric patients with radiographic evidence of a round radio-opaque (coin) FB.<sup>24</sup> In our study 44% of patients had removal of coin with the help of Magill forceps, and 20% with oesophagoscopy. Nasser Ahmad et al in their study removed 80% coins with Magill forceps in first attempt.<sup>25</sup> Refusal to take food and dysphagia was presenting symptom in 13 children (52%), which is similar to what

other researchers has mentioned.<sup>25</sup> In our study doodling of saliva was observed in only 4 (16%) children. Pain was presenting complaint by 20% of patients. In most of cases it was in neck or in upper chest. Ahmad N et al found 90% patient with difficulty in swallowing and excessive salivation while remaining 10% having vomiting and cough.<sup>25</sup> Although this is generally agreed that chance of coin impaction is directly proportional to its size and inversely to the age of child. There are many unanswered and debatable questions on the topic of coin impactions and its management- like which coin size is risky and what should be the criterion to wait for spontaneous passage. On completion of our study we are confident to document that coins below 20 mm in size pass spontaneously and rarely need endoscopic removal. Obtaining second x-ray just before operation in coins above 20mm in size is wasting of time and economy.

### Conclusion

All the cases of coin impaction should be offered wait and see policy for spontaneous passage for 12-24 hours. If the coin does not pass spontaneously, the upper esophageal level coins may be safely and quickly removed under direct vision by McGill's forceps using McIntosh Laryngoscope. Rest of the cases should be offered Oesophagoscopy under G/A. Further study involving a large number of patients, is needed before this regime can be generally recommended. Print and electronic media can be used to educate the masses about the hazards of coin handling by kids.

### Conflict of Interest

This study has no conflict of interest as declared by any author.

### References

1. Abdulaziz AA, Ali AM. Foreign bodies of the esophagus: two- year prospective study. *Ann Saudi Med.* 2000;2:25-62.
2. Uyemura MC. Foreign body ingestion in children. *Am Fam Physician.* 2005;72 (2):287-92.
3. McNeill MB, Sperry SL, Crockett SD, Miller CB, Shaheen NJ, Dellon ES. Epidemiology and management of esophageal coin impaction in children. *Dig Liver Dis.* 2012;44(6):482-6.
4. Waltzman ML. Management of esophageal coins. *Curr Opin Pediatr.* 2006;18(5):571-4.
5. Raahat ZM, Nusrat R, Adnan SU. Coin impaction at upper end of esophagus: wait or intervene. *Pak J Otolaryngol.* 2013;29:77-9.
6. Ratcliff KM. Esophageal foreign bodies. *Am Fam Physician.* 1991;44(3):824-31.
7. Chaikhouni A, Kratz JM, Crawford FA. Foreign bodies of the esophagus. *Am Surg.* 1985;51(4):173-9.
8. Conners GP, Chamberlain JM, Ochenschlager DW. Conservative management of pediatric distal esophageal coins. *J Emerg Med.* 1996;14(6):723-6
9. Ahmed L, Kumar S, Ashraf P, Laquee S. Endoscopic esophageal foreign body retrieval: a single center

experience. *Asian J Pharm Clin Res.* 2012;5(2):49-51.

10. Khan C, Hameed A, Choudhry AJ. Management of foreign bodies in esophagus. *J Coll Physicians Surg Pak.* 2004;14(4):218-20
11. Mahafza TM. Extracting coins from the upper end of the esophagus using a magill forceps technique. *Int J Pediatr Otorhinolaryngol.* 2002;62(1):37-9.
12. Janik JE, Janik JS. Magill forceps extraction of upper esophageal coins. *J Pediatr Surg.* 2003;38(2):227-9.
13. Digoy GP. Diagnosis and management of upper aero digestive tract foreign bodies. *Otolaryngol Clin North Am.* 2008;41(3):485-96.
14. Hameed K, Hassan MK, Rehman S, Khan D, Khan IM, Khattak AK. Management of foreign body in the upper gastrointestinal tract with flexible endoscope. *JPMI.* 2011; 25(1):29-34.
15. Emslander HC, Bonadio W, Klatzo M. Efficacy of esophageal bougienage by emergency physicians in pediatric coin ingestion. *Ann Emerg Med.* 1996;27(6):726-9.
16. Magsi PB, Sangi HA, Jamro B. Experience of foreign bodies in aero-digestive tract at tertiary care hospital Sukkur, Pakistan. *RMJ.* 2011;36(4):277-80
17. Asif M, Haroon T, Khan Z, Muhammad R, Malik S, Khan F. Foreign body esophagus: types and site of impaction. *Gomal J Med Sci.* 2013;11:163-6.
18. Kay M, Wyllie R. Pediatric foreign bodies and their management. *Curr Gastroenterol Rep.* 2005;7(3):212-8.
19. Harkare VV, Khandakkar SP, Deosthale NV, Dhoke PR, Dhote KS, Banerjee M, et al. Ingested foreign body in pharynx and oesophagus: comparison between adult and pediatric population, *J Evidence Based Med Hlthcare.* 2015; 2(44):8060-5.
20. Tadesse A, Feye A. Management of ingested foreign bodies in pediatric patients: an experience from a tertiary hospital in Ethiopia. *East Cent Afr J Surg.* 2014;19(1):11-6.
21. Digoy GP. Diagnosis and management of upper aerodigestive tract foreign bodies. *Otolaryngol Clin North Am.* 2008;41(3):485-96.
22. Kramer RE, Lerner DG, Lin T, Manfredi M, Shah M, Stephen TC, et al. Management of ingested foreign bodies in children: a clinical report of the NASPGHAN endoscopy committee. *JPGN.* 2015; 60:562-74.
23. Sugawa C, Ono H, Taleb M, Lucas CE. Endoscopic management of foreign bodies in the upper gastrointestinal tract: a review. *World J Gastrointest Endosc.* 2014; 6(10):475-81
24. Chua AH. Spontaneous passage of ingested coin in children. *Philippine J Otolaryngol Head Neck Surg;* 2015;30(2): 30-3
25. Ahmad N, Niamatullah, Yousaf M, Javaid M, Ullah I. Removal of coin from upper oesophagus under local anesthesia. *JPMI.* 2007;21(2):109-12.

#### Authorship Contribution

**Author1:** Active participation planning and final review of article

**Author2:** Active participation in research, analysis and discussion

**Author3:** Conception and planning, active participation in research

**Author4:** Active participation in research, analysis and critical view of article