

Diagnostic Accuracy of Trans-Abdominal Ultrasonography in Urolithiasis, keeping CT KUB as Gold Standard

Maryam Javed¹, Faran Nasrullah², Shahlisa Hameedi³

¹ Trainee Radiology, Armed Forces Institute of Radiology and Imaging, Rawalpindi

² Consultant Radiologist, Dept of Radiology, PAF Hospital Rafiqui, Shorkot

³ Assistant Professor, Islamabad Medical & Dental College, Islamabad

ABSTRACT

Objective: To determine the diagnostic accuracy of trans-abdominal ultrasonography in urolithiasis, keeping CT KUB as gold standard.

Material and Methods: This cross-sectional validation study was conducted at Armed Forces Institute of Radiology and Imaging, Military Hospital (MH) Rawalpindi from 15 July 2015 to 14 July 2016. In total 115 patients with expected urolithiasis were evaluated with transabdominal ultrasonography and the findings were documented. CT KUB of these patients was carried out. The sensitivity, specificity, positive predictive value, negative predictive value and diagnostic accuracy of transabdominal ultrasonography were calculated, keeping findings of CT KUB as gold standard.

Results: Among total of 115 patients, 54.78% (n=63) were males and 45.22% (n=52) were females. Mean age was 35.69 ± 5.91 years. Frequency of urolithiasis on CT KUB was recorded in 62.61% (n=72). The sensitivity, specificity, positive predictive value, negative predictive value and diagnostic accuracy of transabdominal ultrasonography in urolithiasis was calculated as 65.27%, 72.09%, 79.66%, 55.36% and 67.83% respectively.

Conclusion: The diagnostic accuracy of trans-abdominal ultrasonography in urolithiasis is acceptable for diagnosing urolithiasis and hence it may serve as an alternative in case of unavailability or contraindication to CT scan.

Key words: CT KUB, Diagnostic accuracy, Tans-abdominal ultrasonography, Urolithiasis.

Author's Contribution

¹ Conception, synthesis, planning of research and manuscript writing Interpretation and discussion

² Data analysis, interpretation and manuscript writing, ³ Active participation in data collection.

Address of Correspondence

Faran Nasrullah
Email: faran.nas@gmail.com

Article info.

Received: January 12, 2018
Accepted: July 12, 2018

Cite this article. Javed M, Nasrullah F, Hameedi S. To Determine diagnostic accuracy of Trans-abdominal Ultrasonography in Urolithiasis keeping CT KUB as Gold Standard. *JIMDC*.2018; 7(3):204-207

Funding Source: Nil

Conflict of Interest: Nil

Introduction

Urinary tract calculi are solid concretions found in the urinary tract from dissolved urinary minerals.¹ They may be found in the kidneys, ureters, urinary bladder or urethra and represent one of the major diseases affecting the population since ancient ages.² A study calculated the prevalence of urinary tract calculi to be greater in males (15%) and lesser in females (8%) with an annual incidence of 131 per 100,000.^{3,4} Urolithiasis, presenting as renal colic, flank pain, dysuria or hematuria, is one of the commonest causes to seek medical attention. Stone

disease may cause longstanding obstruction and infection, ultimately leading to renal failure.⁵ Thus, early accurate diagnosis with appropriate treatment of urolithiasis is paramount for prevention of complications and maintenance of renal function.⁶ Male gender, NSAID (Non-steroidal anti-inflammatory drugs) usage, intestinal surgery, Crohn's disease, reduced physical activity, hospitalization and gallstones are significant risk factors for urolithiasis along with metabolic disturbances such as gout, renal tubular acidosis and hypercalciuria.⁷

Acute renal colic is one of the frequent causes of presentation to the surgical department. Over the years, there has been a drastic change in the preference of investigations used to diagnose urolithiasis, so it is not always clear in which order the investigations should be carried out, especially if there is a contraindication to contrast administration or ionizing radiations. Historically, KUB radiography in the form of plain x-rays and intravenous pyelography (IVP) was used, but this had the disadvantages of radiation exposure, patient preparation and contrast administration (in cases of IVP). A study established KUB radiography to be 57 % sensitive and 76 % specific.⁸ Ultrasound (US) has emerged as a leading imaging modality for diagnosis of urinary tract calculi, as it is non-invasive, free from ionizing radiation, easily available and cost-effective.⁹ The disadvantages may include inter-operator variation and difficulty in diagnosing ureteric calculi. The sensitivity and specificity of ultrasound for urolithiasis is variable, depending upon various factors like patient habitus, operator capability, and the site and size of the calculus. The sensitivity of ultrasonography for ureteric calculi increases on addition of x-ray KUB abdomen.¹⁰

CT KUB is the most sensitive investigation for identification of urolithiasis.¹¹ However, it has some weaknesses like limited spatial resolution, due to which it may wrongly predict small calculi and stone fragments. Similarly, due to use of ionizing radiation, repeated CT scans can result in a substantial cumulative dose during short-term follow up. Low-dose protocols allow patient to be exposed to low dose causing reduced biological risk.¹¹ In Pakistan, the usage of CT KUB for diagnosis of urinary tract calculi is relatively new with the lack of availability, its cost and lack of technical expertise being the main causes of its limited use. So this study has been carried out to assess the diagnostic accuracy of ultrasonography in detecting urolithiasis in comparison with CT, for the reason that it has the advantage of lower radiation dose and easy availability in our setups.

Material and Methods

The cross sectional study was carried out at Armed Forces Institute of Radiology and Imaging, Military Hospital (MH) Rawalpindi, from 15 July 2015 to 14 July 2016. Total 115 patients with expected urolithiasis were

included in the study. Non-probability, purposive sampling was done. All the patients, reporting to the hospital during the duration of the study, who fulfilled the inclusion criteria, were included in the study. The study was approved by institute's ethical committee for research. Patients of either gender having age between 18 to 45 years, visiting to the outpatient department due to flank pain with any of the following associations like increased frequency of urination (more than twice of previous), oliguria (<400ml/24hrs), dribbling of urine (on history) or hematuria were incorporated in the study. Any Patient with known pelvic pathology, pregnant patients, patients who refused to give consent and non-cooperative patients (psychiatric patients) were eliminated from the study. All participants were briefed about the purpose of the study and informed written consent was taken. History and physical examination was done. Ultrasonography was done, through the transabdominal approach for all patients with full urinary bladder, using Toshiba Nemio XG® Doppler ultrasound scanner with 4.2MHz frequency transducer. The kidneys were visualized in both sagittal and coronal planes. Ureters were also traced down up to the urinary bladder with emphasis to the ureterovesical junction.

CT scan was carried out with Acquilion multislice (64) CT Scanner, by the trainee researcher. All findings of computed tomography scan were substantiated by the opinion of consultant radiologist. Data was entered and interpreted using SPSS version 15. Sensitivity, specificity, PPV, NPV and Accuracy were calculated as:

Sensitivity: $a / (a + c) \times 100$ or $TP / (TP + FN) \times 100$

Specificity: $d / (d + b) \times 100$ or $TN / (TN + FP) \times 100$

Positive predictive value: $a / a + b \times 100$

Negative predictive value: $d / c + d \times 100$

Accuracy: $a + d / a + b + c + d \times 100$

Results

Age of study participants ranged between 19 to 54 years with mean age calculated as 35.69 ± 5.91 years. Large number of patients (46.9%) were in 31-45 years of age group (Table 1). Out of total 115 patients, 63 were male and 52 were females (Figure 1). On CT KUB, total 72 patients (62.61 %) were positive while 43 patients (37.39 %) were negative for urolithiasis. Keeping CT KUB as gold standard, trans-abdominal ultrasonography revealed

40.87 % patients as true positive cases (Table 2).The sensitivity was 65.27 %, specificity was 72.09 %, PPV was 79.66 %, NPV was 55.36 % and diagnostic accuracy was 67.83 % (Figure 2).

Discussion

Renal colic resulting due to urinary tract calculi may present as acute abdomen and leads to a significant burden on the A & E (accident and emergency) and surgical OPD. Guidelines of the American College of Radiology (ACR), American Urological Association (AUA), and European Association of Urology (EAU) propose different investigations for further assessment of these cases.¹²

Table 1: Age distribution of patients (n=115)

Age of patients (years)	Frequency	Percentage
16 - 30	22	19.1
31 - 45	54	46.9
46 – 60	39	33.9
Total	115	100

Table 2: Cross tabulation of findings of CT KUB and trans abdominal ultrasonography in study participants (n=115)

Trans-Abdominal Ultrasonography	Urolithiasis	
	CT-KUB Positive	CT-KUB Negative
Positive	a (True positive) 47 (40.87%)	b (False positive) 12(10.43%)
Negative	c (False negative) 25 (21.74%)	d (True negative) 31(26.96%)

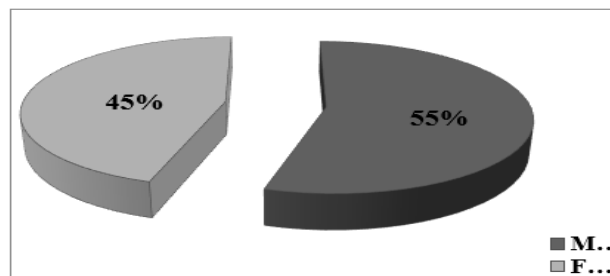


Figure 1: Graphical representation of gender distribution in study participants (n=115)

The ACR and AUA nominate CT KUB as modality of choice for urolithiasis while EAU favors ultrasound.¹²⁻¹⁴ Low dose noncontrast CT, due to its high diagnostic accuracy, is taken as the gold standard in patients with suspected urolithiasis, as it can accurately delineate the site and size of calculus (including ureteric calculi), reveal complications and unfold alternative causes of abdominal pain like appendicitis or intestinal obstruction.¹⁵ In our study, the sensitivity, specificity and diagnostic accuracy of transabdominal ultrasonography in cases of urolithiasis was calculated to be 65.27%, 72.09 % and 67.83 % respectively. The findings of our study are closely in agreement with most studies performed in this regard. Kanno T et al ¹⁶, with a sample size of 856 patients, showed that ultrasonography had a sensitivity of 78.9 % and specificity of 83.7 % for renal calculi, confirmed by non-enhanced CT. The study proved ultrasonography to be an accurate modality for detection of urolithiasis. Another study conducted by Smith-Bindman R et al ¹⁷ (conducted on 2759 patients) showed that ultrasonography as first-line investigation produced lower radiation exposure as compared to CT scan without any significant change in diagnostic ability or any other untoward effect.

Transabdominal sonography may be used effectively to detect calculi in kidneys, proximal ureter, vesicoureteric junction or urinary bladder. It also gives information regarding the extent and severity of the resulting obstruction. Mid ureter is usually obscured by bowel gas shadows and visualization of this region is limited. In this regard, findings of ultrasonography may be combined with findings of x-ray abdomen to give better diagnostic accuracy. Similarly, use of contrast medium or performing transrectal or transvaginal sonography are newer avenues which can be explored to enhance the diagnostic accuracy, but due to the limitation of the study, we did not use these techniques in this study.

In our view transabdominal ultrasonography provides many benefits as an effective diagnostic modality for urolithiasis, especially in pregnant patients and children. Newer techniques and equipment as well as use of intravenous contrast media can provide additional information and lead to even greater improvements in the diagnostic potential of ultrasonography for urolithiasis.

Not much data is available when determining the diagnostic accuracy of transabdominal ultrasonography in urolithiasis, keeping CT KUB as gold standard; however, further trials are required to validate our findings

Conclusion

Diagnostic accuracy of transabdominal ultrasonography in urolithiasis is acceptable for diagnosing urolithiasis. Hence, it may serve as an alternative in case of unavailability or contraindication to CT scan like pregnant patients. Moreover, ultrasonography has the advantage of lower radiation dose and easy availability in our setups.

References

1. Ahmad F, Nada MO, Farid AB, Haleem MA, Razack SM. Epidemiology of urolithiasis with emphasis on ultrasound detection: a retrospective analysis of 5371 cases in Saudi Arabia. *Saudi J Kidney Dis Transpl.* 2015; 26(2):386-91.
2. Nasim MJ, Bin Asad MH, Durr-e-Sabih, Ikram RM, Hussain MS, Khan MT et-al. Gist of medicinal plants of pakistan having ethnobotanical evidences to crush renal calculi (kidney stones). *Acta Pol Pharm.* 2014; 71(1):3-10.
3. Lee M-C, Bariol SV. Epidemiology of stone disease in Australia. In: Talati JJ, Tiselius HG, Albala DM, YE Z, editors. *Urolithiasis: Basic science and clinical practice.* London: Springer London, 2012; p. 73–76.
4. Romero V, Akpınar H, Assimos DG. Kidney stones: A global picture of prevalence, incidence, and associated risk factors. *Rev Urol.* 2010;12(2–3): e86-96.
5. Rafi M., Shetty A., Gunja N. Accuracy of computed tomography of the kidneys, ureters and bladder interpretation by emergency physicians. *Emerg Med Australas.* 2013; 25(5):422–426.
6. Soomro HU, Hammad Ather M, Salam B. Comparison of ureteric stone size, on bone window versus standard soft-tissue window settings, on multi-detector non-contrast computed tomography. *Arab J Urol.* 2016; 14(3):198-202.
7. Fagagnini S, Heinrich H, Rossel JB, Biedermann L, Frei P, Zeitz J, et al. Risk factors for gallstones and kidney stones in a cohort of patients with inflammatory bowel diseases. *PLoS One.* 2017; 12(10):e0185193.
8. Fulgham PF, Assimos DG, Pearle MS, Preminger GM. Clinical effectiveness protocols for imaging in the management of ureteral calculous disease: AUA technology assessment. *J Urol.* 2013; 189(4):1203–1213.
9. Mills L, Morley EJ, Soucy Z, Vilke GM, Lam SHF. Ultrasound for the Diagnosis and Management of Suspected Urolithiasis in the Emergency Department. *J Emerg Med.* 2017 pii: S0736-4679(17):30877-6.
10. M Hammad Ather, Aftab H Jafri, M Nasir Sulaiman. Diagnostic accuracy of ultrasonography compared to unenhanced CT for stone and obstruction in patients with renal failure. *BMC Med Imaging.* 2004; 4(1): 2.
11. Villa L, Giusti G, Knoll T, Traxer O. Imaging for Urinary Stones: Update in 2015. *Eur Urol Focus.* 2016; 2(2):122-129.
12. Coursey CA, Casalino DD, Remer EM, Arellano RS, Bishoff JT, Dighe M, et al. ACR Appropriateness Criteria® acute onset flank pain--suspicion of stone disease. *Ultrasound Q.* 2012; 28(3):227-33.
13. Fulgham PF, Assimos DG, Pearle MS, Preminger GM. Clinical effectiveness protocols for imaging in the management of ureteral calculous disease: AUA technology assessment. *J Urol.* 2013; 189(4):1203-13.
14. Türk C, Petřík A, Sarica K, Seitz C, Skolarikos A, Straub M, Knoll T. EAU Guidelines on Interventional Treatment for Urolithiasis. *Eur Urol.* 2016; 69(3):475-82
15. Brisbane W, Bailey MR, Sorensen MD. An overview of kidney stone imaging techniques. *Nat Rev Urol.* 2016; 13(11):654-662.
16. Kanno T, Kubota M, Sakamoto H, Nishiyama R, Okada T, Higashi Y, et al. The efficacy of ultrasonography for the detection of renal stone. *Urology.* 2014; 84(2):285-8.
17. Smith-Bindman R, Aubin C, Bailitz J, Bengiamin RN, Camargo CA Jr, Corbo J, et al. Ultrasonography versus computed tomography for suspected nephrolithiasis. *N Engl J Med.* 2014;371(12):1100-10.