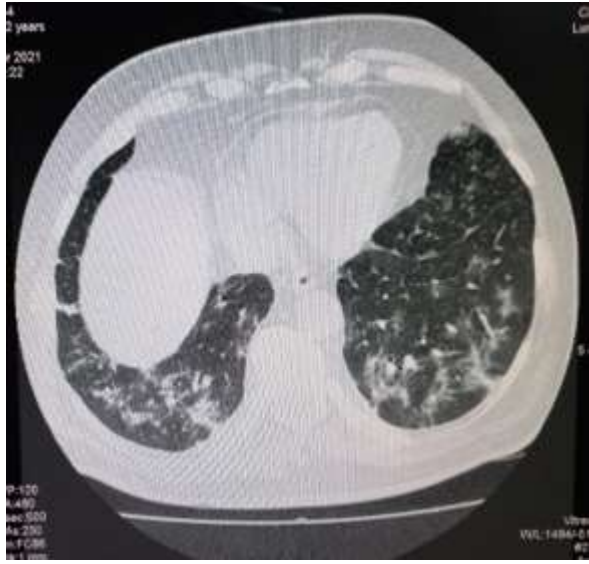
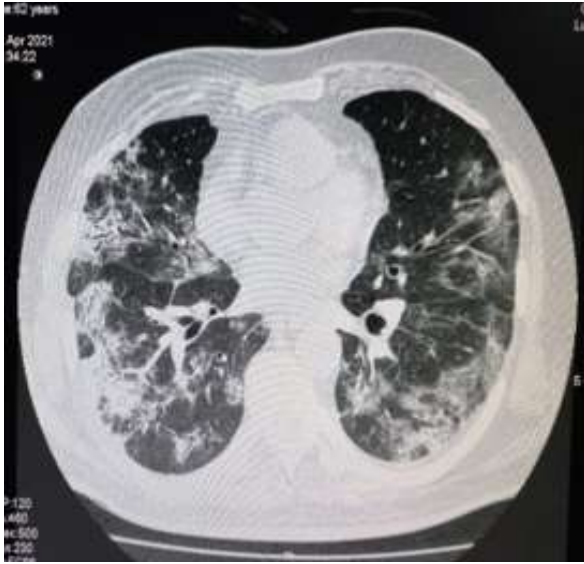
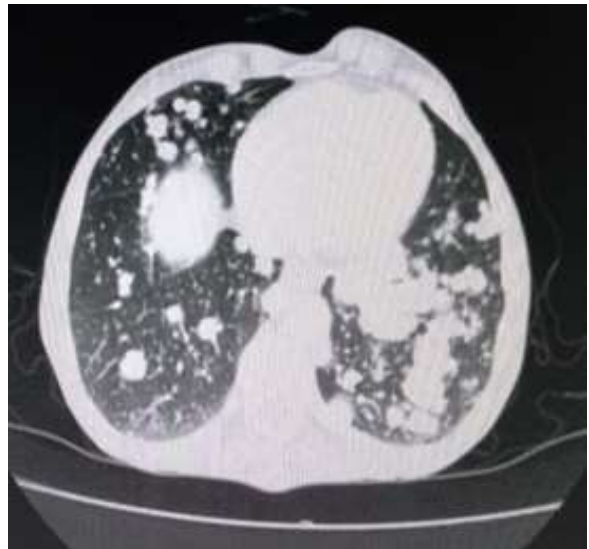
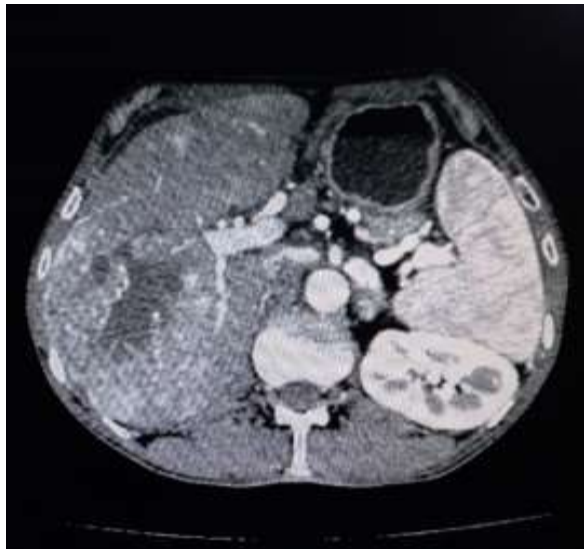# Radiological Images

## Post Covid Fibrosis



## Hepatocellular Carcinoma with Pulmonary Metastases



**Contributed by:**

*Department of Radiology  
Dr. Akbar Niazi Teaching Hospital, Islamabad*