

## Evaluation of the Occlusal Contact between the Opposing Teeth and the Cusp of Carabelli in Maxillary Permanent First Molars in Patients Visiting Peshawar Dental College

Sana Arbab <sup>1</sup>, Munawar Aziz Khattak <sup>2</sup>, Imran Khattak <sup>3</sup>, Yusra Jamil <sup>4</sup>, Faiza Ijaz <sup>5</sup>, Ambereen Hamayun <sup>6</sup>

<sup>1</sup>Assistant Professor, Department of Oral Biology, Peshawar Dental College, Peshawar- Pakistan

<sup>2</sup>Associate Professor, Department of Oral Biology, Peshawar Dental College, Peshawar- Pakistan

<sup>3</sup>Assistant Professor, Department of Oral Biology, Peshawar Dental College, Peshawar- Pakistan

<sup>4</sup>Assistant Professor, Department of Oral Biology, Rashid Latif Medical and Dental College, Lahore- Pakistan

<sup>5</sup>Assistant Professor, Department of Oral Biology, Ayub College of Dentistry, Abbottabad, Pakistan

<sup>6</sup>Assistant Professor, Department of Anatomy, Peshawar Medical College, Peshawar- Pakistan

### ABSTRACT

**Background:** The Cusp of Carabelli is a small additional cusp which is situated on the mesiopalatal surface of first maxillary molars. This nonfunctional cusp comes in many forms including furrows, ridges or pits and is collectively known as the Carabelli trait

**Objective:** To evaluate the frequency of the occlusal contacts between the accessory cusp of Carabelli and the opposing arch tooth among both genders in patients attending the out-patients department of Peshawar Dental Hospital, Peshawar

**Methodology:** This descriptive cross-sectional study was conducted on 300 subjects visiting the OPD of Peshawar Dental Hospital from October 2022 to December 2022. The sample size was calculated using WHO formula  $N = \frac{p(100-p)z^2}{d^2}$  (Http://www.fao.org The age group selected for the participants was from 13-30 years. Consecutive sampling technique was used.). Articulating paper was used to assess the occlusal contacts caused by the cusp of Carabelli. The data were analyzed using SPSS version 20. Pearson's chi square test was applied to analyze the data. P value of  $\leq 0.05$  was considered statistically significant.

**Results:** The results of the current study showed that 10.7% of the participants experienced occlusal contacts caused by the presence of their accessory cusp with the opposing arch tooth with no statistically significant difference between genders.

**Conclusion:** The cusp of Carabelli is the most prevailing variation found on the palatal aspect of mesiopalatal cusp of permanent maxillary first molars in a hospital-based inhabitants of Peshawar with rare occlusal contacts experienced by the patients.

**Key words:** Cusp of Carabelli, Maxillary permanent first molars, Occlusal contact.

#### Authors' Contribution:

<sup>1,2</sup>Conception; Literature research;

<sup>3</sup>manuscript design and drafting; <sup>4,5</sup>Critical analysis and manuscript review; <sup>6</sup>Data

analysis; Manuscript Editing.

#### Correspondence:

Sana Arbab

Email: Sarbab33@yahoo.com

#### Article info:

Received: March 11, 2022

Accepted: March 30, 2023

**Cite this article.** Arbab S, Khattak M A, Khattak I, Jamil Y, Ijaz F, Hamayun A . Evaluation of the Occlusal Contact between the Opposing Teeth and the Cusp of Carabelli in Maxillary Permanent First Molars in Patients Visiting Peshawar Dental College. J Islamabad Med Dental Coll. 2023; 12(1):17-22

DOI: <https://doi.org/10.35787/jimdc.v12i1.855>

**Funding Source:** Nil

**Conflict of Interest:** Nil

## Introduction

Morphological variations exist in both primary and permanent teeth which can be expressed in crown and roots.<sup>1,2</sup> Accessory cusps including cusp of Carabelli, Talon cusp, central cusp, Leong's tubercle are the frequent occurrences.<sup>2,3</sup> Cusp of Carabelli account for 52-68% in molars more frequently maxillary first molars and is located lingual to the mesiopalatal cusp of maxillary first permanent molars.<sup>4</sup> It may also be found in second and third molars but less frequently.<sup>4</sup>

The development of this cusp is usually attributed to certain genetic or environmental factors however the exact etiology is unknown and these accessory cusps are attributed to different growth patterns.<sup>5</sup> Moreover the occurrence of the cusp of Carabelli may be due to the overactivity of dental lamina due to a genetic influence.<sup>6</sup> Its size ranges from a large prominent cusp to a rudimentary eminence.<sup>7</sup> Certain vitamins, nutrients or size of the jaws may also contribute to the development of this cusp.<sup>8</sup>

A study conducted in Mardan showed that 32% of the study population had cusp of Carabelli on permanent maxillary first molars.<sup>9</sup> Another study conducted on a local population of Peshawar showed an overall frequency of the cusp of Carabelli to be 39.3% in permanent maxillary first molars.<sup>10</sup>

The clinical significance of cusp of Carabelli and other accessory cusps is that they may cause some clinical disturbances such as occlusal interferences, esthetic problems, accidental cusp fracture, carious lesion in cusp of Carabelli groove and irritation of tongue during speech and mastication etc.<sup>11,12</sup> The occlusal contacts between the accessory cusps and opposing teeth cause attritional wear which are characterized by smooth and polished delineated areas known as wear facets.<sup>13</sup> Moreover, these occlusal contacts occur when the maxillary molars occlude with the lingual slopes of mandibular molars.<sup>14</sup> These premature contacts caused by the accessory cusps occur because of their abnormal morphology and location.<sup>15</sup> Adequate assessment of

occlusion is necessary for achieving proper mastication and functioning of masticatory apparatus. However, any irregular occlusal contacts can lead to various clinical symptoms such as migration of teeth, cracked enamel, gingival recession, fracture of restorations or prosthesis, diseases of TMJ and orofacial pain.<sup>16</sup> The occlusal contacts can be clinically detected by two methods such as by using articulating papers or waxes and impression materials.<sup>17</sup>

The main objective of the study was to determine the frequency of the occlusal contacts between the accessory cusp of Carabelli and the opposing arch tooth among both genders in patients coming to the OPD of Peshawar Dental Hospital, Peshawar.

## Methodology

This cross-sectional was conducted in Peshawar Medical & Dental College from October 2022 to December 2022. A total of 300 patients were included in the study through convenient sampling technique. The sample size was calculated using WHO formula  $N=p(100-p)z^2/d^2$  ([Http://www.fao.org](http://www.fao.org)). Approval of the study was done by Ethical Review Committee of Peshawar Medical & Dental College. All the included participants were informed (written consent: Annexure B) about the purpose of the study.

Two teeth per patient (600 in total) were examined. Inclusion criteria set for the study was: both genders having complete eruption of permanent maxillary first molars bilaterally, age group 13-30 years, sound non-carious, no attrition or erosion or any dental disease deteriorating the morphology of permanent maxillary first molars were included in the study.

Patients having any congenital dental disease, carious or restored permanent maxillary first molars detected clinically delineating their morphology or any prosthesis/orthodontic appliance on maxillary permanent first molars were excluded.

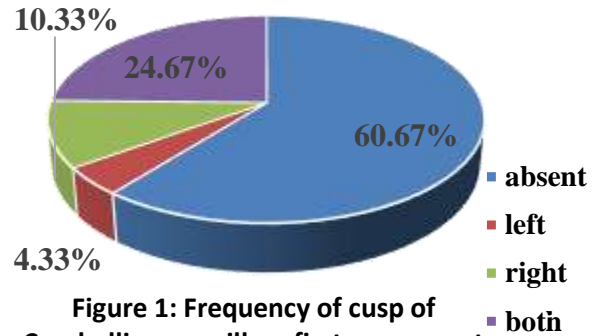
A proforma (Annexure A) was made to document the data of patients. An intraoral examination of the participants' permanent maxillary first molars was carried out by seating them in dental chair under proper illumination and assessing the teeth with the help of mouth mirror. Dental explorer was used to detect any carious lesion on maxillary permanent first molars. All the observations were made by the author herself and no other observer was involved thus excluding interobserver variability.

Articulating paper was placed between the mesiopalatal surface of maxillary permanent first molars and the occlusal surface of mandibular first molars to detect occlusal contact caused by the cusp of Carabelli and the patients were instructed to bite on the paper while opening and closing the jaws (centric relation). Articulating paper was then removed and the teeth were evaluated. A mark on the cusp of Carabelli or opposing arch tooth left by the paper indicated that the cusp does have contact with the opposing tooth of the patient. In case the paper left no mark showed that the cusp of Carabelli did not interfere with occlusion. The data were analyzed using SPSS version 22. Pearson's Chi-Square test was used for data analysis. A p-value  $\leq 0.05$  to be considered statistically significant.

## Results

Out of 300 participants, males accounted for 125 (41.7%) while females were 175 (58.3%) in number. The total number of teeth examined were 600 (two maxillary permanent first molars per patient). The candidates fell in age group 13-30 years having a mean age of  $22.46 \pm 5.1$  years. The current research depicts an overall frequency of cusp of Carabelli to be 39.3% (Fig 1). A p value of 0.140 showed no significant relationship between genders for the distribution of the cusp (Table 1). The Total number of patients who had occlusal interference with cusp of Carabelli and the opposing arch teeth were 10.7% (Table 2). Occlusal contacts caused due to cusp of

Carabelli found on the permanent maxillary first molars with their opposing arch teeth was present in 4% of the patients on right side, 2.7% patients on the left side and 4% on both right and left molars. Statistical analysis showed no significant difference between males and females (p value 0.615) (Table 3).



**Figure 1: Frequency of cusp of Carabelli on maxillary first permanent molars**

Gender	CC Absent in patients N (%)	CC Present in patients			Total N (%)
		Right N (%)	Left N (%)	Both N (%)	
Male	83(45.6)	12 (38.7)	7 (53.8)	23 (31)	125 (41.6)
Female	99 (54.3)	19 (61.2)	6 (46.1)	51 (68.9)	175 (58.3)
Total	182 (100)	31(100)	13 (100)	74(100)	300 (100)

P value = 0.140 as calculated by Pearson's chi square test. df = 3. Total number of patients having CC: Males = 42 (35.5%), Females = 76 (64.4%)

**Table II: Occlusal contact (OC) of cusp of Carabelli with opposing arch tooth**

Occlusal contact associated with Cusp of Carabelli		Number of patients having OC N (%)	Total number of patients having occlusal contacts N(%)
Absent		268 (89.3)	
Present	Right	12 (4.0)	32(10.7%)
	Left	8 (2.7)	
	Both	12 (4.0)	
Total		300 (100)	

**Table III: Gender-wise distribution of occlusal contact of cusp of Carabelli with opposing tooth**

Gender	OC Absent in patients N (%)	OC Present in patients			Total N (%)
		Right N (%)	Left N (%)	Both N (%)	
Male	113 (42.1)	3 (25.0)	3 (25.0)	6 (50.0)	125 (41.6)
Female	155 (57.8)	9 (75.0)	5(62.5)	6(50.0)	175 (58.3)
Total	268 (100)	12 (100)	8 (100)	12 (100)	300 (100)

P= 0.615 as calculated by Pearson's chi square test. df = 3. Total number of patients having OC caused by CC in MPFM; Males = 12 (37.5%), Females = 20 (62.5%).

## Discussion

Cusp of Carabelli is the most frequently occurring accessory cusp found on the permanent maxillary first molars.<sup>1-3</sup> A number of researches have been put forth on the frequency, types or clinical significance of the cusp of Carabelli, however, the current study emphasizes upon the occlusal contacts caused by the cusp of Carabelli with their opposing arch teeth. These accessory cusps sometimes manifest themselves as larger tubercles which may interfere with occlusion with the opposing arch tooth.

The results of the present survey revealed a frequency of cusp of Carabelli occurring on permanent maxillary first molars to be 39.3% (Fig 1) which is in concurrence with the findings of Arbab et al<sup>10, 11</sup> and 32% prevalence was reported in a local population of Mardan with unilateral presentation more common.<sup>9</sup> A prevalence of 25% was reported in Kashmiri population.<sup>2</sup> Other studies revealed no accordance with the findings of the present study. The frequency of the cusp of Carabelli was found to be 87% in a racially mixed population from Begaluru<sup>19</sup>, 72% in Madurai population<sup>20</sup>, 68.3% in Nepalese population,<sup>21</sup> and 53.5% in a population of Multan.<sup>25</sup> However, a study conducted by Bhavyaa et al reported a frequency of cusp of Carabelli to be 90.6% in deciduous maxillary second molars among 3-4 years old children<sup>22</sup> while the same authors conducted a meta-analysis which showed that the cusp of Carabelli was found in 59% of the overall participants.<sup>18</sup>

The participants of the current study did not show a significant difference in gender distribution of the cusp as shown by p value 0.140 (Table 1) which is similar to the findings of Arbab et al<sup>10,11</sup> and Zafar et al<sup>25</sup> whereas other studies recruited on our local population<sup>9</sup> showed male predominance.

Cusp of Carabelli rarely causes occlusal contacts with the opposing arch tooth as shown by frequency in the contemporary group of 10.6% (Table 2). These findings go against the experimentations done by Cakan et al<sup>23</sup> and Elhag et al<sup>24</sup> who reported no occlusal interference caused by the accessory cusp. According to the findings of current study gender differentiation of the cuspal contacts showed no statistically significant difference (P value 0.615) (Table 3).

There were certain limitations of the study such as single centered study, dental casts were not obtained from the participants due to ethical issues.

## Conclusion

1. The cusp of Carabelli is a frequent finding on the palatal surface of mesiopalatal cusp of permanent maxillary first molars in a local population of a hospital-based society in Peshawar having an overall prevalence of 39.3%.

2. Rare occlusal contacts were experienced by the patients having cusp of Carabelli.

## References

1. Sarpangala M, Devasya A. Occurrence of Cusp of Carabelli in Primary Second Molar Series of three Cases. *J Clin Diagn* 2017; 11(3): 01-02. DOI: 10.7860/JCDR/2017/24040.9340
2. Hassan S, Nadaf A, Raina R. The Prevalence of Cusp of Carabelli Among Kashmiri Population. *J Adv Med Dent Scie Res*, 2020; 8(1):42-44.
3. Chowdhary Z, Gupta D, Mohan R, Bajaj A. Parastyle Cusp: A Rare Morphologic Variation of Maxillary Second Molars. *J Forensic Dent Sci*, 2018;10:111-5
4. Scheid RC. *Woelfl's Dental Anatomy: Its relevance to dentistry*. 7<sup>th</sup> edition 2017. Maryland: Lippincott Williams and Wilkins.
5. Algemy AO, Barak AA, Saed GM, Fheelbhoom HA, Aljotri AA. Variations in Occlusal Morphology Of Permanent Maxillary First Molars In Zawia Population: A Comparative Study. *University Bulletin*, 2022;24(2):222-234.
6. Owens BM, Blen BJ, Redmond DC. Cusp of Carabelli: Observations of an odontogenic trait. *Gavin J Dent Sci* 2016; 2016: 1-7.
7. Niazi M, Najmi Y, Qadri M. Frequency of cusp of Carabelli in orthodontic patients reporting to Islamabad. *Pak Orthod J*, 2016; 8(2): 85-88.
8. Cruz CV, Soares LA, Braga DN, Costa CM. Diagnosis and Surgical Management of Nonsyndromic Nine Supernumerary Teeth and Leong's Tubercle. Case reports in Dentistry. 2016. <https://doi.org/10.1155/2016/8641867>
9. Qamar W, Qayum M, Ali A, Idrees S. Frequency and trends of cusp of Carabelli in maxillary first molars of patients visiting dental teaching hospital in Mardan, Pakistan. *Pak Orthod J*, 2018; 10(1): 27-29.
10. Arbab S, Khattak MA, Khattak I, Rashid M. The Frequency Of Unilateral And Bilateral Distribution Of Cusp Of Carabelli In Maxillary Permanent First Molars In Patients Visiting Peshawar Dental Hospital, Peshawar. *Med Forum Mon* 2022; 33(2):165-168
11. Arbab S, Khattak MA, Shah SA. Frequency of cusp of Carabelli in maxillary permanent first molars and its association with dental caries in patients visiting Peshawar Dental Hospital, Peshawar. *Professional Med J*, 2021; 28(8): 1101-1106.
12. Smitha T, Venkatesh D, Veeresh M, Hema KN, Sheethal HS, Vidya MA. The cusp of Carabelli: Frequency, distribution and type in the Bengaluru population. *J Oral Maxillofac Pathol*, 2018, 22(3):418-422
13. JS Rees, S Somi. A guide to the clinical management of attrition. *Br Dent J*, 2018; 224: 319-323.
14. Florenza L, Kullmer O. The functional role of the Carabelli trait in early and late hominins. *J Hum Evol*, 2020. 145.
15. Jain S. Variation In cuspal morphology in maxillary first permanent molar with report of 3 cusp molar. *J Clin Diagn Res*, 2016;10(9):ZC34-ZC36.
16. Bozhkova T, Musulieva N, Slavchev D, Dimitrova M, Rimalovska S. Occlusal indicators used in dental practice: A survey study. *BioMed Res Int*, 2021;2021.
17. Warreth A, Doody K, Mo O, Mohsen MA. Fundamentals of occlusion and restorative dentistry. Part II: Occlusal contacts, interferences and occlusal considerations in implant patients. *J Ir Dent Assoc*, 2015; 61(5): 252-259.
18. Ranka B, Muthu MS, Nirmal L, Ponraj S. Prevalence of Cusp Of Carabelli: A Systematic Review and Meta Analysis. *Ann Hum Biol*, 2022; 48(7-8):1-29.
19. Venkatesh D, Sanchitha V, Smitha T, Sharma G, Gaonkar S, Hema KN. Frequency and variability of five non metric dental crown traits in the permanent maxillary dentitions of a racially mixed population from Bengaluru, Karnataka. *J oral Maxillofac Pathol*, 2019; 23(3): 458-465.
20. Saravanan R. Prevalence of cusp of Carabelli in Madurai population. *Int J Rec ent Sci Res*, 2020; 11(6): 38805-38807.
21. Subedi N, Sah S, Chataut TP, Paudel S, Pradhan A. Prevalence of Carabelli trait in selected Nepalese population. *Br J Med Med Res* 2014; 7(4): 285-91.
22. Bhavyaa R, Sujitha P, Muthu MS, Kithiga M. Prevalence of Cusp of Carabelli and its caries susceptibility - an ambidirectional cohort study. *Aust Dent J* 2020; 65(4): 294-301.
23. Cakan DG, Ulkur F, Taner T. The genetic basis of dental anomalies and its relation to Orthodontics. *Eur J Dent*, 2013 7(1); 143-47.
24. Elhag SBI, Abdulghani ASI, Elhag BI. Concomitant mesiodens with cusp of Carabelli on upper first molars; A rare case report. *Dent Oral Craniofacial Res*, 2015 1: doi: 10.15761/DOCR.1000142.
25. Zafar R, Shakoor A, Haider MU, Muhammad U, Baloch N. The presence/absence of cusp of Carabelli in patients presenting to the dental outdoor department in a teaching hospital in Multan, Pakistan. *Professional Med J*, 2023; 30(3): 281-284.

