

Vision Loss following Small Incision Cataract Surgery: A Case Report

Sushma Chaudhary,^{a,c} Sharad Gupta,^{b,c} Sanjaykumar Singh,^{b,c} Hari Sharma,^{b,d}
Reena Yadav,^{b,c} Vinit Kumar Kamble^{b,c}

ABSTRACT:

Introduction: Retro-bulbar block is still safe and widely employed anesthetic technique in large volume routine cataract surgery. Nevertheless, the procedure is not free of complication. **Case report:** A 48 years old man who had small incision cataract surgery of left eye under retro-bulbar block, had vision of hand movement close to face on his first postoperative day. He was given intracameral cefuroxime and subconjunctival gentamycin at the end of the surgery. Fundoscopy of the operated eye showed marked retinal whitening with cherry red spot in the posterior pole suggestive of cilio-retinal artery occlusion. Optical coherence tomography and optical coherence tomography angiography were done to support and confirm the diagnosis. **Conclusion:** Retinal artery occlusion secondary to retro-bulbar block or drug induced toxicity following routine cataract surgery is unusual and sometimes dreadful vision threatening complication can occur.

Keywords: Optical Coherence Tomography Angiography ; Retinal Artery Occlusion; Retrobulbar anesthesia

INTRODUCTION:

With regard to subtenon, topical and peribulbar anesthesia, retrobulbar anesthesia is still commonly employed anesthetic technique for high volume intraocular surgery. However, the technique is not free of complications. Retrobulbar injection is given at the junction of medial two-third and lateral one-third of the inferior orbital margin using a 26-gauge, 35 mm retrobulbar needle (4 ml of 2% lignocaine with adrenaline 1:100,000 dilution) into the retrobulbar space which contains vascular and neural structures.[1] Few literature reported that globe perforation, retrobulbar hemorrhage, central retinal artery occlusion and combined central retinal artery occlusion with central retinal vein occlusion are some of the complications that may

compromise vision.[2,3] Possible mechanism for those complications would be due to direct trauma to the optic nerve along with mechanical effect of the bolus anesthetic and pharmacologically mediated changes in the vascular caliber.[4]

Here we report a case of cilioretinal artery occlusion following routine small incision cataract surgery under retro-bulbar anesthesia.

CASE REPORT:

A 48 years old male presented with painless progressive diminution of vision in the left eye for last six months. His visual acuity was 6 /12 in the right eye and 6/60 in the left eye. Visual acuity improved to 6/6 and 6/12 after best refractive correction. Patient had cataract surgery in his right eye two years ago. Pupillary reactions (direct and consensual) were normal in both eyes. On slit-lamp biomicroscopic examination anterior and posterior segment except intra-ocular lens in the right eye and nucleus sclerosis grade 2 in the left eye was

Submitted: 16 July, 2020

Accepted: 20 September, 2020

Published: 15 May, 2021

a- Optometrist,

b- Consultant Ophthalmologist,

c- Sagarmatha Choudhary Eye Hospital, Siraha, Lahan, Nepal.

d- Dristi Eye Hospital, Birgunj, Nepal.

Corresponding Author:

Sushma Chaudhary

e-mail: chaudharysushma169@gmail.com

ORCID: <https://orcid.org/0000-0002-5061-652X>

How to cite this article:

Chaudhary S, Gupta S, Singh S, Sharma H, Yadav R, Kamble VK. Vision Loss following Small Incision Cataract Surgery: A Case Report. *Journal of Lumbini Medical College*. 2021;9(1):4 pages. DOI: <https://doi.org/10.22502/jlmc.v9i1.390>. Epub: 2021 May 15.



Licensed under CC BY 4.0 International License which permits use, distribution and reproduction in any medium, provided the original work is properly cited.

unremarkable. Intraocular pressures were 15 mmHg in the right eye and 16 mmHg in the left eye. His physical examination was normal and systemic history was not significant. A diagnosis of right eye pseudophakia and left eye nucleus sclerosis grade 2 was made. The patient was merited for left eye small incision cataract surgery. Topical ciprofloxacin 0.3 % was instilled before surgery and 4 ml of 2% lignocaine in 1: 100000 adrenaline was injected via retrobulbar route (inferior approach) for anesthesia. After anesthesia the eye was usually compressed with palm for 10-15 minutes. Under aseptic condition small incision cataract surgery with intraocular lens implantation in bag was done. At the end of surgery intracameral cefuroxime (1 mg/0.1 ml) along with subconjunctival injection gentamycin (20 mg in 0.5ml) and dexamethasone (0.2 mg in 0.5 ml) was given.

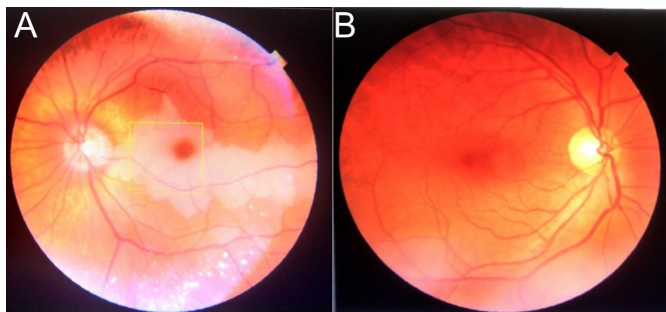


Figure 1. A- Left fundus showing pale retina in the posterior pole along with cherry red spot. B-Normal right fundus.

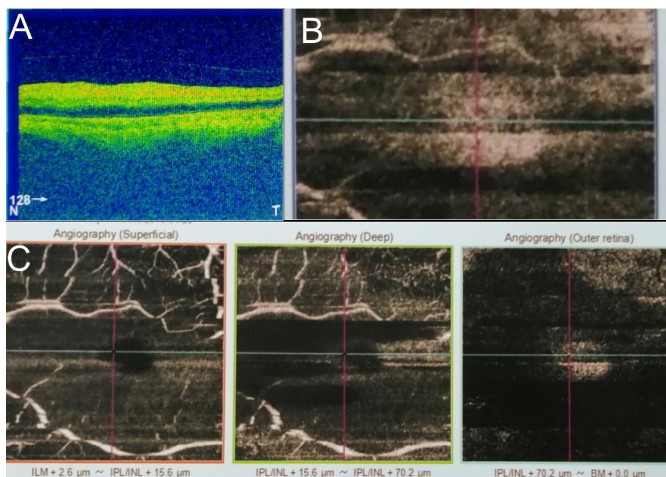


Figure 2. A- Optical coherence tomography images of posterior segment of the left eye- The horizontal cross-sectional image demonstrates increased reflectivity and thickness of the inner retinal layers, but decreased reflectivity in the outer retinal layer. Beneath the fovea, there is an area of normal reflectivity of the IS/OS line and RPE layer. B, C- OCT of posterior of the left eye showed superficial and deep plexus with loss of flow in the capillary network of the occluded area.

On the first postoperative day his best corrected visual acuity in the operated eye was hand movement close to face. Anterior segment examination of operated eye had clear cornea, inflammatory reaction (2-3+ cells) in the anterior chamber, intraocular lens in bag and relative afferent pupillary defect (RAPD) was noted. Under mydriasis, examination of the left fundus revealed whitening of the retina at the posterior pole with cherry red spot suggestive of cilioretinal artery occlusion (Fig 1A) whereas fundus examination of the right eye was normal (Fig 1B). Intraocular pressure was 16 mmHg in each eye by noncontact air puff tonometer. No proptosis or other signs of retrobulbar hemorrhage were noted. Swept source optical coherence tomography and optical coherence tomography angiography was performed to confirm the diagnosis (Fig 2A and B) whereas it was normal in the right eye (Fig 3A and B). He was treated with oral carbonic anhydrase inhibitors. Laboratory and cardiac assessment was found to be within normal limit. Patient was discharged on topical steroid and antibiotic eye drops. Patient was advised for follow up after one month.

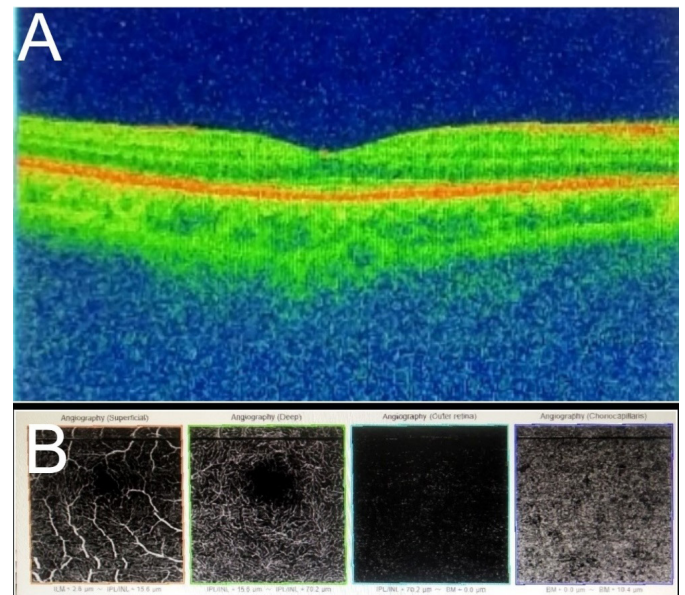


Figure 3. A- Normal OCT images of posterior segment of the right eye. B- Normal OCT-A posterior segment of the right eye.

DISCUSSION:

Retinal artery occlusions (RAO) are most commonly a result of embolic obstruction which might be of carotid or cardiac origin, vaso-obliteration and vascular compression.[5] Though retinal vascular accident secondary to retrobulbar anes-

thesia is rare but damage to the optic nerve, artery or vein via various mechanism (direct trauma, mechanical compression or drug toxicity) still occurs. [4] Klein ML et al., and Morgan CM et al., stated that the probable mechanism for CRAO would be direct trauma to the retinal artery along with retrobulbar hemorrhage associated with marked rise of orbital IOP.[4,6] The most probable hypothesis for combined retinal vein and artery occlusion would be injection into the optic nerve sheath and optic nerve sheath hematoma.[3,6] Our patient had received intracameral cefuroxime and subconjunctival gentamycin at the end of the surgery. Some literatures reported that the use of intracameral cefuroxime and subconjunctival gentamycin could prevent from severe and feared complications like endophthalmitis.[7,8] But use of these drugs can also lead to blinding complications such as macular ischemia and infarction.[9,10,11,12]

Our patient was diagnosed as a case of cilioretinal artery occlusion based on clinical finding of fundus and confirmed by OCTA. In our patient the most possible hypothesis for cilioretinal artery occlusion would be mechanical effect of the volume of anesthetic agent and its vasoconstrictive properties that mediated changes in the vascular caliber. Intracameral cefuroxime and subconjunctival gentamycin induced macular infarction would be another probable hypothesis.

CONCLUSION:

Cataract surgery is most common ocular surgery. Even routine and uneventful cataract surgery is associated with severe unfavorable outcomes. Retinal artery occlusion secondary to retro-bulbar block or drug induced toxicity following routine cataract surgery is unusual and sometimes dreadful vision threatening complication can occur.

Conflict of Interest: The authors declare that no competing interests exist.

Financial disclosure: No funds were available.

REFERENCES:

1. Katsev DA, Drews RC, Rose BT. An anatomic study of retrobulbar needle path length. *Ophthalmology* 1989;96(8):1221-4. DOI: [https://doi.org/10.1016/s0161-6420\(89\)32748-5](https://doi.org/10.1016/s0161-6420(89)32748-5)
2. Jung EH, Park KH, Woo SJ. Iatrogenic central retinal artery occlusion following retrobulbar anesthesia for intraocular surgery. *Korean J Ophthalmol.* 2015;29(4):233-40. PMID:26240507 DOI: <https://doi.org/10.3341/kjo.2015.29.4.233>
3. Vasavada D, Bhaskaran P, Seema R. Retinal Vascular Occlusion Secondary to Retrobulbar Injection: Case Report and Literature Review. *Middle East Afr J Ophthalmol.* 2017;24(1)57-60. PMID: 28546695 DOI: https://doi.org/10.4103/meajo.meajo_37_16
4. Klein ML, Jampol LM, Condon PI, Rice TA, Serjeant GR. Central retinal artery occlusion without retrobulbar hemorrhage after retrobulbar anesthesia. *American Journal of Ophthalmology.* 1982;93(5):573-7. DOI: [https://doi.org/10.1016/S0002-9394\(14\)77371-4](https://doi.org/10.1016/S0002-9394(14)77371-4)
5. Körner-Stiefbold U. Central retinal artery occlusion (CRAO) - etiology, clinical signs and management. *Therapeutic Umschau.* 2001;58(1):36-40. DOI: <https://doi.org/10.1024/0040-5930.58.1.36>
6. Morgan CM, Schatz H, Vine AK, Davidorf FH, Gitter KA, Rudich R. Ocular complications associated with retrobulbar injections. *Ophthalmology.*1988;95(5):660-5. PMID: [3174025](https://pubmed.ncbi.nlm.nih.gov/3174025/) DOI: [https://doi.org/10.1016/s0161-6420\(88\)33130-1](https://doi.org/10.1016/s0161-6420(88)33130-1)
7. Yorston D. Using intracameral cefuroxime as a prophylaxis for endophthalmitis. *Community Eye Health.* 2008;21(65):11. PMID: [18504469](https://pubmed.ncbi.nlm.nih.gov/18504469/) PMID: <http://www.ncbi.nlm.nih.gov/pmc/articles/pmc2377382/>
8. Fintelmann RE, Naseri A. Prophylaxis of postoperative endophthalmitis following cataract surgery: current status and future directions. *Drugs.* 2010;70(11):1395-409. PMID: [20614947](https://pubmed.ncbi.nlm.nih.gov/20614947/) DOI: <https://doi.org/10.2165/11537950-000000000-00000>
9. Campochiaro PA, Conway BP. Aminoglycoside Toxicity - - A Survey of Retinal Specialists: Implications for Ocular Use. *Arch*

Ophthalmol.1991;109(7):946-50. [PMID: 2064573](#) DOI: <https://doi.org/10.1001/archophth.1991.01080070058035>

10. Murao F, Kinoshita T, Katome T, Sano H, Niki M, Mitamura Y. Suspected Gentamicin-Induced Retinal Vascular Occlusion after Vitrectomy. Case Reports Ophthalmology. 2020;11(2):473-80. DOI: <https://doi.org/10.1159/000509337>
11. Cardascia N, Boscia F, Furino C, Sborgia L. Gentamicin-induced macular infarction in transconjunctival sutureless 25-gauge vitrectomy. Int Ophthalmol. 2008;28(5):383-5. [PMID: 17938870](#) DOI: <https://doi.org/10.1007/s10792-007-9148-4>
12. Quresh F, Clark D. Macular infarction after inadvertent intracameral cefuroxime. Journal of Cataract and Refractive Surgery. 2011;37(6):1168-9. DOI: <https://doi.org/10.1016/j.jcrs.2011.03.032>