

# Sex Determination from Radiological Assessment of the Sacrum in Nepalese Population: A Cross-sectional Study

Subina Shrestha,<sup>a,c</sup> Sudikshya KC,<sup>a,d</sup> Sumnima Acharya<sup>b,c</sup>

## ABSTRACT:

**Introduction:** Human skeleton shows variable degree of sexual dimorphism, but definitive inference can be obtained from only a few bones, sacrum being one of them. The morphometric differences of the bone will be helpful to obstetricians, as it shows special adaptations in females for child bearing. It is also important for physical anthropologists and forensic scientists for sex determination. The aim of this study was to find out whether sex could be determined by using sacral parameters from X-ray images of pelvis. **Methods:** The study included antero-posterior X-ray images of pelvis with clearly visible 680 sacra (311 of males and 369 of females) obtained by computer generated random numbers from records in the Department of Radiodiagnosis of a medical college in Nepal. X-ray images with the sacrum suspected for fractures and pathological diseases were excluded. Inbuilt software “CR Konica Minolta Aero DR/CR CS7” was used for measurements. **Results:** The mean sacral length and mean transverse diameter of S1 vertebra were higher in males; whereas, mean sacral breadth, mean left ala length, mean right ala length, mean ala length, mean sacral index and mean alar index were higher in females. These differences in sacral parameters between the two sexes were statistically significant ( $p < 0.05$ ). The percentage of bones identified by demarking points of sacral index was 15.17% and 0.32% respectively in the males and the females. **Conclusion:** The result of the present study supported determination of sex of an individual from radiological assessment of sacrum.

**Keywords:** Anthropology, Radiology, Sacrum, Sex

## INTRODUCTION:

Determination of sex, age, height and ethnic background of an individual contributes to identification of the individual. All elements of human skeleton show variable degree of sexual dimorphism, but definitive inference can be obtained from only a few bones, sacrum being one of them.[1] Sacrum is a large single triangular irregular bone made up of five rudimentary vertebrae. It is the wedge between two

hip bones and forms the posterior superior wall of pelvic cavity. Sacrum also shows special adaptations in females for child bearing, thus its morphometric features form important obstetric landmarks.[2]

To the best of our knowledge, determination of sex from sacrum using radiographs in Nepalese population has not been carried out till date. The aim of the present study was to study the morphometric differences of sacral parameters as determinant of sexual dimorphism using antero-posterior X-ray images of pelvis. This study will be helpful to obstetricians, physical anthropologists and forensic scientists.

**Submitted:** 28 July, 2020

**Accepted:** 9 December, 2020

**Published:** 22 December, 2020

a- Lecturer, Department of Anatomy,

b- Assistant Professor, Department of Radiodiagnosis,

c- Lumbini Medical College, Palpa, Nepal.

d- Nepalese Army Institute of Health Sciences, Kathmandu, Nepal.

## Corresponding Author:

Subina Shrestha

e-mail: [ssubina8@gmail.com](mailto:ssubina8@gmail.com)

ORCID: <https://orcid.org/0000-0002-0006-4974>

## How to cite this article:

Shrestha S, KC S, Acharya S. Sex Determination from Radiological Assessment of the Sacrum in Nepalese Population: A Cross-sectional Study. *Journal of Lumbini Medical College*. 2020;8(2):259-263. DOI: <https://doi.org/10.22502/jlmc.v8i2.393> Epub: 2020 December 22.



Licensed under CC BY 4.0 International License which permits use, distribution and reproduction in any medium, provided the original work is properly cited.

## METHODS:

This was a cross-sectional study conducted in June and July 2020 in the Department of Radiodiagnosis, Lumbini Medical College and Teaching Hospital (LMCTH), Nepal. The ethical clearance was obtained from Institutional Review Committee (IRC-LMC12-CD/020).

Sample size was calculated by using the formula,

$$\text{Sample size } n = \frac{(Z_{\alpha} \sigma)^2}{d^2}$$

Where,

n= desired sample size

Z= 1.96 (Standard value at 95% confidence interval)

d= 0.05 (Margin of error),  $\alpha$ =level of significance

$\sigma = 0.66$ [3]

Thus, the required sample size was 680.

This study included the records of antero-posterior (AP) X-ray images of pelvis with clearly visible 680 (311 of males and 369 of females) sacra of Nepalese people. First, all the available X-ray images that fulfilled inclusion criteria were identified and serial numbers were given; then the sample was chosen by computer generated random numbers. X-ray images with the sacrum suspected for fractures and pathological diseases were excluded.

The radiographs had been taken by "Allengers X Ray machine" and further developed by CR system- Konica minolta. Inbuilt software "CR Konica Minolta Aero DR/CR CS7" was used for the measurements. Following measurements (in millimeters) were taken as shown in Figure 1.

- Length of the sacrum (I to J): This measurement was taken from midpoint of sacral promontory to anterior inferior margin of the 5<sup>th</sup> sacral vertebra.
- Breadth of sacrum (E to H): It was measured by taking two points, each at the lateralmost part of each ala on anterior aspect of the sacrum.
- Transverse diameter of the body of the first sacral vertebra (S1) (F to G): This was measured by taking the lateralmost point on each side of the superior surface of the body of S1 vertebrae.
- Length of the right ala (E to F): This was

measured from the most right lateral point on the superior surface of the body of S1 vertebra to the most lateral point of right ala of sacrum.

- Length of the left ala (G to H): This was measured from the most left lateral point on the superior surface of the body of S1 vertebra to the most lateral point of left ala of sacrum.
- Mean alar length = (Length of the left ala + Length of the right ala)/2

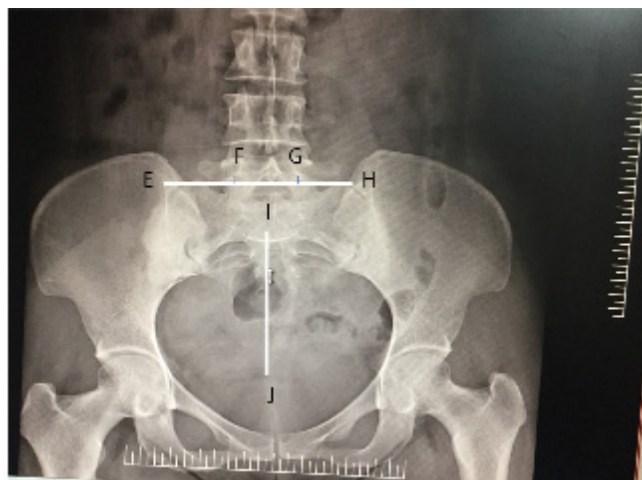


Figure 1. Measurement of sacral parameters (I to J: Sacral length, E to H: Sacral breadth, F to G: Transverse diameter of S1, E to F: Right alar length and G to H: Left alar length)

For sex determination, following indices were calculated;

- Sacral index = (Sacral breadth/Sacral length) X 100
- Alar index = (Length of ala/Transverse diameter of body of S1 vertebra) X 100
- Mean and standard deviations were calculated for sacral and alar indices of males and females. Using these values 'calculated range' was derived by the formula 'Mean  $\pm$  3SD'. [4] For males, if the calculated range was 'a to b' and for females, if the calculated range was 'x to y' (the ranges expectedly overlap each other partly with averages higher in females), then the upper limit of the range for males (b) was chosen as the 'demarking point' (DP) for females. Meaning by, values above 'b' would be accurately identified as belonging to females in cases of uncertainty. Following the same logic, the lower limit of the range for females (x) would be chosen as the DP for identifying males. Hence, the values less than 'x' would be identified as males.

Statistical analysis was done by using Statistical Package for Social Sciences (SPSS™) version 20. Basic descriptive statistics namely standard deviation, mean and range were obtained. Independent sample two tail t-test was used for testing the significance of the differences in the means of the various parameters in males and females. p value <0.05 was considered to be statistically significant.

## RESULTS:

A total of 680 AP pelvic X-ray images were measured. Among them 311 X-ray images were of males and 369 were of females. Observed values of studied parameters are shown in Table 1.

The mean sacral length and mean transverse diameter of S1 vertebra were greater in males (108.04 ± 12.19 mm and 37.94 ± 4.4 mm respectively), when

compared with females (94.66 ± 11.87 mm and 36.79 ± 6.623 mm respectively). Whereas, mean sacral breadth, mean left alar length, mean right alar length and mean alar length were higher in females when compared with males. The differences were statistically significant (p<0.05).

The mean sacral index, mean left ala index, mean right ala index and mean ala index were found to be greater in females as shown in Table 2. DP of sacral index for males was 70.26 and for females it was 131.13. The present study found that the number of bones identified by DP in males and females were 1 (0.32%) and 56 (15.17%) respectively. Similarly, DP of alar index for males was 49.51 and for females it was 134.45. The present study found that the number of bones identified by using DP of alar index in males and females were 0 and 9 (2.4%) respectively.

Table 1: Comparison of male and female sacral parameters.

Parameters	Sex	Range (mm)	Mean (mm)	SD	Statistics
Sacral length	Male	75-143	108.04	12.19	t (678) = 14.460, p<0.001
	Female	62-135	94.66	11.87	
Sacral breadth	Male	76-131	102.71	12.38	t (678) = -7.788, p<0.001
	Female	75-139	110.29	12.86	
Transverse diameter of S1	Male	27-59	37.94	4.41	t (678) = 2.710, p =0.007
	Female	22-67	36.79	6.623	
Left alar length	Male	26-50	36.34	4.90	t (678) = -2.667, p=0.008
	Female	22-57	37.31	4.52	
Right alar length	Male	20-50	32.66	6.49	t (678) = -2.268, p=0.024
	Female	20-54	33.78	6.30	
Mean alar length	Male	26.0-48.5	34.50	4.53	t (678) = -3.155, p=0.002
	Female	23.5-46.0	35.53	4.06	

Table 2: Calculation of demarking points of sacral and alar indices.

Parameters	Sex	Range	Mean	3SD	Mean ±3 SD	Demarking point	Number of bones identified by DP value (%)
Sacral index	Male	66.40-147.50	95.67	35.46	60.20-131.13	<70.26	1 (0.32)
	Female	75.70-189.55	117.63	47.37	70.26-165	>131.13	56 (15.17)
Right alar index	Male	42.86-142.86	87.05	57.45	29.6-144.5	<34.39	0
	Female	35.71-154.55	93.22	58.83	34.39-152.05	>144.5	7 (1.89)
Left alar index	Male	56.52-141.94	96.59	43.11	53.48-139.7	<46.99	0
	Female	33.67-166.67	103.48	56.49	46.99-159.97	>139.7	15 (4.07)
Mean alar index	Male	57.14-137.10	91.82	42.63	49.19-134.45	<49.51	0
	Female	34.69-151.92	98.35	48.84	49.51-147.19	>134.45	9 (2.4)

## DISCUSSION:

The morphometric differences of sacrum are found to be an important parameter for determination of sex, thus useful in forensic and archaeological settings.[4]

In the present study, mean sacral lengths of males and females were respectively ( $108.04 \pm 12.19$  mm) and ( $94.66 \pm 11.87$  mm) and sacral breadth in male and female were respectively ( $102.71 \pm 12.38$  mm) and ( $110.29 \pm 12.86$  mm) which were higher than those found in the study conducted by Yadav N et al.[5] Their observations of male and female sacral lengths were  $104.73 \pm 5.94$  mm and  $92.64 \pm 6.10$  mm respectively. Similarly, sacral breadth in males and females were  $102.93 \pm 4.83$  mm and  $104.77 \pm 6.48$  mm respectively. Their finding of demarking point of sacral index for males was  $<96.4$  and for females  $>112.51$  whereas the present study established  $<70.26$  and  $>131.13$  in males and females respectively. This shows that mean sacral breadth and mean sacral length in Nepalese population were comparatively higher than those in Maharastrian population, whereas sacral index was lower in Nepalese population.[5]

The present study showed the mean sacral indices to be  $96.67 \pm 11.82$  and  $117.63 \pm 15.79$  respectively in males and females. The calculated mean male sacral index was almost similar to the study done by Ravichandran et al., whereas mean sacral index of females was greater in the present study.[6]

The present study observed that the mean sacral breadth was higher in females than that in the males but the mean sacral length was higher in males. This result was similar to the studies conducted by Arora et al., and Dubey et al.,[4, 7] but the study done by Janipati et al.,[1] reported that both mean sacral length and mean sacral breadth were higher in females than in males. Similarly, the study conducted by Masih et al., found that of both mean sacral length and breadth were higher in males.[8]

In the present study, the percentage of bones identified by demarking point of sacral index was 15.17% and 0.32% respectively in males and females whereas the study conducted by Joshi et al. found it to be 12.5% in males and 18.84% in females.[9]

The present study calculated mean right alar index and mean left alar index in the males as

$87.05 \pm 19.15$  and  $96.59 \pm 14.37$  respectively and in females those values were  $93.22 \pm 19.16$  and  $103.48 \pm 18.83$  respectively. All these results were higher than the study conducted by Patel et al.[10]

Our results showed that mean ala length was greater in females ( $35.54 \pm 4.06$  mm) than males ( $34.50 \pm 4.53$  mm) which was similar to the study performed by Kamal et al.[11]

The differences in result of present study compared with other studies may be due to the racial and environmental factors. Further, the present study was conducted in X-ray images while other studies were performed in dry bones.

There are certain limitations of this study. It was conducted in one of the medical colleges of Nepal in a small population. The result obtained from this study might not represent whole population of Nepal. Further studies have to be carried out to find number of bones identified by demarking point for the Nepalese population with larger sample size.

## CONCLUSION:

The sacral and alar indices were found to be greater in females. Demarking points of sacral index for the males and the females have been obtained in the Nepalese context and can be helpful in sex determination.

**Conflict of Interest:** The authors declare that no competing interests exist.

**Financial Disclosure:** No funds were available for the study.

## REFERENCES:

1. Janipati P, Kothapalli J, Rao S. Study of sacral Index: Comparison between different regional population of India and Abroad. *International Journal of Anatomy and Research*. 2014;2(4):640-44. Available from: <https://www.ijmhr.org/ijar.2.4/IJAR.2014.504.pdf>
2. Snell RS. *Clinical Anatomy by regions*. 9<sup>th</sup> ed. West Camden Street Baltimore: Lippincott William & Wilkin, 2012. Available from: <https://www.abebooks.com/Clinical-Anatomy-Regions-Ninth-Edition-Richard/10132537687/bd#&gid=1&pid=1>
3. Ogbogbo M. Gender determination from Radiological Assessment of the Sacrum in Urhobo People of Nigeria. *EC Clinical Experimental Anatomy*. 2019;2(8):385-90. Available from: <https://www.ecronicon.com/eccea/pdf/EC-CEA-02-00077.pdf>
4. Arora AK, Gupta P, Mahajan S, Kapoor SS. Significance of Sacral index in Estimation of sex in Sacra in Cadavers in Punjab. *Journal of Indian Academy of Forensic Medicine*. 2010;32(2):104-7. Available from: <https://www.researchgate.net/publication/277214299>
5. Yadav N, Saini K, Patil K. Determination of sex using dry adult human sacrum- A morphometric study. *International Journal of Current Research and Review*. 2015;7(3):22-8. Available from: [https://www.ijcrr.com/article\\_html.php?-did=630&issueno=0](https://www.ijcrr.com/article_html.php?-did=630&issueno=0)
6. Ravichandran D, Shanthi KC, Shankar K, Chandra H. A study on Sacral Index in Tamil Nadu and Andhra Pradesh population of Southern India. 2013;7(9):1833-4. PMID: 24179874. DOI: <https://doi.org/10.7860/jcdr/2013/6494.3326>
7. Dubey A, Roy SS, Verma S. Significance of Sacral Index in Sex determination and its comparative study in different races. *International Journal of Anatomy and Research*. 2016;4(1):2096-8. DOI: <http://dx.doi.org/10.16965/ijar.2016.153>
8. Masih WF, Singh AP, Rathore KB. Significance of Sacral Index in Estimation of Sex of Sacrum Inhadoti Rajasthan. *Acta Scientific Dental Sci*. 2017;1(4):02-05. Available from: <https://actascientific.com/ASDS/pdf/ASDS-01-0035.pdf>
9. Joshi UU, Puranik M. Various sacral indices: role in study of sexual dimorphism. *International Journal of Research in Medical Sciences*. 2016;4(3):841-6. DOI: <https://dx.doi.org/10.18203/2320-6012.ijrms20160529>
10. Patel MM, Gupta BD, Singel TC. Sexing of sacrum by sacral index and Kimura's base wing index. *Journal of the Indian Academy of Forensic medicine*. 2005;27(1):5-9. Available from: <https://www.indianjournals.com/ijor.aspx?target=ijor:jiafm&volume=27&issue=1&article=001>
11. Kamal A, Ara S, Begum S, Hoque MM, Khatun K. Sexual dimorphism in alar length and auricular index of sacrum. *Bangladesh Journal of Anatomy*. 2014;12(1):17-21. DOI: <https://doi.org/10.3329/bja.v12i1.22613>