

Case Report

Bilateral Chylothorax Post Blunt Trauma: A Case Report

Muhammad Waseem¹, Maryam Rafiq², M Haseeb Malik³¹ Assistant Professor & HOD, Department of Pulmonology, Sahiwal Medical College, Sahiwal.³ Medical Officer, Basic Health Unit, Jandraka, Okara.² Assistant Professor, Department of Pathology, Sahiwal Medical College, Sahiwal.**Author's Contribution**¹ Conception of study¹ Experimentation/Study conduction¹ Analysis/Interpretation/Discussion² Manuscript Writing² Critical Review³ Facilitation and Material analysis**Corresponding Author**

Dr. Maryam Rafiq,

Assistant Professor,

Department of Pathology,

Sahiwal Medical College,

Sahiwal.

Email: mariamsheikh15@yahoo.com

Article Processing

Received: 04/10/2021

Accepted: 07/12/2021

Cite this Article: Waseem, M., Rafiq, M., Malik, M.H. Bilateral Chylothorax Post Blunt Trauma: A Case Report. Journal of Rawalpindi Medical College. 31 Dec. 2021; 25(4): 575-577.

DOI: <https://doi.org/10.37939/jrmc.v25i4.1788>

Conflict of Interest: Nil**Funding Source:** Nil**Access Online:****Abstract**

Introduction: Blunt trauma is a rare cause of chylothorax. In this study, an uncommon case of traumatic chylothorax after blunt trauma is described along with treatment options.

Report on a Case: A 50-year-old male was admitted to the hospital with sudden onset of shortness of breath for one day. He had a history of road traffic accidents 2 days ago, in which he received a strong jerk while trying to avoid impact with the dashboard of the vehicle. He has no past medical history. On examination, He was fully conscious and oriented. Air entry on both sides of the chest was reduced. The x-ray of the chest revealed bilateral blunting of costo-phrenic angles due to pleural effusion. Pleural fluid was sent for biochemical, microbiological, and histopathological analysis. Fluid Triglyceride and cholesterol levels were elevated. Culture and sensitivity were negative while cytopathological analysis revealed increased WBCs. CT scan of the chest did not reveal any malignancy or mediastinal lymph nodes. Bilateral Chest intubation was done to treat severe shortness of breath, that drained milky white fluid. The patient was observed without any particular treatment other than chest intubation. The patient responded well and was discharged uneventfully after five days.

Conclusion: Despite its rarity, chylothorax can occur after blunt trauma. Diagnosis should be confirmed by laboratory testing. Conservative management with or without chest intubation is a common treatment option.

Keywords: Blunt chest trauma, Chylothorax, Triglyceride.

Introduction

Chylothorax is a buildup of milky fluid (chyle) between the visceral and parietal pleura, due to leakage from the thoracic duct. Bartolet first described it in 1633, and the first case was reported by Quinke in 1875.¹ Chylothorax can be classified as congenital, neoplastic, traumatic, and miscellaneous.² The most common cause of chylothorax is cancer that causes obstruction of the thoracic duct.^{3,4} Surgical intervention or percutaneous catheter implantation are the most common iatrogenic causes of chylothorax.^{5,6} Traumatic chylothorax (TC) commonly occurs from penetrating injuries to the thoracic duct. Blunt trauma is a relatively uncommon cause of chylothorax. It should, however, be evaluated in cases that develop pleural effusion after blunt trauma, as it can result in lethal consequences.⁵

The purpose of this study is to describe a case of chylothorax caused by blunt chest trauma and to discuss treatment options.

Case Report

A 50-year-old male was admitted to the hospital with sudden onset of shortness of breath for one day. He had a history of road traffic accidents 2 days ago. During the accident, he received a strong jerk. On examination, he was fully conscious and oriented. Air entry on both sides of the chest was reduced. The x-ray of the chest revealed bilateral blunting of costo-phrenic angles due to pleural effusion CT scan of the chest also showed bilateral pleural effusion, it did not reveal any malignancy or mediastinal lymph nodes (Figure 1).

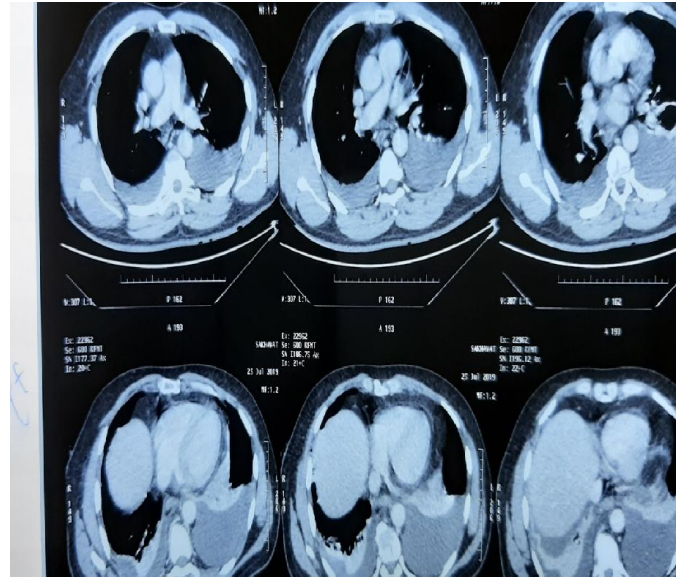


Figure 1: Bilateral pleural effusion with no lymph nodes or malignancy evidence

Pleural fluid was sent for biochemical, microbiological, and histopathological analysis. Triglyceride (TG) and cholesterol levels in the pleural fluid were found elevated. The level of TG was 2406mg/dl and cholesterol was 108mg/dl.

TG Culture and sensitivity revealed occasional WBCs, and culture was negative. Histopathology confirmed that the pleural fluid was a fat-rich fluid with few inflammatory cells.

The patient was intubated bilaterally. Drain output was monitored in both chest drains to below 0.5 litre per day. The ICC drainage per day of admission is shown in (Figure 2).

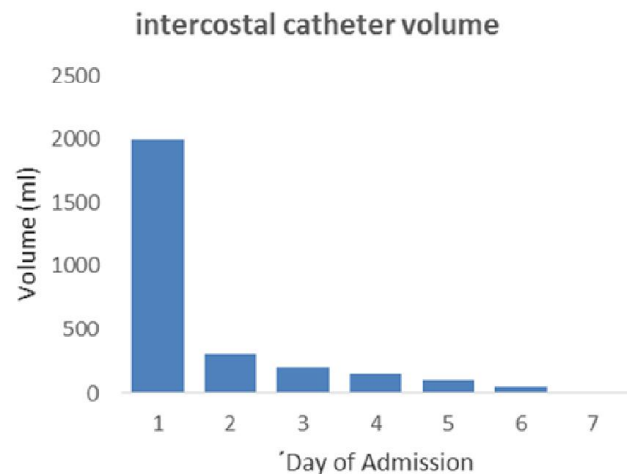


Figure 2: Intercostal catheter volumes (ml) per day of admission

Chest tubes were removed by day five of admission without complications. The patient was uneventfully discharged on day five of admission.

Discussion

A rare but serious consequence of chest trauma is disruption of the thoracic duct. Blunt trauma can result in traumatic chylothorax by a direct breach in diaphragmatic crura, hyperextension of the spine, or direct injury due to vertebral fracture or ribs.⁷ In our case it could be due to hyperextension of the spine during accident leading to injury to any tributaries of the thoracic duct as the patients responded well to conservative management. Nonetheless, a partial tear of the primary thoracic duct spilling chyle with high lipid concentrations cannot be ruled out altogether. Symptoms of chylothorax appear gradually, after 2 to 7 days of injury.⁸

To establish the diagnosis of chylous effusion, triglyceride or cholesterol levels in the pleural fluid were measured quantitatively, which were both grossly elevated. To classify effusions into chylous or non-chylous, Staats et al. measured triglyceride levels in 142 effusions by lipoprotein electrophoresis. They found that fluid with a triglyceride value greater than 110 mg/dL has a 99 percent chance of being chylous, while chances are less than 5% if a triglyceride value is less than 50 mg/dL.⁶

The results of Culture and sensitivity negative and cytopathology revealed scattered reactive inflammatory cells. These laboratory data confirmed chylothorax as culture is usually negative in chylothorax, owing to the bacteriostatic characteristic of chyle.⁹

Conservative management is successful in 88% of cases. However, cause, clinical presentation, and volume of drainage all have a role in determining management strategies.¹⁰ As chyle is an irritating fluid that causes pleurodesis, there is spontaneous closure of the leak. Lung intubation causes the lung to expand, thereby improving clinical conditions. The patient was also kept NPO to reduce chyle production. Conservative treatment should preferably be provided for two weeks; however, it can be stretched to four weeks (11). When the daily chyle leak surpasses 1 Liter/ day for more than 5 days, surgical intervention generally is better than conservative therapy.¹¹

The most common surgical procedure is thoracic duct ligation. Video-assisted thoracoscopic surgery (VATS) or an open thoracotomy may be used to accomplish this.¹²

Conclusion

Chylothorax can be a complication of blunt chest trauma, albeit it is relatively rare. Before addressing management, the diagnosis should be validated with laboratory tests. Patients with chylothorax are given conservative treatments.

References

1. Jahsman WE. Chylothorax; brief review of literature; report of three non-traumatic cases. *Ann Intern Med.* 1944 Oct 1;21(4):669-78. <https://doi.org/10.7326/0003-4819-21-4-669>
2. DeMeester T. The pleura. In: Spencer E, editor. *Surgery of the Chest.* 4ed. Philadelphia: WB Saunders; 1983.
3. Doerr CH, Allen MS, Nichols III FC, Ryu JH. Etiology of chylothorax in 203 patients. In *Mayo Clinic Proceedings* 2005 Jul 1 (Vol. 80, No. 7, pp. 867-870). Elsevier.
4. McWilliams A, Gabbay E. Chylothorax occurring 23 years post-irradiation: Literature review and management strategies. *Respirology.* 2000 Sep;5(3):301-3. DOI: 10.1046/j.1440-1843.2000.00263.x
5. Seitelman E, Arellano JJ, Takabe K, Barrett L, Faust G, Angus LG. Chylothorax after blunt trauma. *J Thorac Dis.* 2012 Jun 1;4(3):327-30. Doi: 10.3978/j.issn.2072-1439.2011.09.03
6. Pillay TG, Singh B. A review of traumatic chylothorax. *Injury.* 2016 Mar 1;47(3):545-50. DOI: 10.1016/j.injury.2015.12.015
7. Kamal Idris MS, Hefny AF, Khan NH, Abu-Zidan FM. Blunt traumatic tension chylothorax: case report and mini-review of the literature. *World J clin cases.* 2016 Nov 16;4(11):380. DOI: 10.12998/wjcc.v4.i11.380
8. Ikonomidis JS, Boulanger BR, Brenneman FD. Chylothorax after blunt chest trauma: a report of 2 cases. *Can J Surg.* 1997 Apr;40(2):135.
9. Golden P. Chylothorax in blunt trauma: a case report. *Am J Crit Care.* 1999 May 1;8(3):189.
10. Demos NJ, Kozel J, Scerbo JE. Somatostatin in the treatment of chylothorax. *Chest.* 2001 Mar;119(3):964-6. DOI: 10.1378/chest.119.3.964
11. Dugue L, Sauvanet A, Farges O, Goharin A, Le Mee J, Belghiti J. Output of chyle as an indicator of treatment for chylothorax complicating oesophagectomy. *Br J Surg.* 1998 Aug;85(8):1147-9. DOI: 10.1046/j.1365-2168.1998.00819.x
12. Patterson GA, Todd TR, Delarue NC, Ilves R, Pearson FG, Cooper JD. Supradiaphragmatic ligation of the thoracic duct in intractable chylous fistula. *Ann Thorac Surg.* 1981 Jul;32(1):44-9. DOI: 10.1016/s0003-4975(10)61372-0.
13. M Shackford SR, Dunne CE, Karmy-Jones R, et al. The evolution of care improves outcome in blunt thoracic aortic injury: A Western Trauma Association multicenter study. *J Trauma Acute Care Surg.* 2017 Dec;83(6):1006-13. DOI: 10.1097/TA.0000000000001555