

ORIGINAL ARTICLE

## UNCONTROLLED TYPE 1 DIABETES MELLITUS WITH LUNG TUBERCULOMA AND BILATERAL HYDRONEPHROSIS IN 13-YEAR-OLD GIRL

Anggia Rarasati Wardhana<sup>1\*</sup>, Sukartini<sup>2</sup>, Annisa Muhyi<sup>3</sup>

<sup>1,2,3</sup>Department of Child Health, University of Mulawarman Medical School, Abdul Wahab Sjahranie Hospital, Samarinda-Indonesia

\*Correspondent Author: [anggiararasatiwardhana@gmail.com](mailto:anggiararasatiwardhana@gmail.com)

### ARTICLE INFO

#### Article history:

Submitted: July 09 2019

Received in revised form

August 2019

Accepted: August 12 2019

#### Keywords:

Type 1 diabetes mellitus, tuberculosis, tuberculoma, hydronephrosis, blood glucose

### ABSTRACT

Diabetes Mellitus (DM) is an important risk factor for the development of active tuberculosis (TB). DM is a chronic disease that weakens the immune system which increases the risk of tuberculosis up to three-fold. We present a case of 13-year-old girl with chest pain and cough. She has a previous history of type 1 DM. Laboratory findings showed hyperglycemic state. Thoracic CT showed tuberculoma at inferoposterior lobe of left lung. The abdominal CT showed bilateral hydronephrosis. She was then administered TB treatment of 2HRZE/10RH, corticosteroid, and insulin regimens with strict monitoring of blood glucose. Clinical symptoms and blood glucose levels were significantly improved after treatment for 20 days.

@2019 Medical and Health Science Journal. 10.33086/mhsj.v3i2.1155

### BACKGROUND

Type 1 Diabetes Mellitus (T1DM) is a chronic illness characterized by the insufficient production of insulin due to autoimmune destruction of beta cells in the pancreas. T1DM is chiefly occurred following an autoimmune demolition of the pancreatic  $\beta$  cells through cell-mediated immunity as well as a humoral immune response. While the disease may develop in adults, the onset most often occurs in childhood. T1DM can be considered as one of the most frequent endocrine and metabolic dysfunction in children. T1DM in children and teenagers represents 80%-90% of diabetes. In the US, the prevalence of T1DM in youth under 20 years was 1.93 /1000 in 2009 with 2.6 - 2.7% relative annual increase.<sup>1</sup>

Tuberculosis (TB) is still one of the main causes of morbidity and mortality worldwide.<sup>3</sup> Children are particularly vulnerable to tuberculosis. Pediatric cases of tuberculosis account for 10% of

all cases of the disease. In 2015, there were an estimated 1 million new cases of childhood tuberculosis and an estimated 210,000 deaths from tuberculosis in children.<sup>4</sup> Children carry a huge tuberculosis disease burden, particularly in endemic areas.<sup>5</sup> According to the WHO, the three regions where most pediatric tuberculosis cases are concentrated are Southeast Asia, Africa, and the Western Pacific, which respectively accounted for 35%, 30%, and 20% of the new cases reported in 2015. It is estimated that tuberculosis caused the death of 210,000 children worldwide in 2015. Based on those estimates, tuberculosis might be the sixth leading cause of death in the 1- to 5-year age group.<sup>4</sup> The possibility of association between DM and TB represents an important and growing challenge to the global control of TB. Patients with these two conditions may present high rates of treatment failure of TB and increased risk of death. Cases of TB with DM have higher probability of treatment failure of TB and may develop resistance

Correspondence: Anggia Rarasati Wardhana

@2019 Medical and Health Science Journal. 10.33086/mhsj.v3i2.1155

Available at <http://journal2.unusa.ac.id/index.php/MHSJ>

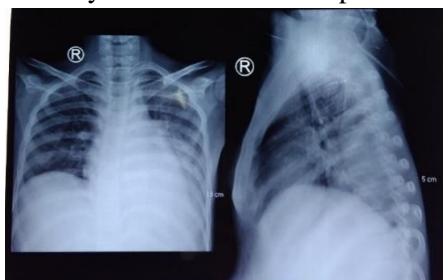
to the drugs used in the treatment. On the other hand, TB can induce glucose intolerance and hinder the glycemic control in individuals with DM.<sup>6</sup> A systematic review of 13 observational studies found that DM increases the risk of TB by three-fold.<sup>7</sup> Thus, patients with DM comorbidity may pose a greater challenge the control of TB.<sup>8</sup>

## CASE PRESENTATION

A 13-year-old girl presented to A. W. Sjahranie Hospital with left chest pain for three days which felt like being punctured and burned. The pain was exacerbated when she laid down. She also had cough for two months with yellow-green phlegm and fever which appeared simultaneously with cough, night sweats, weight loss, and hematuria. The patient has a history of a lump in the neck for one year which was sometimes felt painful, and was getting bigger. She also had prolonged fever, and no cough in that time. Her grandmother was diagnosed with lung tuberculosis and had passed way. Her BCG vaccine history were positive. She was diagnosed with lymphadenitis TB and had been treated in declared cured in 2017 and was diagnosed with T1DM at the age of 10. Her father had been diagnosed with DM and stroke. Her mother had a history of breast cancer.

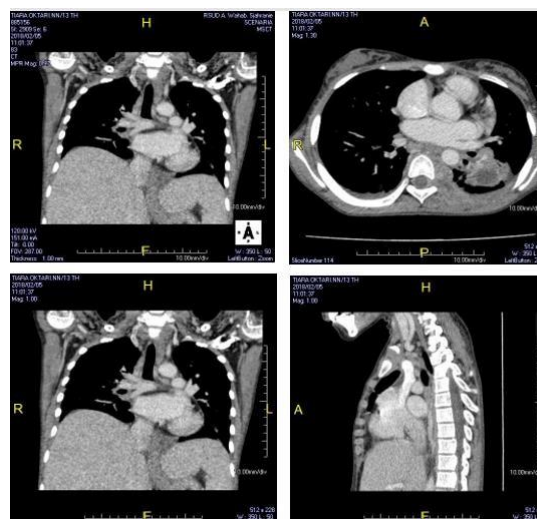
## INVESTIGATIONS

Physical examination revealed asymmetrical chest movement, decreased tactile fremitus on left chest, dull percussion on the inferoposterior left chest, and decreased breath sound on posterior left chest with rhonchi on both sides of lung bases. Both kidneys were palpable. Early diagnosis when admitted to the hospital for this patient was pleural effusion and T1DM with hematuria. The differential diagnosis were pleuritic TB and pleural abscess with urinary tract infection or nephrolithiasis.

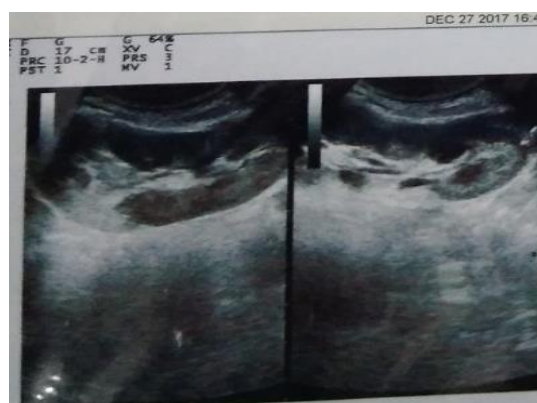


**Figure 1.** Chest X-ray

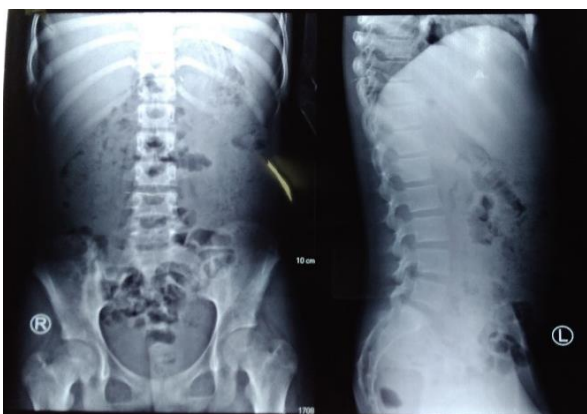Acid Fast Bacilli sputum smear was negative. Laboratory findings revealed leukocytosis (WBC 23.580/mm<sup>3</sup>), anemia (9,7 gr/dl), Hematocrit was 30,4%, Platelets were 364.000/mm<sup>3</sup> and blood glucose of 463 mg/dL. Chest X-ray showed bronchopneumonia (Fig 1), while thoracic CT showed: hypodense lesion with slight hyperdense on inferior-posterior lobe of left lung; suspicion of left lung abscess; solid and cystic mass of inferior-posterior lobe of left lung; and minimal effusion on posterior right lung (Fig 2). Fine Needle Aspiration Biopsy revealed granulomatous suppurative inflammations with squamous dysplasia (TB with secondary infection and squamous dysplasia). Abdominal USG showed bilateral hydronephrosis (Fig 3), while abdominal X-ray showed unclear kidney contours (Fig 4). Abdominal CT revealed left grade II hydronephrosis and right grade I hydronephrosis (Fig 5). After complete examination, the final diagnosis in this patient is T1DM with lung tuberculosis and bilateral hydronephrosis.



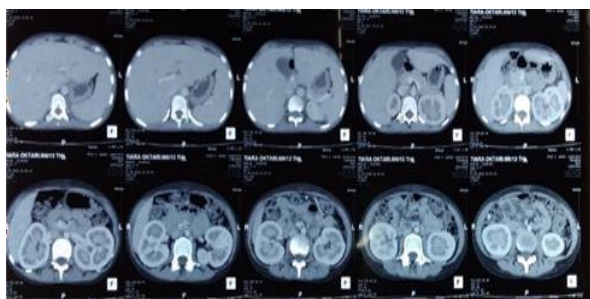
**Figure 2.** Thoracic CT.



**Figure 3.** Abdominal USG



**Figure 4.** Abdominal X-ray.



**Figure 5.** Abdominal CT.

## TREATMENT

On admission she was given antibiotics and the symptomatic therapy such as antipyretic, antiulcer through injection. Treatment for TB was initiated with 2HRZE/10RH and corticosteroid, with strict blood glucose monitoring. Insulin regimen consists of both long-acting insulin and rapid acting insulin with dose adjusted to the patient's condition.

Outcome and follow up

Clinical symptoms were improved significantly after 20 days of hospitality. The complaints were reduced. The chest pain were eased, cough were missing arise, and vanished fever. After one month, the patient's blood glucose becomes normal. The chest examination was improved lung spot and no effusion on the affected side.

## DISCUSSION

The first report of the association between DM and TB was documented by Avicenna (980-

1027 AD) over one thousand years ago. In recent decades, with the increasing prevalence of TB, particularly Multi Drug Resistant TB (MDR-TB), and DM cases in the world, the relationship is re-emerging as a significant public health problem. The link of DM and TB is more prominent in developing countries where TB is endemic and the prevalence of DM is rising.<sup>9</sup>

Our patient had diseases that were mutually incriminating one to another. Associated with this case, patients with T1DM may have an even higher risk of developing TB compared to those with type 2 diabetes (T2DM).<sup>10</sup> DM patients exhibit alterations in the immune response against *Mycobacterium tuberculosis* (Mtb), making them more susceptible to infection or progression towards active TB disease and less responsive to treatment. DM patients have been associated with dysregulated cytokine responses to Mtb, including T-helper 1 (Th1) along with several cytokines (TNF- $\alpha$ , IL-1 $\beta$ , and IL-12), lymphocytes, monocytes, natural killer T cells, and B lymphocytes.<sup>11</sup> Thus, DM is likely to reduce the efficiency of anti-mycobacterial treatment. Hyperglycemia may also compromise Mtb killing by affecting the microvasculature and reducing lung tissue perfusion for optimal immune surveillance.<sup>7</sup> In addition, Arce-Mendoza et al (2008) reported that DM also affects the expression of receptors like CD64, CD206 and RAGE in monocytes.<sup>12</sup>

Other possible factors that may impact the host response in patients with DM are short-chain fatty acids (SCFAs). SCFAs modulate immune and inflammatory responses, thereby influencing the host response to Mtb. SCFAs act on immune and endothelial cells via at least two mechanisms: activation of G-protein coupled receptors (GPCRs) and inhibition of histone deacetylase (HDAC). They affect the function of various cell types such as lymphocytes, neutrophils, and macrophages.<sup>13</sup>

The immunological source of susceptibility to TB among those with DM is not well understood. Enhanced susceptibility to TB in patients with DM has been attributed to several factors, including direct effects related to hyperglycemia and insulin resistance and indirect effects related to macrophage and lymphocyte function. The impaired immune

response in patients with DM, which facilitates either primary infection with TB or reactivation of latent TB, may be the possible reason for these defective immune responses. Studies probing the innate and adaptive immune response to microbial antigens in patients with DM suggest that these responses are compromised, particularly in patients with chronic hyperglycemia.<sup>12</sup>

Active TB disease may present atypically with altered symptoms and signs in those with DM. Among persons with DM, TB may progress faster, present with more chest and systemic symptoms and more frequent and higher-grade smear and culture positivity. Severity at presentation seems to be related to the degree of uncontrolled hyperglycemia. The effects of DM on chest radiograph findings are inconsistent.<sup>14</sup> There is also some evidence that DM prolongs smear and culture positivity.<sup>14</sup>

Patients with DM comorbidity may pose a greater challenge to control the TB, since DM adversely affects TB treatment outcomes. The reasons are not completely understood but include the immunosuppressive effects of DM itself, drug-drug interactions, adverse effects from medications, suboptimal adherence to medication, reduced bio-availability of the drugs and other unlisted factors. There is also a doubling of the risk of death during TB treatment among those with DM with the risk increasing to about five times.<sup>6,14</sup> Diabetic patient with TB has a higher probability of failure of the sputum smear conversion after 2 months of therapy than patients without DM. Patients with DM also are more likely to be lost to follow-up than patients who are non-diabetic, thus, increased duration of treatment and weight-adjusted doses of anti-TB drugs might be necessary.<sup>15</sup> In addition, Lee et al (2014) revealed that the presence of DM was independently associated with the risk of TB relapse.<sup>8</sup>

Currently, there is not sufficient evidence to recommend alternative anti tuberculosis regimen for diabetics. Consequently, treatment of TB is similar between diabetics and nondiabetics.<sup>9</sup> There are a number of actions that can be taken to mitigate the effect of DM to decrease the burden of TB, such as prevention by addressing the underlying determinants, screening, early diagnosis, adequate

support systems, treatment of patients with double disease, research and innovation. Optimizing DM management during TB treatment should therefore be a high priority in patients with TB to improve the general health status of the patient. Management of DM in TB should be aggressive, since an optimal glycemic control results in a better patient outcome. The optimal approach might consist of avoiding sulphonylurea derivatives and treating DM with diet, lifestyle modifications, metformin and insulin, as these last two medications have few interactions with TB drugs.<sup>15</sup> The American Association of Clinical Endocrinologists recommends the use of modern insulins or insulin analogues, as they are more predictable in action and cause less hypoglycemia.<sup>16</sup> A successful treatment can only be achieved by ensuring good compliance to treatment both for TB and DM.<sup>15</sup>

---

## CONCLUSION

A case of 13-year-old girl with T1DM and tuberculoma and bilateral hydronephrosis was reported. The diagnosis was based on patient's history, physical examination, laboratory findings, and imaging. The patient was admitted with chest pain and chronic cough with a history of T1DM. Standard regimen of anti-tuberculosis treatment was initiated, in conjunction with corticosteroid and insulin therapy. Clinical and laboratory improvement were shown after treatment. This report highlighted that aside from the comorbidities between diseases, there existed additional complexity in managing T1DM patient with DM. Patients with DM comorbidity may pose a greater challenge to control the TB, since DM adversely affects TB treatment outcomes. The reasons are not completely understood but include the immunosuppressive effects of DM itself, drug-drug interactions, adverse effects from medications, suboptimal adherence to medication, reduced bio-availability of the drugs and other unlisted factors. There is also a doubling of the risk of death during TB treatment among those with DM with the risk increasing to about five times. A successful treatment can only be achieved by ensuring good compliance to treatment both for TB and DM. The

success of the therapy will later provide a good prognosis to the patient.

---

### CONFLICTS OF INTEREST

There is no conflict of interest in this article.

---

### REFERENCES

1. Shojaeian A et al. An overview of the Epidemiology of Type 1 Diabetes Mellitus. *Int J Metab Syndr*. 2018;2(1):1–4.
2. Factors R et al. Diagnosis , Therapy and Control of Diabetes Mellitus in Children and Adolescents. *Exp Clin Endocrinol Diabetes*. 2014;122:425–34.
3. Marais BJ. Tuberculosis in children. *J Paediatr Child Health*. 2014;1–9.
4. Cristina A et al. Epidemiological aspects , clinical manifestations , and prevention of pediatric tuberculosis from the perspective of the End TB Strategy. *J Bras Pneumol*. 2018;44(2):134–44.
5. Gomez-pastrana D. Diagnosis of Pulmonary Tuberculosis in Children. *J Infect Dis Ther*. 2013;1:17–24.
6. I SMP et al. Association between diabetes and tuberculosis : case-control study. *Rev Saúde Pública*. 2016;50(82):1–7.
7. Restrepo BI. Diabetes and tuberculosis. *Microbiol Spectr*. 2017;4(6):1–19.
8. Shen T et al. Increased Risk of Tuberculosis in Patients With Type 1 Diabetes Mellitus : Results From a Population-Based Cohort Study in Taiwan. *Medicine (Baltimore)*. 2014;93(16):1–6.
9. Baghaei P et al. Diabetes mellitus and tuberculosis facts and controversies. *J Diabetes Metab Disord*. 2013;12(58):1–8.
10. Lachmandas E et al. Patients with type 1 diabetes mellitus have impaired IL-1  $\beta$  production in response to Mycobacterium tuberculosis. *Eur J Clin Microbiol Infect Dis*. 2018;37:371–80.
11. Pal R et al. Diabetes Mellitus as Hub for Tuberculosis Infection : A Snapshot. *Int J Chronic Dis*. 2016;1–7.
12. Nathella PK. Influence of diabetes mellitus on immunity to human tuberculosis. *Immunology*. 2017;152:13–24.
13. Lachmandas E et al. Diabetes Mellitus and Increased Tuberculosis Susceptibility : The Role of Short-Chain Fatty Acids. *J Diabetes Res*. 2016;1–15.
14. Lin Y. Management of Diabetes Mellitus-Tuberculosis: A Guide to the Essential Practice. France: World Diabetes Foundation; 2018.
15. Pizzol D et al. Tuberculosis and diabetes : current state and future perspectives. *Trop Med Int Heal*. 2016;21(6):694–702.
16. Niazi AK et al. Diabetes and tuberculosis : a review of the role of optimal glycemic control. *J Diabetes Metab Disord*. 2012;11(28):1–4.