

Change in Visual Acuity in Relation to Central Macular Thickness after Intravitreal Bevacizumab in Diabetic Macular Edema

Muhammad Ali Haider¹, Uzma Sattar²

¹⁻²Department of Ophthalmology, Rahbar Medical and Dental College, Lahore

ABSTRACT

Purpose: To evaluate the change in visual acuity (Log MAR) in relation to decrease in central macular thickness, after a single dose of intravitreal Bevacizumab injection.

Study Design: Quasi experimental study.

Place and Duration of Study: Rahbar Medical & Dental College, Punjab Rangers Teaching Hospital, Lahore, from January 2019 to June 2019.

Material and Methods: 70 eyes of 70 patients diagnosed with diabetic macular edema were included in the study. Patients having high refractive errors (spherical equivalent of $> \pm 7.5D$) and visual acuity worse than +1.2 or better than +0.2 on log MAR were excluded. Patients with ocular diseases other than diabetic macular edema were also excluded. Central macular edema was measured in μm on OCT and visual acuity was documented using Log MAR chart. These values were documented before and at 01 month after injection with intravitreal Bevacizumab (1.25 mg in 0.05 ml). Wilcoxon Signed rank test was used to evaluate the difference in VA before and after the anti-VEGF injection. Difference in visual acuity and macular edema (central) was observed, analyzed and represented in p value. P value was considered statistically significant if it was less than 0.01%.

Results: Mean age of patients was 52.61 ± 1.3 . Vision improved from 0.90 ± 0.02 to 0.84 ± 0.02 on log MAR chart. The change was statistically significant with p value < 0.001 . Central macular thickness reduced from 328 ± 14 to $283 \pm 10.6 \mu m$ on OCT after intravitreal anti-VEGF, with significant p value < 0.001 .

Conclusion: A 45 μm reduction in central macular thickness was associated with 0.1 Log MAR unit improvement in visual acuity after intravitreal Bevacizumab in diabetic macular edema.

Key Words: Visual acuity, Macular edema, Central macular thickness, Bevacizumab.

How to Cite this Article: Haider MA, Sattar U, Zaidi SR. Change in Visual Acuity in Relation to Central Macular Thickness after Intravitreal Bevacizumab in Diabetic Macular Edema. Pak J Ophthalmol. 2020, **36 (3)**: 292-297.

Doi: 10.36351/pjo.v36i3.1051

INTRODUCTION

Diabetic macular edema results in increased central retinal thickness at macula which is a sight

threatening condition. This increased thickness leads to reduction in visual acuity. Currently, intravitreal anti-VEGF drugs are recommended for management of diabetic macular edema¹. These drugs are safe, decrease macular edema and restore vision. Amongst the various anti-VEGF agents available, Bevacizumab (1.25 mg in 0.05 ml) has revolutionized the management of diabetic macular edema in recent years. It is used off label in the developing world^{2,3}. It is a humanized monoclonal antibody that swathes with all isoforms of vascular endothelial growth factors-A,

Correspondence to: Muhammad Ali Haider
Department of Ophthalmology
Rahbar Medical and Dental College, Lahore
Email: alihaider_189@yahoo.com

Received: April 20, 2020
Accepted: June 17, 2020

Revised: May 8, 2020

with a molecular mass of 149 kDa that effectively binds and inhibits all the isoforms of VEGF^{4,5}. Significant decrease in leakage from vessels has also been observed in proliferative diabetic retinopathy treated with single dose of intravitreal Bevacizumab (1.25 mg)⁶. It results in improved visual acuity (VA) with reduction in macular thickness⁷. Anti-VEGF or implantable dexamethasone with or without retinal laser are considered to be the treatment of choice in DME⁸.

Improvement in diabetic macular edema is gauged by repeatedly measuring central retinal thickness, before and after the start of treatment using high resolution OCT (optical coherence tomography), a diagnostic tool for management of retinal diseases^{9,10}.

The aim of this prospective study was to correlate the improvement in visual acuity with the corresponding reduction in central macular thickness after a single dose of intravitreal Bevacizumab therapy in patients with diabetic macular edema.

MATERIAL AND METHODS

The study was conducted at the Department of Ophthalmology Rahbar Medical & Dental College, Punjab Rangers Teaching Hospital, Lahore after approval from the ethical committee. In this Quasi experimental study, 70 eyes with diabetic macular edema were enrolled, having a clear media for OCT with minimum of 3 mm pupil diameter and best corrected visual acuity (BCVA) of +0.2 to +1.2 on log MAR with snellen equivalent of 6/12 to 6/120.

The patients having high refractive errors (spherical equivalent of $> \pm 7.5D$) and visual acuity worse than +1.2 or better than +0.2 on log MAR were excluded. Any other ocular condition in which after treatment, the improvement in vision was not significant (e.g. ocular degenerative/dystrophic changes) and patients having any media opacity that could affect the visual acuity and OCT measurements were also excluded.

In the selected patients, prior to intravitreal injection of anti-VEGF, LogMAR distance visual acuity was recorded and a full ophthalmological examination including evaluation of refractive

status, slit lamp examination for anterior and posterior segments was performed. Based on the clinical findings diabetic macular edema was diagnosed and the central macular thickness was measured in micron meter (μm) on OCT (NIDEK RS-3000 Advance). In selected patients, single dose of intravitreal anti-VEGF was injected by senior consultant ophthalmologist. Distance visual acuity and OCT parameters were re-evaluated one month after the intravitreal anti-VEGF therapy.

Data was analyzed using SPSS version 22. Quantitative data was represented as mean \pm S.D. and S.E. while the qualitative data was represented in the form of pie chart.

RESULTS

A total of 70 eyes of 70 patients, 40 (57%) males and 30 (43%) females were enrolled in this research by convenient sampling technique. Mean age of the patients was 52.61 ± 1.3 with minimum age of 22 years and maximum 74 years (Table 1). Normality

Table 1: Assumption Test of Normality Using Shapiro-Wilk.

	Kolmogorov-Smirnov ^a		Shapiro-Wilk			
	Statistic	df	Sig.	Statistic	Df	Sig.
VA after injection	.160	70	.000	.919	70	.000
VA before injection	.169	70	.000	.935	70	.001
OCT before injection	.255	70	.000	.791	70	.000
OCT after injection	.206	70	.000	.832	70	.000

assumption was checked by using Shapiro-Wilk test. All quantitative variables were considered to have normal distribution with $p\text{-value} > 0.05$ while the $p\text{-value} \leq 0.05$ was considered as not normally distributed. Shapiro-Wilk test shows abnormal distribution of Visual acuity and macular measurements (μm) on OCT (Table 2). There were

Table 2: Descriptive Statistic of Age (Years).

	N	Range	Minimum Value	Maximum Value	Mean Value	Std. Deviation	Std. Error of Mean	Statistic
Age of patients	70	52	22	74	52.61	1.373	11.488	

Table 3: Distribution of Macular Edema among Patients Having Different Types of Diabetic Retinopathy.

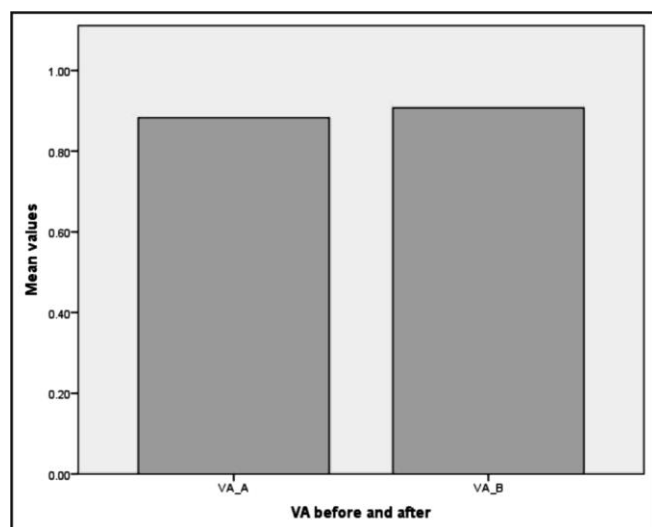
Type of Diabetic Retinopathy	Type of Macular Edema		Total
	CSMO	Diffuse	
High risk PDR	1	1	2
Low risk PDR	7	3	10
Severe NPDR	27	6	33
Very severe NPDR	22	3	25
Total	57	13	70

different stages of diabetic retinopathy in 70 eyes. Details are shown in table 3.

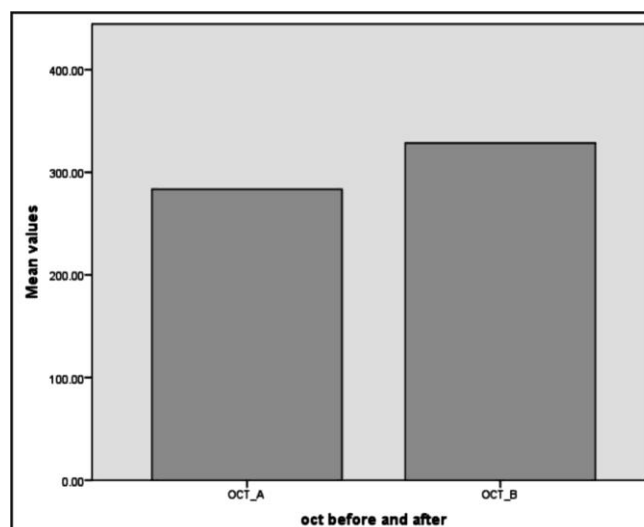
Wilcoxon Signed rank test was used to evaluate the difference in VA before and after the anti-VEGF injection. It improved from 0.90 ± 0.02 to 0.84 ± 0.02 on log MAR chart. The change was statistically significant with p value < 0.001 . Central macular thickness reduced from 328 ± 14 to $283 \pm 10.6 \mu\text{m}$ on OCT after intravitreal anti-VEGF, with significant p value < 0.001 (Table 4).

Table 4: Description and Comparison in Visual Acuity and OCT.

	Range μm	Minimum Value Statistics	Maximum Value Statistics	Mean Value Statistics	Std. Deviation	P value Statistic	
VA before injection	1.0	.3	1.3	.890	.0261	.2181	< 0.001
VA after injection	0.9	.3	1.2	.840	.0278	.2324	
OCT before injection	490	215	705	328.43	14.348	120.041	< 0.001
OCT after injection	319	161	480	283.44	10.672	89.287	



Graph 1: Visual acuity before and after the intravitreal anti-VEGF (Bevacizumab).
VA_A: Visual Acuity Before
VA_B: Visual Acuity After



Graph 2: Macular thickness before and after intravitreal anti-VEGF (Bevacizumab).
OCT_A = OCT After Injection
OCT_B = OCT Before Injection

DISCUSSION

Clinical evidence has established that increase in central macular thickness in diabetic macular edema results in corresponding decrease in visual acuity, and the treatment which reduces the retinal thickening improves vision. OCT can detect macular edema that is not clinically evident, and several OCT-derived biomarkers are useful predictors of its progression, severity, and visual outcome¹¹. In this study, we

documented the correlational change after a single injection of intravitreal bevacizumab injection between visual acuity and central macular thickness on OCT.

At any given central macular thickness, there was a corresponding significant change in visual acuity. Many eyes with significant macular edema had very good visual acuity and eyes with mild edema exhibited a profound decrease in vision. It is also reported that there is inconsistency increase in thickness of central

macular point with the increase in visual acuity as well as incongruous decrease in thickness of central retina with the decrease in visual acuity is not common.² According to this, OCT measurement can be a good surrogate for visual acuity in macular edema related to diabetes.

Diabetic macular edema is the major clinical factor affecting visual acuity in diabetic retinopathy and is quantified for assessment and response to treatment by the central retinal thickness measured by OCT. Visual acuity is inversely related to the retinal thickness to some extent. In this study we found a strong correlation of visual acuity with OCT measurements of macular thickness ($r^2 = -0.46$). After the intravitreal bevacizumab therapy, the visual acuity improved with the reduction in retinal thickness. This study has shown that after a single dose of Bevacizumab therapy the central retinal thickness on OCT improved from 328 ± 14 to $283 \pm 10.6 \mu\text{m}$ with a corresponding improvement in the mean visual acuity from 0.9 ± 0.02 to 0.84 ± 0.02 with significant *p* value ≤ 0.01 .

Recent studies have suggested that anti-VEGF drugs are safe, cost effective, and easily admissible in clinical settings, well tolerated by the patients and remarkably well suited for treating macular edema secondary to diabetes. The efficacy of bevacizumab (1.25 mg) has been demonstrated in a study conducted on patients having diabetic macular edema. There was significant decrease in area of leaking vessels in proliferative diabetic retinopathy when treated with single dose of intravitreal bevacizumab (1.25 mg). There was a significant improvement in mean visual acuity associated with it⁸. These studies reported that often in bilateral DME, Bevacizumab effects reduction in macular thickness in un-injected fellow eye and improvement in visual acuity was seen in 40% eyes injected with Bevacizumab¹².

According to previous studies, significant improvement of visual acuity was appreciated in diabetic macular edema with Bevacizumab when combined with dexamethasone, as compared to Bevacizumab monotherapy¹³. In this study, efficacy of treating diabetic macular with Anti-VEGF injection bevacizumab in diabetic patients was documented. Visual Acuity on Log MAR chart and central retinal thickness on OCT were the efficacy markers that were documented.

The mean BCVA on Log MAR chart at the start of the treatment was 0.42 ± 0.14 Log MAR units. There

was a significant improvement from baseline to 0.34 ± 0.13 , 0.25 ± 0.12 and 0.17 ± 0.12 Log MAR units at 1 monthly intervals after the three injections. At final visit at 6 months, the visual acuity was 0.16 ± 0.14 Log Mar units. With a *P* value of $P > 0.0001$, the difference was statistically significant. The mean central retinal thickness of central 1 mm area improved from 452.9 ± 143.1 microns at baseline to 279.8 ± 65.2 microns ($P < 0.0001$) on the final visit.¹⁴ Another study also suggested that Bevacizumab is helpful in significant macular edema reduction and visual acuity improvement in wet age related Macular Degeneration.¹⁵

In their study Santos et al. described the factors affecting response to intravitreal anti-VEGF injections in patients of diabetic macular edema. They found that BCVA improved from 4.78 and 5.52 letters, and a central retinal thickness decreased from 80.25 and 106.12 microns after 3 and 6 months of treatment. They concluded that optimal responders to anti-VEGF therapy could be identified based on their response to decrease in central retinal thickness and hence, could be a predictor of BCVA improvement after the treatment¹⁶.

Mansourian et al determined the efficacy of a single anti-VEGF injection of bevacizumab as primary treatment for diabetic macular edema. They compared the response to treatment using bevacizumab alone, in combination with intravitreal triamcinolone acetonide and compared the response to macular laser photocoagulation. The result showed no significant difference between these two treatments in reducing the central macular thickness with improvement in visual acuity¹⁷.

Yang et al compared the visual acuity, central retinal thickness and retinal sensitivity in different types of macular edema. He found that there was positive correlation between central foveal thickness and log MAR BCVA in patients with focal, diffuse and ischemic diabetic macular edema ($r = 0.56, -0.62$; $P < 0.01$).¹⁸

Recent studies showed that visual outcome improves significantly if anti-VEGF therapy is started earlier in the course of disease. Patients presenting earlier with a shorter history of symptoms had better improvement in visual acuity and sustained decrease in central retinal thickness, 6 months after treatment. However patients with a prolonged disease history, the central retinal thickness and visual acuity at 3 months

and 6 months post treatment would not be significantly different from baseline values at the start of treatment¹⁹. Thus, based on these results early treatment of macular edema is indicated for better and sustained anatomical and visual results. Thus earlier detection of reduced visual acuity is significantly important for the treatment of recurring macular edema. Another study highlighted the correlation between central subfield thickness and baseline visual acuity after treatment with Bevacizumab²⁰.

Consistent with other studies, younger age of patients with diabetic macular edema was associated with significantly improved visual acuity^s and reduced central retinal thickness after every 6 weeks of treatment. However, if the treatment is delayed by more than 6 weeks, repetition of intravitreal bevacizumab would not result in significant visual improvement²².

Limitation of our study was the small sample size. We did not study the association of vascular patterns of macula on OCTA with decreased visual acuity, which is also a contributory factor in decreased visual acuity.

CONCLUSION

Thus based on our study results, 45µm reduction in central macular thickness is associated with 0.1 LogMAR unit improvement in visual acuity in patients with Diabetic Macular edema after a single dose of Intravitreal Bevacizumab (1.25 mg).

Ethical Approval

The study was approved by the Institutional review board/Ethical review board.

Conflict of Interest

Authors declared no conflict of interest.

Author's Designation and Contribution

Muhammad Ali Haider; Assistant Professor: *Study Design, Data collection, Manuscript writing, and review.*

Uzma Sattar; Optometrist: *Compiling Results, Data Analysis, Article review.*

REFERENCES

1. **Bahrami B, Hong T, Gilles MC, Chang A.** Anti-VEGF Therapy for Diabetic Eye Diseases. *Asia Pac J Ophthalmol (Phila)*. 2017 Nov-Dec; **6 (6)**: 535-545. Doi: 10.22608/APO.2017350.
2. **Lam DS, Lai TY, Lee VY, Chan CK, Liu DT, Mohamed S, et al.** Efficacy of 1.25 MG versus 2.5 MG intravitreal bevacizumab for diabetic macular edema: six-month results of a randomized controlled trial. *Retina*. 2009; **29 (3)**: 292-9.
3. **Keane PA, Liakopoulos S, Chang KT, Wang M, Dustin L, Walsh AC, et al.** Relationship between optical coherence tomography retinal parameters and visual acuity in neovascular age-related macular degeneration. *Ophthalmology*, 2008; **115 (12)**: 2206-14.
4. **Yang J, Wang X, Fuh G, Yu L, Wakshull E, Khosraviani M, et al.** Comparison of binding characteristics and in vitro activities of three inhibitors of vascular endothelial growth factor A. *Mol Pharm*. 2014; **11 (10)**: 3421-30.
5. **Demirel S, Argo C, Agarwal A, Parriott J, Sepah YJ, Do DV, et al.** Updates on the Clinical Trials in Diabetic Macular Edema. *Middle East Afr J Ophthalmol*. 2016; **23 (1)**: 3-12.
6. **Pescosolido N, Pranno F, Buomprisco G.** Intravitreal injections and diabetic macular edema: actual and new therapeutic options. *Curr Diabetes Rev*. 2013; **9 (6)**: 491-8.
7. **Vyas S, Thapa R, Bajimaya S, Pradhan E, Paudyal G.** Anatomical and visual outcome of intravitreal bevacizumab (Avastin) in patients with diabetic macular edema. *Nepal J Ophthalmol*. 2016; **8 (15)**: 54-61.
8. **Das T, Aurora A, Chhablani J, Giridhar A, Kumar A, Raman R, et al.** Evidence-based review of diabetic macular edema management: Consensus statement on Indian treatment guidelines. *Indian J Ophthalmol*. 2016; **64 (1)**: 14-25.
9. **Sala-Puigdollers A, Figueras-Roca M, Hereu M, Hernandez T, Morato M, Adan A, et al.** Repeatability and reproducibility of retinal and choroidal thickness measurements in Diabetic Macular Edema using Swept-source Optical Coherence Tomography. *PloS one*, 2018; **13 (7)**: e0200819.
10. **Browning DJ, Glassman AR, Aiello LP, Beck RW, Brown DM, et al.** Diabetic Retinopathy Clinical Research Network. Relationship between optical coherence tomography-measured central retinal thickness and visual acuity in diabetic macular edema. *Ophthalmology*, 2007; **114 (3)**: 525-36.
11. **Bhende M, Shetty S, Parthasarathy MK, Ramya S.** Optical coherence tomography: A guide to interpretation of common macular diseases. *Indian J Ophthalmol*. 2018; **66 (1)**: 20-35.

12. **Hanhart J, Tiosano L, Averbukh E, Banin E, Hemo I, Chowers I, et al.** Fellow eye effect of unilateral intravitreal bevacizumab injection in eyes with diabetic macular edema. *Eye*, 2014; **28 (6)**: 646-53.
13. **Maturi RK, Bleau L, Saunders J, Mubasher M, Stewart MW.** A 12-Month, Single-Masked, Randomized Controlled Study of Eyes with Persistent Diabetic Macular Edema after Multiple Anti-VEGF Injections to Assess the Efficacy of the Dexamethasone-Delayed Delivery System as an Adjunct to Bevacizumab Compared with Continued Bevacizumab Monotherapy. *Retina*, 2015; **35 (8)**: 1604-14.
14. **Tareen IU, Rahman A, Mahar PS, Memon MS.** Primary effects of intravitreal bevacizumab in patients with diabetic macular edema. *Pak J Med Sci*. 2013; **29 (4)**: 1018-22.
15. **Ristic D, Vukosavljevic M, Draganic B, Cerovic V, Petrovic N, Janicjevic-Petrovic M.** The effect of intravitreal administration of bevacizumab on macular edema and visual acuity in age-related macular degeneration with subfoveal choroidal neovascularisation. *Vojnosanitetski pregled*. 2013; **70 (7)**: 660-3.
16. **Santos AR, Gomes SC, Figueira J, Nunes S, Lobo CL, Cunha-Vaz JG.** Degree of decrease in central retinal thickness predicts visual acuity response to intravitreal ranibizumab in diabetic macular edema. *Ophthalmologica*. 2014; **231 (1)**: 16-22.
17. **Mansourian M, Kazemnejad A, Kazemi I, Zayeri F, Soheilian M.** Using skew-symmetric mixed models for investigating the effect of different diabetic macular edema treatments by analyzing central macular thickness and visual acuity responses. *J Res Med Sci*. 2011; **16 (10)**: 1319-25.
18. **Yang XL, Zou HD, Xu X.** Correlation of retinal sensitivity, visual acuity and central macular thickness in different types of diabetic macular edema. *Chinese J Ophthalmol*. 2013; **49 (12)**: 1081-8.
19. **Jeong SH, Kim JH, Kim JW, Lee TG, Kim CG, Yoo SJ, et al.** Patient's self-recognition of reduced visual acuity due to recurrence of macular edema and prompt visitation to the hospital in retinal vein occlusion. *Korean J Ophthalmol*. 2014; **28 (3)**: 213-9.
20. **Deak GG, Schmidt-Erfurth UM, Jampol LM.** Correlation of Central Retinal Thickness and Visual Acuity in Diabetic Macular Edema. *JAMA Ophthalmology*, 2018.
21. **Scott IU, VanVeldhuisen PC, Ip MS, Blodi BA, Oden NL, King J, et al.** Baseline Factors Associated with 6-Month Visual Acuity and Retinal Thickness Outcomes in Patients with Macular Edema Secondary to Central Retinal Vein Occlusion or Hemiretinal Vein Occlusion: SCORE2 Study Report4. *JAMA ophthalmology*, 2017; **135 (6)**: 639-49.
22. **Epstein DL, Algvere PV, von Wendt G, Seregard S, Kvanta A.** Benefit from bevacizumab for macular edema in central retinal vein occlusion: twelve-month results of a prospective, randomized study. *Ophthalmology*, 2012; **119 (12)**: 2587-91.

