

# First Crack Guided Conservative Posterior Capsulotomy Using Neodymium: YAG Laser

Syed Imtiaz Ali Shah, Shujaat Ali Shah, Partab Rai, Safdar Ali Abbasi, Naeem Akhtar Katpar

*Pak J Ophthalmol 2016, Vol. 32, No. 3*

See end of article for authors affiliations

Correspondence to:  
Prof. Syed Imtiaz Ali Shah  
Syed Eye Clinic, Ratodero Road  
Larkana, Sindh – Pakistan  
Email:  
syedimtiazalinaqvi@yahoo.com

**Purpose:** To report a new method of Nd: YAG laser posterior capsulotomy (first crack guided conservative posterior capsulotomy).

**Study Design:** Prospective case series study.

**Place and duration of study:** From January 2001 to January 2015 at the Department of Ophthalmology, Chandka Medical College Hospital, Larkana, Pakistan.

**Material and Methods:** In this study, 670 eyes of 623 patients with clinically diagnosed posterior capsular opacification following extra capsular cataract extraction or phacoemulsification and posterior chamber IOL implantation, were included. Patients with Aphakia, Anterior chamber IOL, High myopia, Uveitis, Uncontrolled glaucoma, Maculopathies, Optic nerve diseases and patients below 20 years of age were excluded from the study. Pre-procedure best corrected visual acuity (BCVA) and IOP was noted and complete clinical examination was done. Nd: YAG laser posterior capsulotomy was performed. The patients were seen one hour after capsulotomy, then after 24 hours and then weekly for 3 weeks. Post-procedure best corrected visual acuity (BCVA) and any complications seen were recorded. SPSS version 20 was used for data entry and analysis.

**Results:** Out of the total 623 patients 398 (63.88%) were males and 225 (36.12%) were females. Mean age  $\pm$  standard deviation was  $55.39 \pm 13.16$  years and age range was 20 to 78 years. Most of the patients belonged to the 51 – 60 years age group. Interval between cataract surgery and Nd: YAG laser posterior capsulotomy ranged from 6 months to 60 months. 652 (97.31%) patients showed improvement of the best corrected visual acuity (BCVA) after Nd: YAG laser posterior capsulotomy. Most common complications seen after the procedure were transient uveal reaction, transient rise in IOP and intra ocular lens (IOL) pitting.

**Conclusion:** First crack guided conservative posterior capsulotomy using Nd: YAG laser has proved to be a quick, safe, efficient and cost effective method in our setting.

**Keywords:** Cataract surgery, Posterior capsule opacification, Nd: YAG laser, Posterior capsulotomy, Complications.

Posterior capsular opacification (PCO) is the most common late onset post operative complication of standard cataract surgery including phacoemulsification<sup>1</sup>. It still remains the most challenging complication of modern cataract surgery despite significant improvements in the

techniques of surgery, IOL materials and designs. Posterior capsular opacification occurs due to proliferation of the left over lens epithelial cells after cataract extraction and a peculiar change occurring in them which turns them into myofibroblasts<sup>2</sup>. These myofibroblasts contract to cause thickening and wrinkling of the posterior capsule and as the process progresses further, the sheets of fibroblastic proliferation are seen entering into the central area (visual axis) that cause visual disturbance. The incidence of PCO is reported to be as much as 100%<sup>5</sup> in children, however most of the studies report PCO incidence to be around 20% to 50%<sup>4,5</sup>. After being reported as a treatment modality for PCO more than three decades ago<sup>3</sup>; Nd: YAG laser has taken over as the gold standard for performing posterior capsulotomy. The cutting effect is achieved by way of ionizing effect of the laser leading to plasma formation and photo-disruption of the target tissue. Although it is accepted as an effective procedure for the management of posterior capsular opacification, Nd: YAG laser posterior capsulotomy can lead to sight – threatening complications<sup>11</sup>. Several techniques have been used for performing Nd: YAG laser posterior capsulotomy, like cross pattern method<sup>6</sup>, can opener method<sup>7</sup>, inverted U method<sup>8</sup>, racquet shaped method<sup>9</sup> and circular with vitreous strand cutting method<sup>10</sup>. All techniques have been employed to achieve maximum visual improvement with minimum complications but all of them have their advantages, limitations and drawbacks as well. In this research study we are reporting a new method of Nd: YAG laser posterior capsulotomy and we have termed it as “first crack guided conservative posterior capsulotomy”.

### Material and Methods

This was a prospective case series study of 670 eyes of 623 patients, conducted from January 2001 to January 2015 at the Department of Ophthalmology, Chandka Medical College Hospital, Larkana, Pakistan after approval from institutional Ethical Review Committee. Patients with PCO following extra capsular cataract extraction or phacoemulsification and posterior chamber IOL implantation were included in the study. Definite diagnosis of PCO was made clinically by senior ophthalmologist. Patients below 20 years of age, patients with aphakia, anterior chamber IOL, high myopia, uveitis, uncontrolled glaucoma, maculopathies and optic nerve diseases were excluded from the study. With the help of available data and history, actual dates of cataract

surgery were noted and pre-procedure best corrected visual acuity (BCVA) was also noted. Slit lamp examination, Applanation Tonometry and Fundoscopy was performed on all cases before patient was taken for Nd: YAG laser posterior capsulotomy.

Patient was seated comfortably in dimly lighted room of consultant for approximately one hour, while consultant kept on examining the other patients. This kept the patient awake and the pupil dilates physiologically. Then the patient was taken to Nd: YAG laser equipment and the laser beam was focused on the posterior capsule at 12 o'clock position just inferior to the superior pupil margin. The posterior YAG laser offset was kept on 150  $\mu$ m in all cases, to avoid IOL pitting. The Nd: YAG laser energy level was set at 1 millijoule and when the pupil was seen to acquire dilating phase of hippus, the first shot was fired. If crack was observed at 1 millijoule, the process was continued at the same energy level but if crack was not observed than the energy level was increased with 0.5 millijoule steps till crack was achieved Fig. 1. The direction of first crack was observed and further shots were aimed in the line of dehiscence of the crack Fig. 2. The line of crack usually advanced quickly with few shots and capsular flaps gave way. In some cases where crack remained as a cut Fig. 3, few shots were given to the edges and an adequate opening was achieved quickly Fig. 4. Wherever needed, a few shots were aimed to displace the flaps downwards or sideways, away from the visual axis.

The patients were seen one hour after capsulotomy, then after 24 hours and then weekly for 3 weeks. During these follow up examinations, post-procedure best corrected visual acuity (BCVA) was recorded, patients were seen on slit lamp, applanation tonometry and detailed fundus examination was performed. Increase in the best corrected visual acuity (BCVA) of at least one line on the Snellen's chart was considered as improvement in visual acuity. Any complications seen were recorded and treatment was prescribed accordingly. SPSS version 20 was used for data entry and analysis.

### RESULTS

A total of 670 eyes of 623 patients were included in the study. Out of these 623 patients 398 (63.88%) were males and 225 (36.12 %) were females (Figure 2). Mean age  $\pm$  standard deviation was 55.39  $\pm$  13.16 years and age range was 20 to 78 years. Most of the patients belonged to the 51 – 60 years age group (Table 1). IOL material type used was hydrophobic acrylic in 214




Fig. 1:

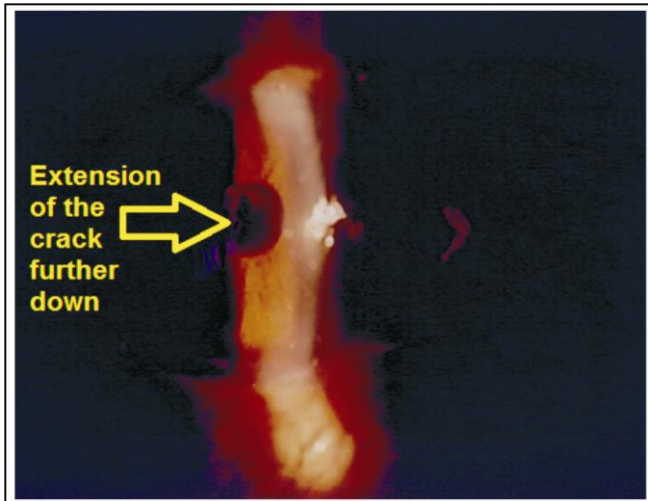


Fig. 2:

(31.94%) eyes and polymethylmethacrylate (PMMA) in 456 (68.06%) eyes (Table 2). Interval between cataract surgery and Nd: YAG laser posterior capsulotomy ranged from 6 months to 60 months in different patients, but the interval was 37 months to 48 months in majority 167 (24.9 %) of the patients (Table 3). Energy level used for the procedure ranged from 1 millijoule to 2.5 millijoule and the number of shots ranged from 3 to 19. Maximum energy used in a case was 44.5 millijoule (range: 3 millijoule to 44.5 millijoule). 652 (97.31%) patients showed improvement of the best corrected visual acuity (BCVA) after Nd: YAG laser posterior capsulotomy (Figure 2). Complications seen after the procedure

were transient uveal reaction in 331 (49.4%) patients, transient rise in IOP in 219 (32.7%) patients, intra ocular lens (IOL) pitting in 53 (7.9%) patients, clinical macular edema in 18 (2.7%) patients and retinal detachment in 3 (0.4 %) cases (Table 4).

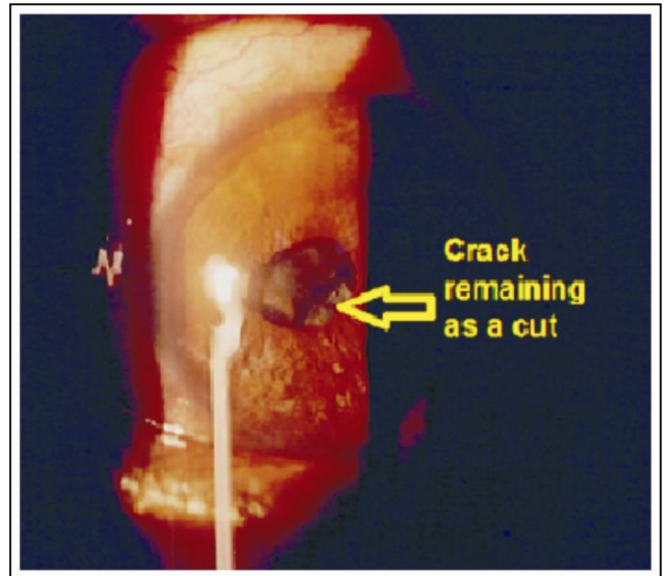


Fig. 3:

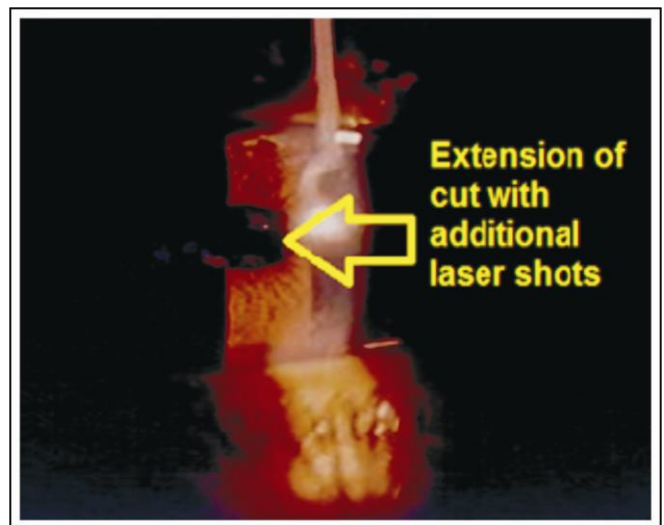


Fig. 4:

## DISCUSSION

Nd: YAG laser posterior capsulotomy is a quick and effective method for the treatment of posterior capsular opacification but some complications may occur. Improvement in visual acuity after Nd: YAG

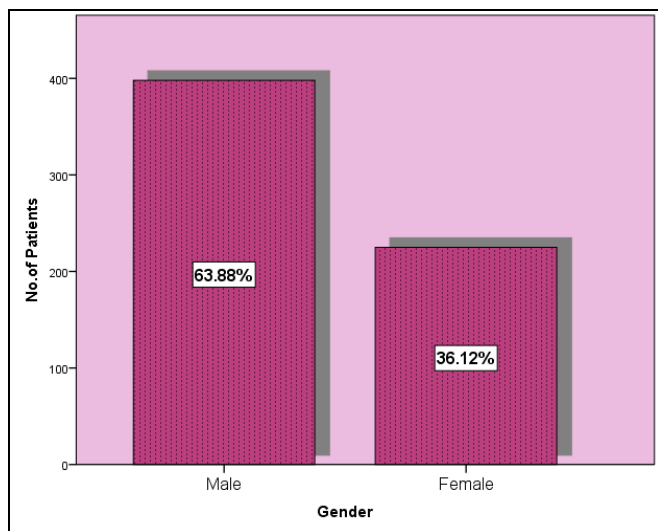


Figure 5:

Table 1:

Age Group	No. of Patients	Percentage
20 - 30 years	60	9.6%
31 - 40 years	23	3.7%
41 - 50 years	46	7.4%
51 - 60 years	291	46.7%
61 - 70 years	148	23.8%
71 - 78 years	55	8.8%
Total	623	100%

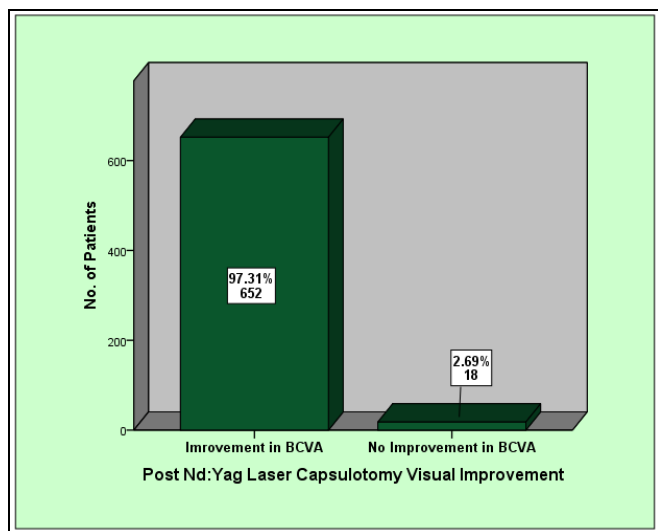


Figure 6:

Table 2:

Type of IOL Material	No: of Eyes	Percentage
Polymethylmethacrylate (PMMA)	456	68.06 %
Hydrophobic acrylic material	214	31.94 %
Total No: of Eyes	670	100 %

Table 3:

Interval between Cataract Surgery and Capsulotomy	No. of Eyes	Percentage
6 - 12 Months	125	18.7%
13 - 24 Months	136	20.3%
25 - 36 Months	149	22.2%
37 - 48 Months	167	24.9%
49 - 55 Months	87	13.0%
56 - 60 Months	6	0.9%
Total No: of Eyes	670	100%

Table 4:

Complications	No. of Eyes	Percentage
Transient Rise in IOP	219	32.7%
Transient Uveal Reaction	331	49.4%
Lens Pitting	53	7.9%
Clinical Macular Edema	18	2.7%
Retinal Detachment	3	0.4%

laser posterior capsulotomy has been reported to be 96% by Min JK et al<sup>10</sup>, 96.9% by Khanzada MA et al<sup>12</sup>, 100% by Zeki SM et al<sup>8</sup> and it was 97.31% in our study. Various complications after Nd: YAG laser posterior capsulotomy have been reported, like IOL dislocation<sup>15</sup>, damage<sup>13</sup>, pitting<sup>12</sup>, increased IOP<sup>14</sup>, Uveitis<sup>15</sup>, cystoid macular edema<sup>16,17</sup>, rupture of anterior vitreous face<sup>18,19</sup>, hyphaema<sup>15</sup>, endophthalmitis<sup>15,21</sup>, aqueous misdirection syndrome<sup>20</sup> and retinal detachment<sup>22,23</sup>. Our study has also observed some of these complications, which are

shown in Table 4, but they were mild, transient and resolved with appropriate treatment. Incidence of retinal detachment in our study was so low that any causal relationship between Nd: YAG laser posterior capsulotomy and retinal detachment seems unlikely, as has been suggested by Nielsen NE et al<sup>25</sup> as well. Min JK et al<sup>10</sup> have reported no complications in their study, probably due to preventive measures like use of steroids and IOP lowering drugs. We did not use any drug post-procedure and prior to the development of complications, to observe the accurate effects of First Crack Guided Conservative Nd: YAG Laser Posterior Capsulotomy on the ocular structures. According to some studies, capsulotomy size and laser energy levels are directly proportional to the post-capsulotomy complications<sup>16,17,24</sup>. Our method, "First crack guided conservative posterior capsulotomy" using Nd: YAG laser utilizes least energy as the crack is assisted by contractile forces of the posterior capsule and capsulotomy site and size is physiological owing to utilization of physiologically dilated pupil during the procedure. In other methods, where pharmacological mydriasis is used, there is a risk of performing an undesirably big and/or decentered capsulotomy. In our method, patient sitting in a dark room usually achieves maximum physiological dilatation of pupil within an hour and when the patient is taken to YAG laser, the pupil starts contracting but the patient's dilating phase of hippus is already facilitated and is utilized giving a physiologic capsular opening. As the crack line is followed in this method, the tear guides its own course and capsulotomy is achieved quickly with least number of shots and hence least amount of laser energy. This not only causes lesser number of complications but also prolongs the life of laser cavity of the machine. Patient is comfortable before and after the procedure with quick visual recovery because less laser energy causes less pigment bleaching and there is no photophobia as pupil is not pharmacologically dilated.

## CONCLUSION

First crack guided conservative posterior capsulotomy using Nd: YAG laser has proved to be a quick, safe, efficient and cost effective method in our setting. It has the beauty of patient comfort and satisfaction, it is superior to other methods being utilized presently as it leads to perfectly centered capsulotomy, no photophobia and least complications due to least energy used inside the eye.

## Authors Affiliation

Syed Imtiaz Ali Shah  
FCPS, Professor, Department of Ophthalmology,  
Chandka Medical College/SMBB Medical University  
Larkana

Shujaat Ali Shah  
Trainee Registrar, Department of Ophthalmology,  
Chandka Medical College/SMBB Medical University  
Larkana

Partab Rai  
FCPS, Professor, Department of Ophthalmology,  
Chandka Medical College/SMBB Medical University  
Larkana

Safdar Ali Abbasi  
Ophthalmologist, Department of Ophthalmology,  
Chandka Medical College Larkana

Naeem Akhtar Katpar  
Ophthalmologist, Department of Ophthalmology,  
Chandka Medical College Larkana

## Role of Authors:

Dr. Syed Imtiaz Ali Shah  
Reviewed the case, images, and gave final approval of the manuscript to be published.

Dr. Shujaat Ali Shah  
Did Literature search, Drafted the manuscript,  
Reviewed the case, images, and did the analysis.

Dr. Partab Rai  
Reviewed the case, images, and revised the manuscript.

Dr. Safdar Ali Abbasi  
Involved in data collection and review of manuscript.

Dr. Naeem Akhtar Katpar  
Involved in data collection and review of cases.

## REFERENCES

1. **Wormstone IM.** Posterior capsule opacification: a cell biological perspective. *Exp Eye Res.* 2002; 74 (3): 337-47.
2. **Nishi O, Nishi K.** Intraocular lens encapsulation by shrinkage of the capsulorhexis opening. *J Cataract Refract Surg.* 1993; 19: 544-5.
3. **Aron-Rosa D, Aron JJ, Griesemann M, Thyzel R.** Use of the neodymium-YAG laser to open the posterior capsule after lens implant surgery: a preliminary report. *J Am Intraocul Implant Soc.* 1980; 6 (4): 352-4.
4. **Nakazawa M, Ohtsuki K.** Apparent accommodation in pseudophakic eyes after implantation of posterior chamber intraocular lenses. *Am J Ophthalmol.* 1983; 96(4): 435-8.

5. **Kim MJ, Lee HY, Joo CK.** Posterior capsule opacification in eyes with a silicone or poly methyl methacrylate intraocular lens. *J Cataract Refract Surg.* 1999; 25 (2): 251-5.
6. **Levy JH, Pisacano AM.** Comparison of techniques and clinical results of YAG laser capsulectomy with two Q-switched units. *J Am Intraocul Implant Soc.* 1985; 11 (2): 131-3.
7. **Murrill CA, Stanfield DL, Van Brocklin MD.** Capsulotomy. *Optom Clin.* 1995; 4 (4): 69-83.
8. **Zeki SM.** Inverted U' strategy for short pulsed laser posterior capsulotomy. *Acta Ophthalmol Scand.* 1999; 77 (5): 575-7.
9. **Shaikh MA, Shah SIA, Siddiqui SJ, Shaikh AH, Shaikh KR:** The Short Term and Long Term Complications of Racquet Shaped Nd: Yag Posterior Capsulotomy. *Ophthalmology Update,* 2014; 12 (4): 270-2.
10. **Min JK, An JH, Yim JH.** A new technique for Nd: YAG laser posterior capsulotomy. *Int J Ophthalmol.* 2014; 7 (2): 345-9.
11. **Billotte C, Berdeaux G.** Adverse clinical consequences of neodymium: YAG laser treatment of posterior capsule opacification. *J Cataract Refract Surg.* 2004; 30 (10): 2064-71.
12. **Khanzada MA, Jatoi SM, Narsani AK, Dabir SA, Gul S.** Is the Nd: YAG laser a safe procedure for posterior capsulotomy? *Pak J Ophthalmol.* 2008; 24 (2): 73-8.
13. **Newland TJ, McDermott ML, Elliott D, Hazlett LD, Apple DJ, Lambert RJ, Barrett RP.** Experimental neodymium: YAG laser damage to acrylic, poly methyl methacrylate, and silicone intraocular lens materials. *J Cataract Refract Surg.* 1999; 25 (1): 72-6.
14. **Ge J, Wand M, Chiang R, Paranhos A, Shields MB.** Long-term effect of Nd: YAG laser posterior capsulotomy on intraocular pressure. *Arch Ophthalmol.* 2000; 118 (10): 1334-7.
15. **Khan B, Alam M, Shah MA, Bashir B, Iqbal A, Alam A.** Complications of Nd: YAG Laser Capsulotomy. *Pak J Ophthalmol.* 2014; 30 (3): 133-6.
16. **Steinert RF, Puliafito CA, Kumar SR, Dudak SD, Patel S.** Cystoid macular edema, retinal detachment, and glaucoma after Nd: YAG laser posterior capsulotomy. *Am J Ophthalmol.* 1991; 112 (4): 373-80.
17. **Ari S, Cingu AK, Sahin A, Inar YC, Caca I.** The effects of Nd: YAG laser posterior capsulotomy on macular thickness, intraocular pressure, and visual acuity. *Ophthalmic Surg Lasers Imaging,* 2012; 43 (5): 395-400.
18. **Harris WS, Herman WK, Fagadau WR.** Management of the posterior capsule before and after the YAG laser. *Trans Ophthalmol Soc.* 1985; 104: 533-5.
19. **Ficker LA, Steel AD.** Complications of Nd: YAG laser posterior capsulotomy. *Trans Ophthalmol Soc.* 1985; 104: 529-32.
20. **Mastropasqua L, Ciancaglini M, Carpineto P.** Aqueous misdirection syndrome: a complication of neodymium: YAG posterior capsulotomy. *J Cataract Refract Surg.* 1994; 20 (5): 563-5.
21. **Carlson AN, Koch DD.** Endophthalmitis following Nd:YAG laser posterior capsulotomy. *Ophthalmic Surg.* 1988; 19 (3): 168-70.
22. **Raza A.** Complications after Nd: Yag posterior capsulotomy. *J Rawalpindi Med Coll.* 2007; 11: 27-9.
23. **Burq MA, Taqui AM.** Frequency of Retinal Detachment and Other Complications after Neodymium: Yag Laser Capsulotomy. *J Pak Med Assoc.* 2008; 58 (10): 550-2.
24. **Karahan E, Er D, Kaynak S.** An Overview of Nd:YAG Laser Capsulotomy. *Med Hypothesis Discov Innov Ophthalmol.* 2014; 3 (2): 45-50.
25. **Nielsen NE, Naeser K.** Epidemiology of retinal detachment following extracapsular cataract extraction: a follow-up study with an analysis of risk factors. *J Cataract Refract Surg.* 1993; 19 (6): 675-80.