

# Efficacy of Intra-vitreous Bevacizumab for Resolution of Macular Edema Secondary to Central Retinal Vein Occlusion

Muhammad Younis Tahir, Afshan Ali

*Pak J Ophthalmol 2015, Vol. 31 No. 2*

See end of article for authors affiliations

Correspondence to:  
Muhammad Younis Tahir  
Ophthalmology Department  
BVH/Qamc, Bahawalpur

**Purpose:** To determine the efficacy of intravitreal injection of Bevacizumab in resolution of macular edema in patients of central retinal vein occlusion.

**Material and Methods:** It was a descriptive case series, conducted at Institute of Ophthalmology unit III, Mayo Hospital Lahore and Bahawal – Victoria Hospital Bahawalpur simultaneously. A total of 60 cases were selected through purposive sampling for this study. Diagnosis was ascertained on fundus fluorescein angiography. Pre and post injection macular edema was measured on optical coherence tomography on the day of drug administration and thirty days after it.

**Results:** Mean macular thickness before treatment was  $663.10 \pm 109.76$  microns and after treatment mean thickness was  $453.06 \pm 106.09$  microns which was a significant ( $p = 0.0000001$ ) finding. Majority (75%) of patients achieved a reduction of  $\geq 200$  microns in their retinal thickness after treatment. Whereas in the remaining 15 (25%) patients reduction in retinal thickness was  $< 200$  microns. These findings were independent of gender bias.

**Conclusion:** Intravitreal injection of Bevacizumab is effective in the resolution of macular edema in the patients of central retinal vein occlusion.

**Key words:** Central retinal vein occlusion, macular edema, Bevacizumab.

Central retinal vein occlusion (CRVO) is the second most common retinal vascular disorder<sup>1</sup> with incidence of 0.5% and prevalence of 1.3%.<sup>1,2</sup> It is thought to be caused by thrombus formation in at the level of lamina cribrosa.<sup>3</sup> CRVO is characterized by edema of the optic nerve, retinal hemorrhages and marked vascular dilatation and tortuosity.<sup>4</sup> Fluorescein angiography is used as a diagnostic tool for CRVO and it also classifies it into ischemic and non-ischemic types on the basis of degree of retinal capillary non perfusion.<sup>5</sup> Ischemia induces a rise in intraocular levels of vascular endothelial growth factor (VEGF)<sup>6</sup> – a cytokine which not only increases vascular permeability which leads to macular edema but also stimulates endothelial cell hypertrophy, thus reducing the capillary lumen, causing more ischemia and perpetuating further edema.<sup>7</sup> If left untreated, persistent macular edema,

macular ischemia and neovascular glaucoma can lead to visual morbidity and blindness.<sup>2,8</sup> To date, no effective and safe therapy has been found for macular edema secondary to central retinal vein occlusion. Intravitreal injection of steroids such as triamcinolone acetonide initially showed some promising results but later it was found to be associated with unacceptable ocular complications.<sup>4</sup>

Bevacizumab is a monoclonal antibody that inhibits VEGF and has been advocated to facilitate resolution of macular edema by breaking VEGF cycle which is critical for perpetuating macular edema in the setting of CRVO as a famous study<sup>7</sup> has shown a decrease of 200 microns in macular thickness from baseline in at least one third of patients, one month after the injection. In another study, in addition to all these changes, significant reduction in venous dilation, tortuosity, optic disc swelling was also found.<sup>9</sup>

Current study was the first of its kind in local population of Punjab, Pakistan to explore the efficacy of this drug in resolving macular edema due to central retinal vein occlusion. It has also provided data for comparison with the results from studies being conducted across the globe.

## MATERIAL AND METHODS

It was a descriptive case series, conducted at Institute of Ophthalmology unit III, Mayo Hospital Lahore and Bahawal - Victoria hospital simultaneously. A total of 60 cases central retinal vein occlusion were selected after informed written consent of patients and approval of institutional ethics committee. Sample size was selected through purposive sampling technique through following criteria;

### Inclusion criteria

- Both genders.
- Age more than or equal to 20 years.
- Central retinal vein occlusion in one eye of the patients diagnosed on fluorescein angiography as per operational definition.
- Macular edema of equal to or more than 300 microns at baseline confirmed by optical coherence tomography.

### Exclusion criteria

- Previously treated according to history.
- Cases of increased intraocular pressure (more than 21mm Hg) evidenced by applanation tonometry.
- Filtration surgery, corneal transplantation, cataract surgery three months prior to baseline assessed on slit lamp examination.
- Diabetic retinopathy in rapid progression confirmed by fluorescein angiography.
- Vitreous hemorrhage seen on ultrasonography.
- Pregnancy according to ultrasound findings.

The diagnosis of central retinal vein occlusion was made if delayed arteriovenous transit time (more than 12 seconds), blockage by hemorrhages, good retinal capillary perfusion (non-ischemic type), capillary non perfusion (ischemic type) and leakage was observed on Fluorescein angiography. Macular edema was defined as retinal thickness of more than or equal to 300 microns confirmed by the presence of intra-retinal cysts in the central macular area on optical coherence tomography (OCT).

The main outcome measure was efficacy of Bevacizumab which was defined in terms of resolution of macular edema on OCT measured in microns. Edema was considered resolved if the decrease in retinal thickness is equal to or more than 200 microns from the baseline measurement after one month of giving injection.

Demographic information like name, age and gender was recorded. Pre and post treatment macular edema was measured by optical coherence tomography. All the information collected was noted on a special proforma attached. All patients received ciprofloxacin antibiotic drops for three days pre and post treatment. Intravitreal injection of 1.25 mg Bevacizumab in 0.05 ml total volume was given via superior pars plana area, under aseptic condition after topical anesthesia of lidocaine. To avoid bias the whole procedure was done by a single skilled surgeon and all the observations were recorded by a single observer. Follow up was done after one month and documenting the post treatment macular edema on optical coherence tomography. Final reading was taken at the end of one month. Complications if any, were dealt with accordingly.

## RESULTS

Males (n = 36, 60%) and females (n = 24, 40%) having mean age of  $58.83 \pm 9.33$  and  $58.75 \pm 8.19$  years respectively having macular edema due to CRVO were treated with intravitreal injection of Bevacizumab. Mean macular thickness before and after treatment was  $663.10 \pm 109.76$  and  $453.06 \pm 106.09$  microns respectively as shown in Table 1 and Fig. 1. Macular thickness before treatment among male and female patients was  $667.27 \pm 108.30$  and  $656.83 \pm 113.96$  microns. After treatment mean Macular thickness among male and female patients was  $463.30 \pm 106.03$  and  $437.70$  respectively. It was clear after treatment significant reduction in Macular thickness was observed as shown in Table 2 and Fig. 2.

Efficacy criteria was set as decrease in retinal thickness  $\geq 200$  microns. Keeping in mind this criteria there were 45 (75%) patients in which retinal thickness decrease from baseline was  $\geq 200$  microns after treatment. Whereas the remaining 15 (25%) patients retinal thickness was  $< 200$  microns showing no efficacy of treatment for these patients. Among male patients efficacy of treatment (Retinal thickness  $\geq 200$  microns) was observed among 25 (69.4%) whereas among female patients efficacy of treatment was observed in 20 (83.3%) patients as shown in Table 3

**Table 1:** Macular thickness on OCT before and after treatment.

	Macular Thickness on OCT (Microns)	
	Pre-Treatment	Post-Treatment
N	60	60
Mean	663.10	453.06
Standard Deviation	109.76	106.09
Range	407	450
Minimum	478	250
Maximum	885	700
P-value	0.000001	

**Table 2:** Macular thickness on OCT with respect to gender before and after treatment.

	Macular Thickness on OCT (Microns)			
	Male	Female	Male	Female
	Pre-Treatment	Post-Treatment	Pre-Treatment	Post-Treatment
N	36	24	36	24
Mean	667.27	656.83	463.30	437.70
Standard Deviation	108.30	113.96	106.03	106.55
Range	392	407	448	450
Minimum	489	478	250	250
Maximum	881	885	698	700

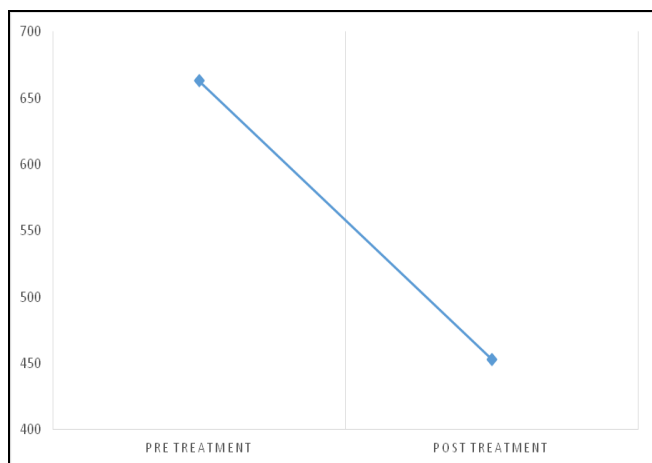
**Table 3:** Efficacy with respect to gender before and after treatment.

		Gender		Total n (%)
		Male n (%)	Female n (%)	
Efficacy	Yes	25 (69.4)	20 (83.3)	45 (75)
	No	11 (30.6)	4 (16.7)	15 (25)
Total		36 (100)	24 (100)	60 (100)
P-value		0.2240		

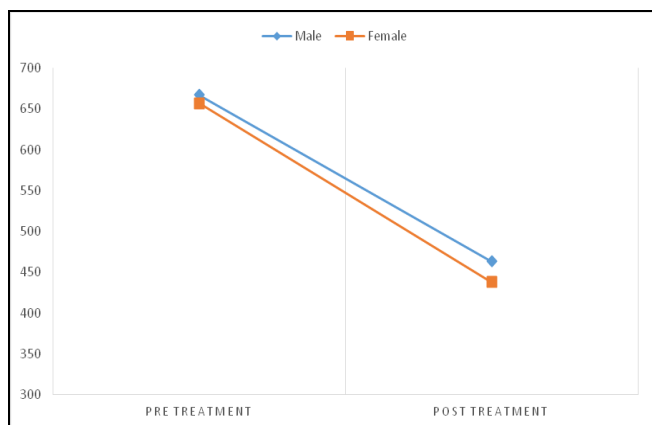
and Fig. 3. Pre and post-operative out of 2 patients are shown in Fig. 4 and 5.

## DISCUSSION

A definite therapeutic target for central retinal vein

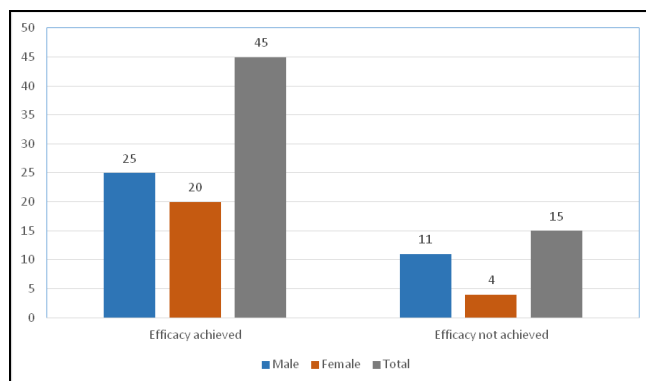


**Fig. 1:** Macular thickness on OCT before and after treatment.

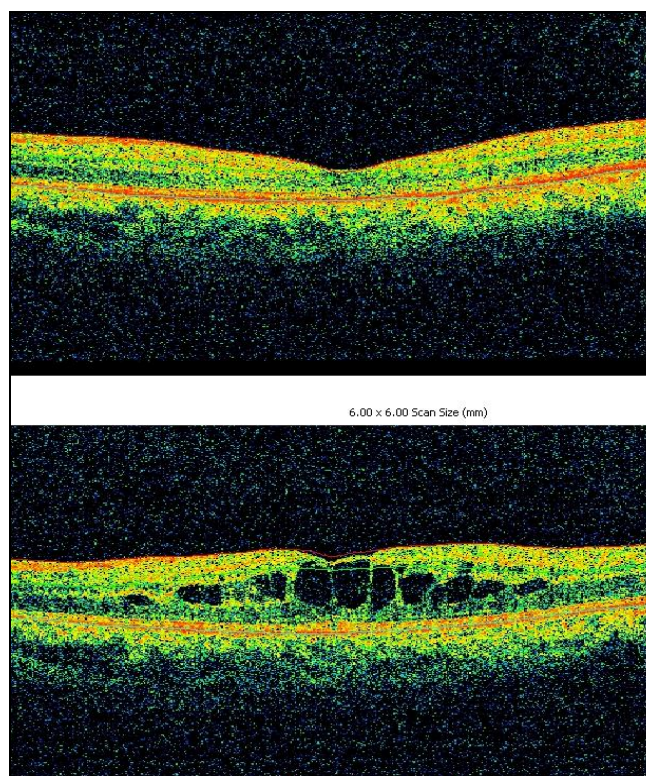


**Fig. 2:** Macular thickness on OCT (microns) before and after treatment; comparison of resolution between two genders.

occlusion has yet to be proclaimed. Much focus has been given to treat macular edema which arises secondarily in the setting of CRVO and causes markedly diminished and visual acuity.<sup>10</sup> Among the various treatment modalities that have been tried, many discarded either due to therapeutic failure or due to systemic or local complications were associated with their use, these included vitrectomy, radical optic neurotomy etc.<sup>11,12</sup> However, intra-vitreous injection of anti-angiogenic monoclonal antibody bevacizumab has shown promising results without any major adverse effects. Current study was an effort to investigate the repeatability and reliability of this claim in local circumstances, to validate the findings of previous similar reports and to add more data into an emerging area of wider interest where previous publications have in fact demanded further studies.



**Fig. 3:** Efficacy of treatment with respect to gender of patients.



**Fig. 4:** After and before treatment (OCT).

We observed that mean macular thickness before treatment was  $663.10 \pm 109.76$  microns which was reduced to a mean macular thickness of  $453.06 \pm 106.09$  microns after the treatment, which means almost 1/3<sup>rd</sup> reduction in simple arithmetic terms and highly significant in statistical terms thus proving the efficacy of the bevacizumab for the treatment of macular edema. Current study also shows that after one month of giving intra-vitreous bevcizumab, there is significant decrease in retinal thickness. This



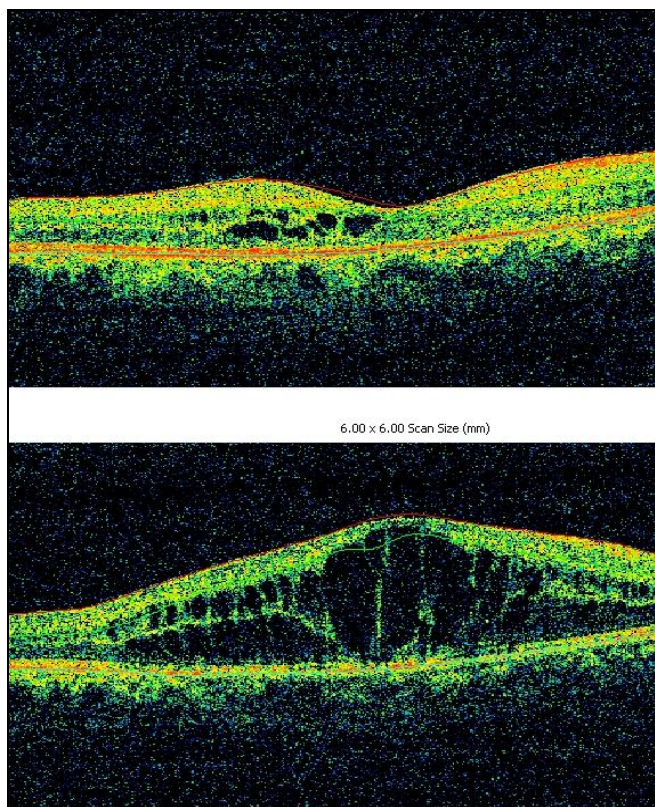


Fig. 5: After and before treatment OCT.

decrease is more than or equal to 200 microns from the baseline value which fulfills our efficacy criteria for bevacizumab in cases of macular edema secondary to CRVO. A total number of 60 patients were included in the study. Out of those, 75% patients showed a reduction of more than 200 microns in their retinal thickness from its baseline value. While in 25% patients the decrease in retinal thickness was less than 200 microns. As for the gender distribution, macular thickness before treatment among male and female patients was  $667.27 \pm 108.30$  and  $656.83 \pm 113.96$  microns. After treatment mean Macular thickness among male and female patients was  $463.30 \pm 106.03$  and  $437.70$  respectively. Similarly, 69.3% men and 83.3% women with macular edema were found to achieve a reduction of  $> 200$  microns in the retinal thickness. These findings show that the results were apparently more favorable in women however it was statistically not significant and we can say that our results were independent of gender.

Manayath et al., included 15 patients of retinal vein occlusion developing macular edema who were serially evaluated with best corrected visual acuity (BCVA), optical coherence tomography (OCT),

fluorescein angiography, and tonometry. Mean follow-up was  $12 \pm 3.6$  months (range, 6 - 18 months); mean number of injections was 2.2 (range, 1 - 4) per patient. They found statistically significant reduction of macular thickness ( $P < 0.001$ ) at six weeks (mean, 346  $\mu$ ); three months (mean, 353  $\mu$ ); six months (mean, 348  $\mu$ ); and final follow-up (mean, 342  $\mu$ ) and thus concluded that intravitreal Bevacizumab is effective for resolution of macular edema.<sup>13</sup> Another recent study by Thapa et al., also found similar results.<sup>14</sup>

Epstein et al. used different outcome measures for the trial of bevacizumab. Their primary outcome measure was the proportion of patients gaining at least 15 letters at 12 months. Secondary outcome measures included mean change from baseline best-corrected visual acuity (BCVA), change in foveal thickness, and development of neovascular glaucoma and they also found intra-vitreal injection of bevacizumab an effective therapy for the macular edema secondary to CRVO.<sup>15</sup>

These studies mentioned above show comparable findings. However, current study has larger sample size which makes our results more reliable as most of the other studies done on intravitreal Bevacizumab have a very small sample size. In South - east Asian region, not much research is done on role of Bevacizumab in cases of central retinal vein occlusion. So this study provides valuable data for treatment and further research on patients of CRVO.

There are a few limitations of our study as well. We are studying the effect of intravitreal bevacizumab on macular thickness one month after its administration. Although macular thickness shows a significant decrease in thickness i.e. 200 microns but in many cases residual thickness is still more than 300 microns, which means there might be need for further injections. Further study needs to be done on effects of multiple injections of intravitreal bevacizumab in cases of CRVO. Many studies have reported results of three intravitreal injections of Bevacizumab given on monthly basis in these patients. In our region research need to be carried out regarding this, and the possible adverse effects of long term administration of injection bevacizumab.

## CONCLUSION

Our study demonstrates that intra-vitreal injection of anti VEGF agent Bevacizumab is effective in resolution of macular edema in patients of central retinal vein occlusion.

**Author's Affiliation**

Dr. Afshan Ali  
Ophthalmology Department  
BVH / Qamc, Bahawalpur

Dr. Muhammad Younis Tahir  
Fellowship in Vitreo-Retina  
Assistant Professor  
Ophthalmology Department  
BVH / Qamc, Bahawalpur

**REFERENCES**

1. **Ehlers JP, Fekrat S.** Retinal Vein Occlusion: Beyond the Acute Event. *Survey of Ophthalmology.* 2011; 56: 281-99.
2. **Mohamed Q, Macintosh RL, Saw SM Wong TY.** Interventions for central retinal vein occlusion: an – evidence based systematic review. *Ophthalmology,* 2007; 114: 507-19.
3. **Pieramici DJ, Rabena M, Castellarin AA, Nasir M, See R, Norton T, Sanchez A, Risard S, Avery RL.** Ranibizumab for the Treatment of Macular Edema Associated with Perfused Central Retinal vein Occlusions *Ophthalmology,* 2008; 115: e47-54.
4. **Kinge B, Stordhal PB, Forsaa V, Fossen K, Haugstad M, Helgesen OH, Seland J, Stene-Johansen I.** Efficacy of Ranibizumab in Patients with Macular Edema secondary to central retinal vein occlusion: Results from the Sham – controlled ROCC Study. *Am J Ophthalmol.* 2010; 150: 310-14.
5. **Macintosh RL, Rogers SL, Lim L, Cheung N, Wang JJ, Mitchell P, Kowalski JW, Nguyen HP, Wong TY.** Natural History of Central Retinal Vein Occlusion: An – Evidence – Based Systematic Review. *Ophthalmology,* 2010; 117: 1113-23.
6. **Campochiaro PA, Hafiz G, Shah SM, Nguyen QD, Ying H, Do DV, Quinlan E, Zimmer-Galler I, Haller JA, Solomon SD, Sung JU, Hadi Y, Janjua KA, Jawed N, Choy DF, Arron JR.** Ranibizumab for macular edema due to retinal vein occlusions: implication of VEGF as a critical stimulator. *Mol Ther.* 2008; 16: 791–9.
7. **Figueroa MS, Contreras I, Noval S Arruabarrena C.** Results of bevacizumab as the primary treatment for retinal vein occlusions. *Br J Ophthalmol.* 2010; 94: 1052-6.
8. **Mehmood T.** Central retinal vein occlusion: current management options. *Pak J Ophthalmol.* 2009; 25: 1-4.
9. **Ferrara DC, Koizumi H, Spaide RF.** Early bevacizumab treatment of central retinal vein occlusion. *Am J Ophthalmol.* 2007; 144: 864–71.
10. **Yeh S, Kim SJ, Ho AC, Schoenberger SD, Bakri Sophie J, Ehlers JP, Thorne JE.** Therapies for Macular Edema Associated with Central Retinal Vein Occlusion: A Report by the American Academy of Ophthalmology. *Ophthalmology.* 2015; In Press.
11. **Arevalo JF, Garcia RA, Wu L, Rodriguez FJ, Dalma-Weiszhausz J, Quiroz-Mercado H, Morales-Canton V, Roca JA, Berrocal MH, Graue-Wiechers F, Robledo V.** Radial optic neurotomy for central retinal vein occlusion: results of the Pan-American Collaborative Retina Study Group (PACORES). *Retina,* 2008; 28: 1044-52.
12. **Leizaola-Fernandez C, Suarez – Tata L, Quiroz-Mercado H, Colina-Luquez J, Fromow-Guerra J, Jiménez-Sierra JM, Guerrero-Naranjo JL, Morales-Cantón V.** Vitrectomy with complete posterior hyaloid removal for ischemic central retinal vein occlusion: series of cases. *BMC Ophthalmol.* 2005; 5:10.
13. **Manayath GJ, Narendran V, Al-Kharousi N, Wali UK.** Bevacizumab therapy for macular edema in central retinal vein occlusion: Long-term results. *Oman J Ophthalmol.* 2009; 2: 73–8.
14. **Thapa, R., and G. Paudyal.** “63 Short term results of intra-vitreous bevacizumab for the treatment of macular edema secondary to retinal vein occlusion.” *Nepalese Journal of Ophthalmology,* 2013; 5.1: 63-8.
15. **Epstein DL, Alverve PV, von Wendt G, Seregard S, Kvanta A.** Benefit from Bevacizumab for Macular Edema in Central Retinal Vein Occlusion: Twelve-Month Results of a Prospective, Randomized Study. *Ophthalmology,* 2012 119: 2587-91.