

# Sheep in the Skin of a Wolf, An unusual Sub-Retinal Lesion

Tayyaba Gul Malik, Muhammad Khalil, Afzal Hussain

*Pak J Ophthalmol 2015, Vol. 31 No. 3*

See end of article for authors affiliations

**Purpose:** To describe a case of sub retinal hemorrhage mimicking as uveal tumour.

Correspondence to:  
Tayyaba Gul Malik  
Ophthalmology Department  
Lahore Medical and Dental  
College  
Email: tayyabam@yahoo.com

**Material and Methods:** Although new diagnostic techniques are emerging every now and then, indirect ophthalmoscopy is still a gold standard in the diagnosis of retino-choroidal lesions. Problems arise when media is not clear. OCT, FFA are not possible in hazy media and fine needle aspiration cytology carries a risk of seeding. There are other conditions like choroidal naevi, choroidal hemangiomas and hemorrhages which can be observed, but when it comes to choroidal melanoma, it becomes very important to diagnose it in time to prevent metastatic complication and death. A case of an 81 years old male is presented who had vitreous hemorrhage and a sub retinal mass. Age of the patient, size of the mass and B scan were quite confusing to exclude a choroidal malignancy. Pars plana vitrectomy was performed and the mass proved to be a sub retinal hemorrhage secondary to exudative age – related macular degeneration.

**Key Words:** Choroidal melanoma, sub retinal hemorrhage, Intra gel hemorrhage, choroidal lymphoma, choroidal metastasis, choroidal naevus.

**E**xudative type of age related macular degeneration is one of the commonest causes of irreversible vision loss. Sometimes rupture of choroidal neovascular membrane can lead to hemorrhagic retinal and retinal pigment epithelial detachments that, may be mistaken for choroidal melanoma which is the most common primary malignant intra ocular tumor and the second most common primary malignant melanoma of the body. It has a high mortality rate and the Collaborative Ocular Melanoma Study (COMS) has reported a misdiagnosis rate of 0.48%. There are reports in which benign choroidal lesions came out to be malignant and vice versa. One such case is discussed in relation to literature review.

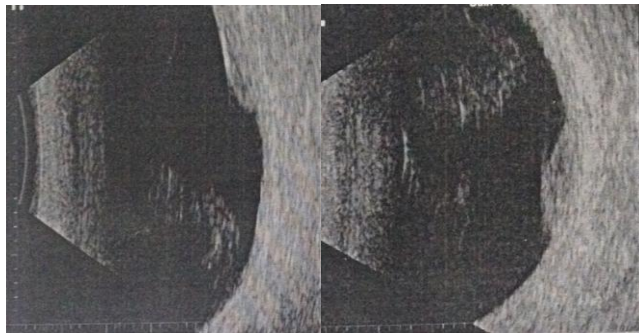
## CASE REPORT

An 81 years old male presented with history of sudden loss of vision in his left eye. He was a known case of diabetes and hypertension. Both conditions were well

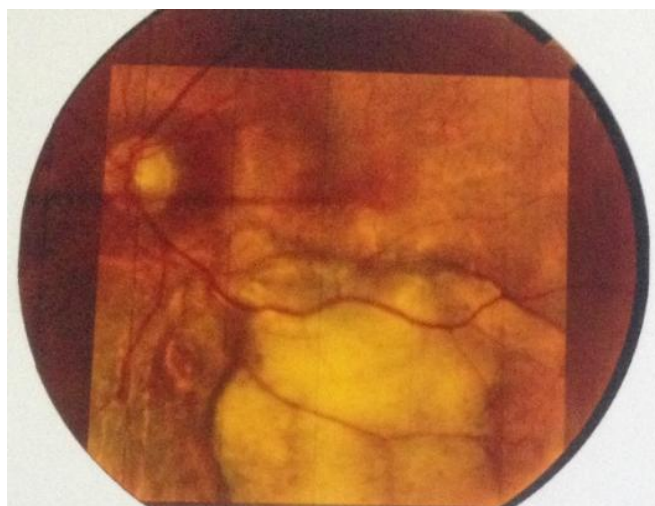
controlled on insulin and antihypertensive agents respectively. He had several injections of intravitreal Avastin in left eye for exudative age related macular degeneration. On examination, there was visual acuity of projection of light in right eye and finger counting in left eye. Intra ocular pressures were normal. Slit lamp examination revealed nuclear sclerosis in right eye and pseudo-phakia in left eye. Fundoscopy showed macular disciform scar in right eye and vitreous hemorrhage in left eye. B-scan of left eye showed moderately dense intra gel hemorrhage with freely mobile fibrotic posterior vitreous detachment. Inferotemporal area showed solid retinal detachment. All other structures were normal. There was medium reflectivity. An acoustic quiet zone at the base of the elevation could be seen. Orbital shadowing was absent (Figures 1-2)

The differential diagnosis in our minds were sub retinal hemorrhage, choroidal melanoma, choroidal metastasis, choroidal osteoma and choroidal hemangioma. Pars plana vitrectomy (PPV) was

performed. A large yellowish white sub-retinal mass, more than 8 disc diameters was seen in the macular area and extending inferior to the inferior temporal vascular arcade (Figure 3).



**Fig. 1 & 2:** B-scan showing Intra gel hemorrhage and solid retinal detachment



**Fig. 3:** Post PPV fundus photograph

Post PPV picture was more like amelanotic melanoma or choroidal Lymphoma. SD-OCT showed normal choroidal contours with no evidence of excavation. Systemic investigations were performed to rule out choroidal metastasis from other organs especially lungs and prostate. Choroidal osteoma was already ruled out on B scan. Owing to the presence of disciform scar in the other eye and history of intra ocular Avastin for AMD in the same eye the patient was followed up for any change in size of the mass. After one month, the mass considerably reduced in height and width. Diagnosis of large sub retinal hemorrhage was made and follow up was continued.

## DISCUSSION

The importance of correct diagnosis of sub retinal mass cannot be overlooked. Certain conditions for example choroidal melanoma requires prompt intervention while some others need either medical therapy (e.g, lymphoma) or just wait and observe strategy (haemangioma and sub retinal hemorrhage). There are cases where choroidal melanoma turns out to be some benign condition usually referred to as pseudo melanomas.

In a study by Shields, about 40 different conditions were described which simulated melanoma. The common ones included suspicious choroidal nevus, disciform degeneration, congenital hypertrophy of the retinal pigment epithelium and choroidal hemangioma. Such a large number of differential diagnosis reflect the clinical problem confronted by ophthalmologist.<sup>1,2</sup>

In the early seventies the percentage of misdiagnosis of choroidal melanoma was as high as 20%. This percentage has fallen considerably with the improvement in diagnostic techniques over the past years. Current diagnosis of choroidal melanoma is based on clinical findings including indirect ophthalmoscopy, A and B scan ultrasonography, and fundus fluorescein angiography. However, invasive procedures like FNAC are not indicated. With clear media, 95% cases are correctly diagnosed by indirect ophthalmoscopy.<sup>3</sup>

The single most important technique to rule out a choroidal melanoma is indirect ophthalmoscopy associated with biomicroscopy of the fundus.<sup>4</sup> According to COMS, accuracy of clinical diagnosis for choroidal melanoma was more than 99% (confirmed by histopathology).<sup>5</sup> But it should be noted that the study excluded patients with cloudy media which could have interfered with the ophthalmoscopic examination, fluorescein angiography and optical coherence tomography.

Another study reported that approximately 30% of patients referred to an ocular oncology service with the diagnosis of choroidal melanoma had an incorrect diagnosis.<sup>6</sup>

Our patient had vitreous hemorrhage that made diagnosis a bit difficult. Gunduz K and colleagues had described a healthy 31 years old man who had loss of vision in right eye. He had yellow white juxta papillary choroidal mass with vitreous hemorrhage. Later on it turned out to be a choroidal granuloma.<sup>7</sup> Another report described unilateral intraschisis

hemorrhage which closely mimicked a choroidal melanoma.<sup>8</sup>

Our patient was found to be a case of exudative AMD. Literature shows that Choroidal nevus is the commonest condition which simulates melanoma. Only 4% patients of pseudomelanoma have AMD.<sup>9</sup>

Amoli FA has described non-Hodgkin lymphoma (NHL) as a masquerade syndrome of choroidal melanoma.<sup>10</sup>

Another differential diagnosis of our patient was circumscribed choroidal hemangioma, which often appears as a subtle red-orange mass or as a grayish lesion in the posterior choroid.<sup>11</sup> The color of lesion in this particular patient and B scan was highly against hemangioma.

Sometimes limited choroidal hemorrhages are mistaken for a choroidal melanoma. Morgan CM described three cases with an unusual localized posterior choroidal hemorrhage. These patients were thought to be cases of choroidal melanomas and were referred for proton beam irradiation. Later, they turned out to be hemorrhagic choroidal detachments.<sup>12</sup>

Contrary to these, there are reports in which presumed benign choroidal lesions later on proved to be choroidal melanoma. Melanomas in the macular region can further jeopardize the diagnosis. They mimic exudative AMD and if left as such, they can be fatal.<sup>13</sup>

In cases where ocular media is clear, SD-OCT provides useful information to observe and document suspicious choroidal lesions and help differentiate choroidal nevus from malignant melanoma. Our patient underwent PPV and SD-OCT showed normal choroid and the lesion was purely sub retinal hemorrhage.<sup>14</sup>

Although clear media is a pre-requisite for SD-OCT, it is very helpful in very small tumours which are not detectable by B scan.<sup>15</sup>

It is not necessary that subretinal hemorrhages should be darker red in color. This particular patient had yellowish white subretinal mass. When hemoglobin undergoes metabolism, there are spectrum of colors seen through this process. It is believed that the greenish hue originates from the retinal nerve fiber layer, which becomes stained by the breakdown products of hemoglobin. There are macrophages, which convert heme into biliverdin (water - soluble green compound) and bilirubin (water insoluble yellow compound).

## CONCLUSION

Even with the advent of new technology, certain cases still prove to be backbreaking and challenging. Ophthalmologists should be vigilant in making a final verdict. Sometimes innocuous lesions turn out to be fatal and conversely, apparently blatant lesions prove benign.

### Author's Affiliation

Dr. Tayyaba Gul Malik  
Associate Professor of Ophthalmology  
Lahore Medical and Dental College  
Email: tayyabam@yahoo.com

Dr. Muhammad Khalil  
Associate Professor of Ophthalmology  
Lahore Medical and Dental College  
Email: mkhalil64pk2002@yahoo.com

Dr. Afzal Hussain  
Eye Consultant  
National Eye Center, Lahore

### Role of Authors

Dr. Tayyaba Gul Malik  
Patient management and manuscript writing.

Dr. Muhammad Khalil  
Patient management and manuscript writing.

Dr. Afzal Hussain  
Patient management and manuscript writing.

## REFERENCES

1. **Shields JA, Augsburger JJ, Brown GC, Stephens RF.** The differential diagnosis of posterior uveal melanoma. *Ophthalmology*. 1980; 87: 518-22.
2. **Shields CL, Manalac J, Das C, Ferguson K, Shields JA.** Choroidal melanoma: clinical features, classification, and top 10 pseudomelanomas. *Curr Opin Ophthalmol*. 2014; 25: 177-85.
3. **Char DH, Stone RD, Irvine AR, Crawford JB, Hilton GF, Lonn LI, et al.** Diagnostic modalities in choroidal melanoma. *Am J Ophthalmol*. 1980; 89: 223-30.
4. **De Laey JJ.** Diagnosis and differential diagnosis of malignant melanomas of the choroid. *Bull Soc Belge Ophthalmol*. 1993; 248: 6-10.
5. The Collaborative Ocular Melanoma Study Group. Accuracy of diagnosis of choroidal melanomas in the Collaborative Ocular Melanoma Study. COMS report no. 1. *Arch Ophthalmol*. 1990; 108: 1268-73.
6. **Khan J, Damato BE.** Accuracy of choroidal melanoma diagnosis by general ophthalmologists: a prospective study. *Eye (Lond)*. 2007; 21: 595-7.

7. **Gündüz K, Shields CL, Shields JA, Schubert H.** Presumed choroidal granuloma with vitreous hemorrhage resembling choroidal melanoma. *Ophthalmic Surg Lasers.* 1998; 29: 422-5.
8. **Hayyam Kıratlı.** Persistent Intrachisis Hemorrhage Simulating Choroidal Melanoma. *Jpn J Ophthalmol.* 2002; 46: 222-5.
9. **Shields JA, Mashayekhi A, Ra S, Shields CL.** Pseudomelanomas of the posterior uveal tract: the 2006 Taylor R. Smith Lecture. *Retina.* 2005; 25: 767-71.
10. **Amoli FA, Rajabi MT, Esfahani MR, Sadeghi A.** Non-Hodgkin lymphoma (NHL) is also one of the masquerade syndromes of malignant melanoma. primary choroidal malignant lymphoma: report of a case and review of literature. *Acta Medica Iranica.* 2006; 44: 145-50.
11. **Khuu T, Hoffman DJ.** Circumscribed choroidal hemangioma: A case report and review of the literature. *Optometry.* 2006; 77: 384-91.
12. **Morgan CM, Gragoudas ES.** Limited choroidal hemorrhage mistaken for a choroidal melanoma. *Ophthalmology.* 1987; 94: 41-6.
13. **Trzaska KA.** Differential diagnosis of exudative age - related macular degeneration with posterior pole choroidal tumours *Klin Oczna.* 2005; 107: 147-55.
14. **Sayanagi K, Pelayes DE, Kaiser PK, Singh AD.** 3D Spectral domain optical coherence tomography findings in choroidal tumors. *Eur J Ophthalmol.* 2011; 21: 271-5.
15. **Torres VL, Brugnoli N, Kaiser PK, Singh AD.** Optical coherence tomography enhanced depth imaging of choroidal tumors. *Am J Ophthalmol.* 2011; 151: 586-93.