

# Orbital Fungal Myositis; A Case Report

Sahar Khalid, Mohammad Moin

*Pak J Ophthalmol 2014, Vol. 30 No. 3*

See end of article for authors affiliations

Correspondence to:  
**Sahar Khalid**  
Eye Unit 2  
Lahore General Hospital  
Lahore

To report a case of 20 years old female presenting with proptosis of the left eye and restricted medial gaze due to medial rectus fungal involvement in an immune competent patient. She underwent removal of the medial rectus followed by muscle transposition surgery few months later with satisfactory outcome.

**Key words:** Orbital myositis, Proptosis, Corneal mucormycosis.

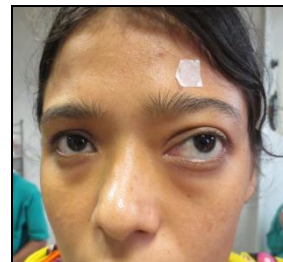Orbital masses can be inflammatory, infectious and neoplastic in origin. In orbital space, they present with overlapping clinical manifestations. The slow growth of a solitary, discrete mass is usually suggestive of tumor. Fungal infections of the orbit are usually seen in immune compromised state<sup>1</sup>. But here, we report a case of orbital fungal granuloma in a young female who was immune-competent and managed satisfactorily.

## CASE REPORT

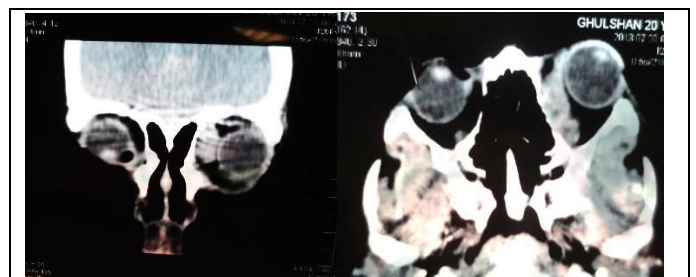A 20 years old unmarried female, presented to our tertiary care hospital with painless progressive non-axial proptosis of the left eye for the last 1 year. She had outward deviation of the left eye with no double vision. She had no visual complaints, no complaints of redness, discharge and photophobia. There was no history of trauma, surgery, systemic illness, lymphadenopathy and nose or throat infection. She had no fever and reported no change in appetite or weight. Past medical and surgical history was unremarkable. She reported no evidence of a disease causing immune suppression. Family history was unremarkable.

On examination, visual acuity was 6/6 unaided in both eyes. There was non-axial proptosis of 23 mm of the left eye on Hertel's exophthalmometer, which increased slightly on Valsalva maneuver. She had an exotropia of 45 degrees on cover test. The dystopia was measured to be 5 mm outwards and 5 mm upwards in the left eye (Fig 1). There was no

complaint of diplopia. Bruit and pulsation were absent. Anterior segment examination was normal.



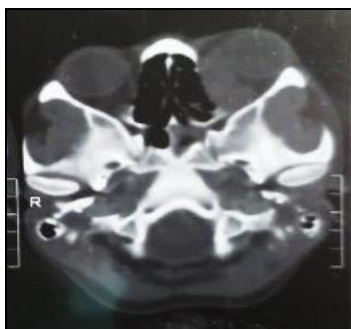
**Fig. 1:** proptosis and exotropia of left eye on initial presentation.



**Fig. 2:** CT scan coronal and axial view showing mass involving medial rectus.

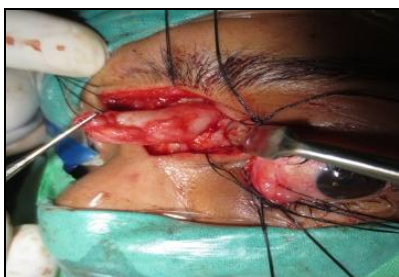Laboratory findings revealed normal blood count, blood glucose level, PT and APTT. Ultrasound abdomen and x-ray chest were of no significance. Computed tomography of orbits and PNS revealed, diffuse thickening of medial rectus (Fig. 2). Rest of the left eye appeared normal. Right eye, nasal cavity and sinuses were within normal limits.

MRI orbit showed thickening of medial rectus muscle and involvement of retrobulbar fat with proptosis of left eye and compression of optic nerve Fig. (3). Brain appeared normal.

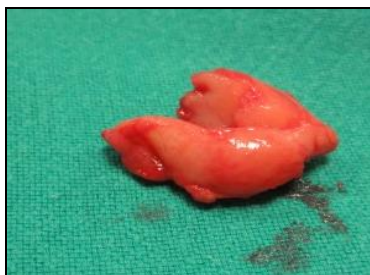

**Fig. 3:** MRI axial view showing the mass invading the medial rectus.

These findings gave the impression of a mass involving the medial rectus. Surgical excision was performed under general anesthesia. Lynch Howarth approach was used. The excised mass which was yellowish in colour unlike the medial rectus on naked eye examination was excised and wound closed with 6/0 vicryl (Fig 4). But the medial rectus tendon was forming the anterior end of the mass which suggested that the muscle had lost its characteristic appearance due to pathological changes. The tendon was identified and separated from the sclera with a muscle hook before excision. Biopsy specimen was sent for histopathology (Fig. 5).

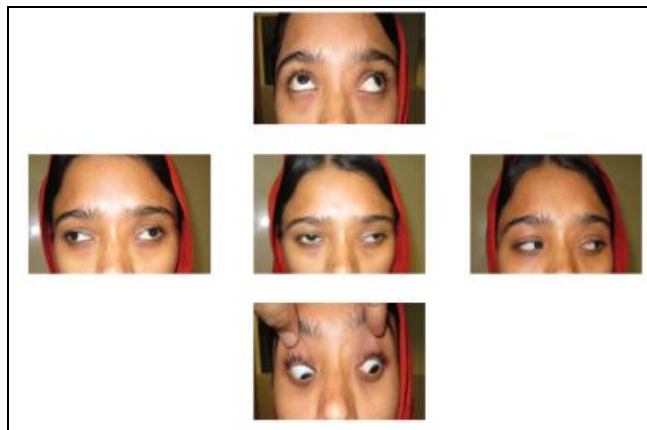


**Fig. 4:** The tumour being removed.



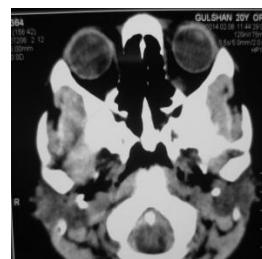**Fig. 5:** Biopsy specimen.

On a follow up examination, 2 weeks after surgery, proptosis was decreased to 20 mm. Optic disc, anterior and posterior segments were within normal limits. Intraocular pressure was 16 mm Hg. Inward eye movements were restricted (grade -4), but normal on superior, inferior and lateral gaze (Fig. 6). There was no diplopia.



**Fig. 6:** Left exotropia with absent abduction at 2 weeks Post op.

Histopathology report showed fibro-connective tissue with granulomatous inflammation. Granulomas were composed of aggregates of epithelioid cells, surrounded by collar of lymphocytes and histiocytes with multiple multinucleated giant cells within the granuloma. Scattered eosinophils were also identified. Few granulomas showed septate hyphae. Histochemical stains were positive for fungal organisms.

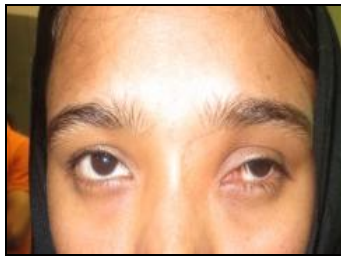

**Fig. 7:** Post op CT showing residual fungal granuloma.

The proptosis decreased after 2 weeks, but there was no movement of left eye on medial gaze, due to absent medial rectus muscle and exotropia of 45 degrees was seen. Post op CT and MRI scans were carried out. They showed residual fungal granuloma (Fig. 7). Patient was prescribed tablet Itraconazole (sporonox) 100 mg twice a day for 3 months. After 3

months, CT and MRI were again carried out, which showed no recurrence of fungal granuloma.

Cosmetic squint correction was done for the large angle exotropia by performing Hummulsheim procedure. In this procedure, there was full tendon transfer of superior and inferior recti to the medial rectus. A Jenson procedure involving split tendon transfer could be done but we opted for full tendon transfer due to the very large angle exotropia. Lateral rectus recession was not feasible due to the absence of medial rectus which would pull it medially after surgery. Post-op examination after 4 weeks showed improvement of exotropia on primary position to 30 degrees (Fig. 8).



**Fig. 8:** Residual small angle exotropia of left eye at 4 weeks post op.

## DISCUSSION

In adults, primary orbital tumors are lymphoid tumors, cavernous hemangioma, meningioma, neurofibroma and schwannoma. Most common presentations are proptosis and exophthalmos. Infectious and inflammatory process has acute onset as compared to tumors, which has slow onset. In the presented case fungal granuloma developed in an immune competent patient over a period of 1 year with no acute symptoms except proptosis.

Orbital infections occur due to spread of infections from paranasal sinuses or direct from trauma and surgery. Most common organisms are bacteria, while viral and fungal infections are rare. Organisms causing fungal infections include aspergillus. Mucormycosis and Cryptococcus species<sup>2</sup>. Aspergillus granuloma is the most commonly reported intracranial granuloma among fungal granulomas<sup>3</sup>. It is the common causative fungal organism of intracranial fungal mass lesion accounting for approximately 56% to 69%<sup>3</sup>. The estimated annual incidences of systemic invasive fungal infections caused by Aspergillus species are 12-34%<sup>4</sup>. The estimated incidence of fungal infection is 4-6% of CNS involvement<sup>5</sup>. Fungal infections commonly

occur in immune compromised state like diabetes mellitus (37%)<sup>6</sup>, AIDS or excessive steroid use. The common sites of involvement are nasal cavity (10%), brain with sinonasal (36.6%) and nose and orbital cavity (53.3%)<sup>7</sup>. Some of the reports shows that the fungal infections can present as optic neuritis<sup>8</sup>. It can present in the form of sub periosteal abscess<sup>9</sup>. Optic neuropathy<sup>8</sup>, orbital apex syndrome<sup>10</sup> and orbital tuberculosis with coexisting fungal granulomas<sup>11</sup>.

To assess the orbital disease, MRI imaging is preferable because it gives full detail of the soft tissue structures. The MRI findings are characteristics in fungal granuloma. These include a mass lesion producing hypo-intense or iso-intense lesion on T<sub>1</sub> weighted and hypo intense lesion on T<sub>2</sub> weighted images<sup>12</sup>.

In our case, MRI findings of fungal granuloma on T<sub>1</sub> weighted images were iso-intense while they were hypointense on T<sub>2</sub> weighted images, which in literature are characteristic of aspergillus fungal granuloma. Its non-tender and non-inflammatory nature caused it to be misdiagnosed as tumor. So, fungal infections should always be kept in differentials of such solitary orbital masses.

Surgery is important both for initial diagnosis and for excision of granuloma, allowing for a better treatment efficacy of systemic antifungal agents like Amphotericin B and Itraconazole 100-400 mg twice a day for 3 months.

## CONCLUSION

Orbital fungal granuloma may affect immune competent healthy patients as well as immune compromised patients. Main stays of treatment are surgical debridement and systemic antifungal therapy. Early diagnosis can prevent the extensive surgical intervention.

### Author's Affiliation

Dr. Saher Khalid  
PGR Eye Unit 2  
lahore General Hospital  
Lahore

Dr. Mohammad Moin  
Professor Ophthalmology  
Eye Unit 2  
Lahore General Hospital  
Lahore

## REFERENCES

1. **Zafar MA, Waheed SS, Enam SA.** Orbital aspergillus infection mimicking a tumor: a case report. *Cases journal.* 2009; 2: 7860.
2. **Hershay BL, Roth TC.** Orbital infections. *Semin ultrasound CT MR* 1997; 18: 448-59.
3. **Sundram C, Umabala P.** Pathology of fungal infections of central nervous system: 17 years experience from Southern India. *Histopathology.* 2006; 49: 396-405.
4. **Pfaller MA, Pappas PG.** Invasive fungal pathogens, current epidemiological trends. *Clinical infectious disease.* 2006; 43: 3-14.
5. **Kethireddy S, Andes D.** CNS pharmacokinetics of antifungal agents. *Expert Opinion on Drug Metabolism and Toxicology.* 2007; 3: 573-81.
6. **Finn DG.** Mucormycosis of paranasal sinuses. *Ear Nose Throat J.* 1998; 67: 813-16.
7. **Javadi M.** Fungal infection of the sinus and anterior skull base. *Med J Islam Repub Iran.* 2008; 22: 137-40.
8. **Mafee MF, Goodim J.** optic nerve sheath meningiomas. *RadiolClin North Am.* 1999; 37: 37-58.
9. **Spoor TC, Hartel WC.** Aspergillosis presenting as a corticosteroid responsive optic neuropathy. *J Clin Neuroophthalmol.* 1982; 2: 103-7.
10. **Matsou T, Notohara K.** aspergillosis causing bilateral optic neuritis and later orbital apex syndrome. *Jpn J Ophthalmol.* 2005; 49: 430-1.
11. **Reddy SS, Penmmaiah DC.** Orbital tuberculosis with coexisting fungal infection. *Surg NeurolInt.* 2014; 5: 32.
12. **Siddiqui AA, Bashir SH.** Diagnostic MR imaging features of craniocerebralaspergillosis of sino nasal origin in immune competent patients. *Acta Neurochir.* 2006; 148: 155-66.