

Role of Oral Rifampicin in Chronic Central Serous Chorioretinopathy

P.S. Mahar, Nasir Memon, A. Sami Memon, M. Faisal Faheem

Pak J Ophthalmol 2018, Vol. 34, No. 1

See end of article for authors affiliations

Correspondence to:
Prof. P.S Mahar
Isra Postgraduate Institute of Ophthalmology
Karachi, Pakistan
E-mail: salim.mahar@aku.edu

Purpose: To determine the improvement in visual acuity and central macular thickness in patients with chronic central serous chorioretinopathy (CSCR) with oral Rifampicin.

Study Design: Quasi experimental study.

Place and Duration of Study: Isra Postgraduate Institute of Ophthalmology, Al-Ibrahim Eye Hospital, Karachi. From September 2015 to December 2016.

Material & Methods: Ten eyes of 10 patients having chronic CSCR of more than 6 months duration were prospectively treated with oral Rifampicin 450 mg in single oral dose for 3 months duration. All patients were followed-up for 12 months.

Results: Ten eyes of 10 patients were included in the study. The gender distribution showed 8 male (80%) and 2 female (20%) patients. There were five right and five left eyes. Mean age of our patients was 40.10 ± 5.1 years (Range 34 – 46 years). Mean duration of patient's ocular symptoms was 9.4 ± 2.9 months with range of 6 – 14 months. Patient's visual acuity improved at 3 months follow-up. Mean Pre-treatment central macular thickness was 350 ± 82.3 μ m improving to 232 ± 54.3 μ m at 3 months treatment.

Conclusion: All patients with chronic CSCR of more than 6 months duration showed improvement in their vision and central macular thickness with oral Rifampicin taken for 3 months.

Key Words: Rifampicin, Central serous chorioretinopathy, Visual acuity, Central macular thickness.

Central serous chorioretinopathy (CSCR) is characterized by elevation of neuro sensory retina at the posterior pole. In majority of the cases, the cause remains unknown so the condition is termed as idiopathic. CSCR is a self-limiting disease with spontaneous resolution occurring within 3 – 4 months of initial episode resulting in good visual outcome¹. Observation alone is therefore advised as the first line approach in the newly diagnosed cases. However, risks factors such as increase stress score, raised homocysteine and serum cortisol level and elevated systolic blood pressure should be addressed². Unfortunately, recurrences are seen in up to 50% of patients within the first year. In 10 – 20% of cases, patients can have persistent serous retinal detachment

with progressive decreased vision³.

The exact mechanism of the disease is not known. Gass suggested that an increase in the choriocapillaris permeability was the primary cause of damage to the overlying retinal pigment epithelium (RPE), resulting in accumulation of fluid under the neuro sensory retina⁴. This theory has been recently supported by choroidal vessel staining on indo-cyanine green (ICG) angiography and appearance of thickened choroid on swept source optical coherence tomography (OCT)⁵.

CSCR has been associated with intake of steroids and also described in patients with Cushing disease, pregnancy and stress with endogenous high level of cortisol secretion⁶. As glucocorticoids are implicated in

the pathogenesis of CSCR, their inhibition has been suggested as a potential treatment modality.

There are several options of treatment described in patients when sub-retinal fluid persists beyond 3 months and condition takes a chronic course with progressive decrease in vision. The ICG - guided photodynamic therapy with verteporfen was described by Yannuzzi in patients with chronic CSCR with favorable results⁷. Intravitreal anti - vascular endothelial growth factor (VEGF) such as bevacizumab⁸ and systemic pharmacologic therapy affecting glucocorticoid metabolism has also been described in chronic CSCR⁹.

Rifampicin is an anti-tuberculous drug and is known to induce cytochrome P450 3A4 to alter the metabolism of endogenous steroids with an improvement in clinical features of CSCR¹⁰.

Although the first report of use of Rifampicin in chronic CSCR is attributed to Ravage and Packo¹¹ for their presentation during American society of retinal specialist meeting in 2010, the first reported case in literature is described by Steinle and colleagues published in British Journal of Ophthalmology (BJO) in 2011¹².

We carried out a prospective study to evaluate the efficacy of oral Rifampicin (Rimactal - Sandoz Pakistan) in patients with chronic CSCR who had persistent sub-retinal fluid (SRF) for more than 6 months of initial presentation with diminished vision. The primary outcome measure in our study was decrease in SRF documented on OCT and secondary outcome was an increase in the Snellen's visual acuity after the treatment with Rifampicin for 3 months.

MATERIALS & METHODS

We prospectively treated 10 eyes of 10 patients having chronic CSCR of more than 6 months duration with oral Rifampicin 450 mg in a single oral dose for 3 months. All patients were followed up for 12 months duration.

This was quasi experimental study with non-probability convenience sampling. The study was conducted at Isra Postgraduate Institute of Ophthalmology, Karachi from September, 2015 till December 2016. The study was approved by the Research Ethical Committee of the Institute (Protocol No. A-00044).

All patients gave consent for taking Rifampicin orally. The study patients had detailed history of

visual symptoms with any other significant medical or surgical history with intake of any oral medication. The ocular examination included best corrected visual acuity (BCVA) on Snellen's chart, bio-microscopic examination of anterior segments with intraocular pressure (IOP) measurement. Every patient underwent dilated fundus examination with + 90 Diopter lens and subsequently OCT scan of macula (Topcon - Japan). In some cases fundus fluorescein angiography (FFA) was also obtained. Once patient was initiated on oral Rifampicin therapy, ocular examination was repeated at each monthly visit with recording of BCVA. At monthly follow up, OCT scan was also repeated to demonstrate any change in the presence of SRF with decrease in central macular thickness (CMT).

All patients with confirmed diagnosis of CSCR on clinical examination confirmed with OCT scan with age limit of 20 - 50 years were included in the study. Any patient having oral acetazolamide, methotrexate or history of intravitreal injection of Bevacizumab in last 3 months was excluded. Patients taking topical non-steroidal anti-inflammatory drugs and topical carbonic anhydrase inhibitors were also excluded from the study.

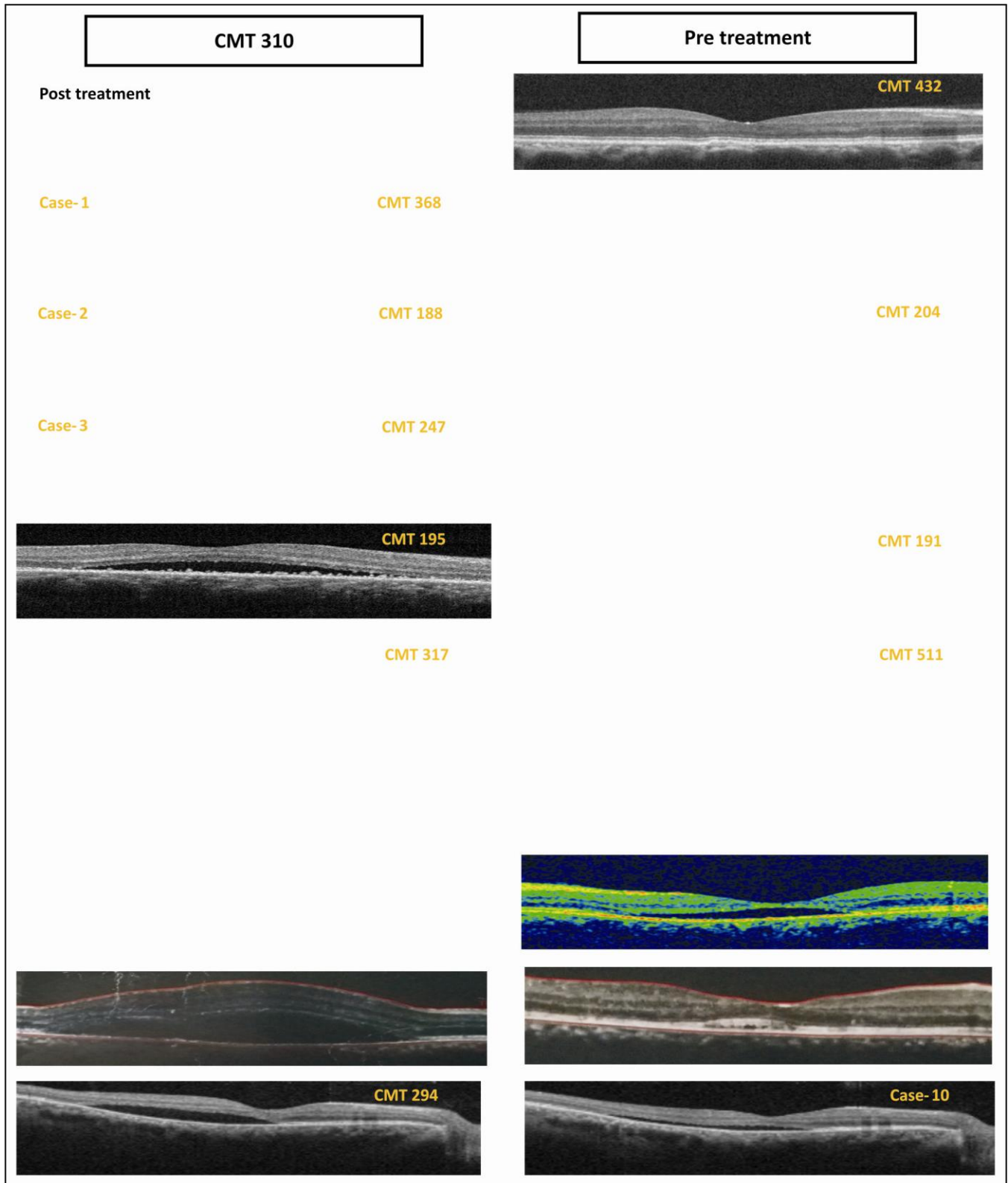
Before the start of the treatment liver function tests (LFTs) and complete blood count (CBC) of all patients was worked up. These tests were repeated every month while patient was taking oral Rifampicin. Rifampicin was discontinued after 3 months of treatment.

Statistical Analysis

Data analysis was done through the software SPSS version 20.0. All the continuous variables were presented in Mean and Standard Deviation. The entire categorical variables were shown in frequency and percentages. Paired sample t test was used to find the significance between pre and post CMT and Chi square test was used for categorical variable like Visual Acuity. P value ≤ 0.05 was considered to be statistically significant.

RESULTS

Ten eyes of 10 patients were included in the study. The gender distribution showed 8 males (80%) and 2 females (20%). there were five left and five right eyes. Mean age was 40.10 ± 5.1 years (Range 34 - 46 years). Mean duration of patient's ocular symptoms was 9.4 ± 2.9 months with range of 6 - 14 Months (Table 1).



OCT= Optical coherence tomography
 CMT= Central macular thickness (microns)

Table 1: Demographic Characteristics of Patients.

The enrolled patients were commenced on oral Rifampicin (450 mg) half an hour before the breakfast. Patient's visual acuity improved at 3 months follow-up (Figure 1).

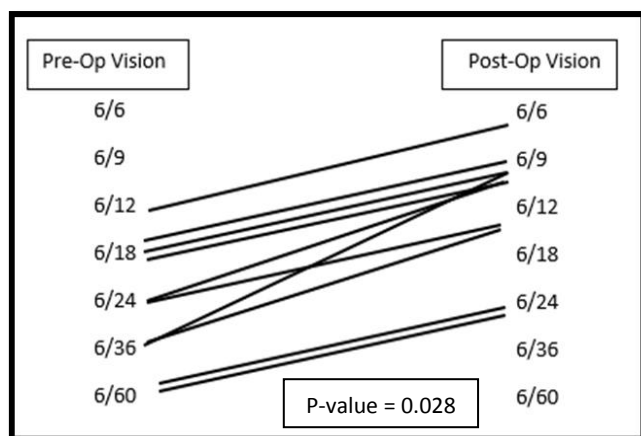
Mean pre-treatment central macular thickness (CMT) was $350 \pm 82.3 \mu\text{m}$ improving to $232 \pm 54.3 \mu\text{m}$ at 3 months treatment (Figure 2).

All patients' OCT scans showing CMT are given in figure A. These patients were followed upto 12 months and showed stable vision.

The drug was very well tolerated by all the patients for 3 months duration and improvements in visual acuity and CMT were sustained till 12 months follow-up.

Age, Years	40.10 ± 5.1
Age Range, Years`	32 - 46
Gender	
Male	8 (80%)
Female	2 (20%)
Affected eye	
Right	5 (50%)
Left	5 (50%)
Duration of symptoms (months)	9.4 ± 2.9

*Data presented in Mean± SD & frequency (%)



*Chi-Square test was applied to see the significance
*P-value ≤ 0.05 considered to be statistically significant

Fig. 1: Comparison of Visual Acuity.

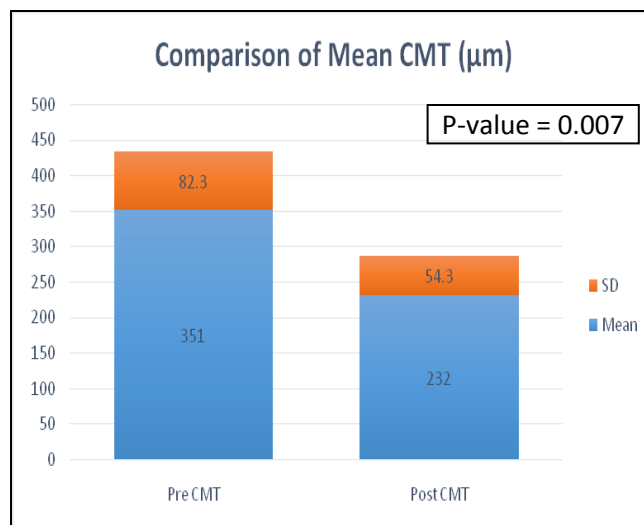


Fig. 2: Comparison of Mean Central Macular Thickness (CMT).

DISCUSSION

Chronic CSCR can be a debilitating disease with decrease in visual acuity due to persistent presence of fluid in the sub-retinal space and wide spread RPE atrophy. It is associated with higher recurrence rate and potentially poor visual prognosis. There are multiple options described in the literature to treat chronic CSCR. This includes reduced fluence PDT with verteporfin¹³, transpupillary thermotherapy¹⁴, intravitreal ranibizumab¹⁵ and micro-pulse diode laser photocoagulation¹⁶.

Jampol and colleagues first suggested that glucocorticosteroids antagonist may be of value in treating repeated episodes of CSCR. This was based on the association of endogenous hypercortisolism with the development of CSCR¹⁷.

The exact role of glucocorticoids in pathogenesis of CSCR is not known but possible mechanism include increased capillary fragility and hyper permeability leading to choroidal circulation decompensation with leakage of fluid in the sub-retinal space¹⁸.

Rifampicin is an anti-tuberculous drug with primary action of inducing cytochrome P450 3A4 which catalyzes the drug metabolism and synthesis of cholesterol, steroids and lipids¹⁹. It is therefore suggested that induction of cytochrome P450 3A4 increases the metabolism of endogenous steroids resulting in improvement of CSCR features with resolution of sub-retinal fluid.

We prospectively treated 10 eyes of 10 patients

with the diagnosis of chronic CSCR showing sub-retinal fluid on OCT scan of more than 6 months duration. All these patients had oral Rifampicin 450 mg in single dosage taken for 3 months. As the drug can be hepatotoxic so all our patients had LFTs done at baseline and repeated every month till cessation of drug. As all patients had visual complaints of long duration with presence of SRF we feel that the resolution of patient's symptoms with decrease in SRF and CMT were induced by Rifampicin.

It is important to take previous drug intake history of patients before commencing them on Rifampicin as it can cause multiple drug interactions with anti-coagulants, anti-convulsants, anti-arrhythmics, anti-fungal, beta blockers, calcium channel blockers, steroids and certain antibiotics²⁰.

Nattis and Josephberg has described 3 cases of chronic CSCR with patients having blurred vision over past couple of years. All cases showed improvement in their visual acuity and amount of SRF present on OCT²¹. Biggest series of Rifampicin treated patients has come from Israel by Shulman and colleagues where 14 eyes of 12 patients had been treated with oral Rifampicin in dose of 600 mg/day for 4 months²². Choudhury and co-workers²³ treated 13 patients with chronic CSCR, though the duration of patient's symptoms was merely 6 weeks old. Ten of their patients showed improvement in vision with decrease in CMT after getting treatment with Rifampicin 600 mg in single dose for 4 weeks. It is not clear from their work that for how long these patients were followed. Khan et al²⁴ found that central macular thickness was reduced from 494 ± 96 μ m to 306 ± 50 μ m after 4 weeks of treatment with 300 mg Rifampicin daily.

The optimal dosage and duration of Rifampicin in treating chronic CSCR is not known. Our patients received 450 mg/day for 3 months with remarkable improvement in their clinical features. Our work differ from other studies that we only treated those patients who has CSCR with visual symptoms of more than 6 months duration and were followed-up for 12 months.

As the drug is hepatotoxic and can cause interaction with other drug, proper medical history and LFTs at baseline and follow up are mandatory.

Although CSCR is self-limiting disease but persistence of symptoms with presence of SRF beyond 3 - 4 months warrants treatment.

Photodynamic therapy (PDT) with verteporfin with reduced fluence and half exposure time is suggested as the first line treatment. However, this can

be associated with pigmentary changes, RPE atrophy, RPE tear, choroidal ischemia and secondary choroidal neovascularization²⁵. Focal argon laser therapy is another option when leakage occurs outside foveal avascular zone. But these cases can also be complicated by secondary choroidal neovascularization.

Rifampicin appears promising, cost-effective and efficacious mode of treatment in chronic CSCR. It will be interesting also to explore its value in acute cases where prompt visual recovery is required in patients such as in pilots and doctors.

CONCLUSION

In this study all patients with chronic CSCR of more than 6 months duration showed improvement in their visual acuity and corresponding decrease in central macular thickness on OCT, when treated with oral Rifampicin 450 mg in single dose for 3 months period.

Author's Affiliation

Dr. PS Mahar
FRCS, DO, FRCOphth
Professor & Dean,
Isra Postgraduate Institute of Ophthalmology,
Karachi.

Dr. Nasir Memon
FCPS, Senior Registrar
Isra Postgraduate Institute of Ophthalmology,
Karachi.

Dr. A. Sami Memon
MD, FCPS, Assistant Professor
Isra Postgraduate Institute of Ophthalmology,
Karachi.

Mr. M. Faisal Faheem
MSc (Statistics), Statistician
Isra Postgraduate Institute of Ophthalmology
Karachi.

Role of Authors

Dr. PS Mahar
Writing the manuscript.

Nasir Memon
Collection of data.

A. Sami Memon
Collection of data.

M. Faisal Faheem
Statistical Analysis.

REFERENCES

1. **Marmor MF.** New hypotheses on the pathogenesis and treatment of serous retinal detachment. *Graefes Arch Clin Exp Ophthalmol.* 1988; 226: 548-52.
2. **Agarwal A, Garg M, Dixit N, Godara R.** Evaluation and correlation of stress scores with blood pressure, endogenous cortisol levels, and homocysteine levels in patients with central serous chorioretinopathy and comparison with age-matched controls. *Indian J Ophthalmol.* 2016; 64: 803-5.
3. **Spaide RF, Goldbaum M, Wong DWK, et al.** Serous detachment of the retina. *Retina.* 2003; 23: 820-46.
4. **Gass JDM.** Pathogenesis of disciform detachment of the neuroepithelium: V. Disciform macular detachment secondary to focal choroiditis. *Am J Ophthalmol.* 1967; 63: 661-87.
5. **Spaide RF, Koizumi H, Pozzoni MC.** Enhanced depth imaging spectral-domain optical coherence tomography. *Am J Ophthalmol.* 2008; 146: 496-500.
6. **Sharma T, Shah N, Rao M, et al.** Visual outcome after discontinuation of corticosteroids in atypical severe central serous chorioretinopathy. *Ophthalmology,* 2004; 111: 1708-14.
7. **Yannuzzi LA.** Chronic central serous and fundus autofluorescence. *Retinal Cases and Brief Reports,* 2008; 2: 1-5.
8. **Huang WC, Chen WL, Tsai YY, Chiang CC, Lin JM.** Intravitreal bevacizumab for treatment of chronic central serous chorioretinopathy. *Eye,* 2009; 23 (2): 488-9.
9. **Meyerle CB, Freund KB, Bhatnagar P, Shah V, Yannuzzi LA et al.** Ketoconazole in the treatment of chronic idiopathic central serous chorioretinopathy. *Retina,* 2007; 27: 943-6.
10. **Wang M, Munch IC, Hasler PW et al.** Central serous chorioretinopathy. *Acta Ophthalmol.* 2008; 86: 126-45.
11. **Ravage Z, Packo K.** Rifampicin for treatment of central serous chorioretinopathy. *Invest Ophthalmol Vis Sci.* 2011; 52: ARVO E-Abstract 2137.
12. **Steinle N, Gupta N, Yuan A, Singh R.** Oral rifampicin utilization for the treatment of chronic multifocal central serous retinopathy. *Br J Ophthalmol.* 2011; 96: 10-3.
13. **Shin JY, Woo SJ, Yu SG, et al.** Comparison of efficacy and safety between half-fluence and full-fluence photodynamic therapy for chronic central serous chorioretinopathy. *Retina.* 2011; 31: 119-26.
14. **Shukla D, Kolluru C, Vignesh TP et al.** Transpupillary thermotherapy for subfoveal leaks in central serous chorioretinopathy. *Eye,* 2006; 22: 100-6.
15. **Bae SH, Heo JW, Kim C, et al.** Randomized pilot study of low-fluence photodynamic therapy versus intravitreal ranibizumab for chronic central serous chorioretinopathy. *Am J Ophthalmol.* 2011; 152: 784-92.
16. **Sivaprasad S, Elagonz M, McHugh D, et al.** Micropulsed diode laser therapy: evolution and clinical applications. *Surv Ophthalmol.* 2010; 55: 516-30.
17. **Jampol LM, Weinreb R, Yannuzzi LA.** Involvement of corticosteroids and catecholamines in the pathogenesis of central serous chorioretinopathy: a rationale for new treatment strategies. *Ophthalmology,* 2002; 109: 1765-6.
18. **Garg SP, Dada T, Talwar D, et al.** Endogenous cortisol profile in patients with central serous chorioretinopathy. *Br J Ophthalmol.* 1997; 81: 962-4.
19. **Guengerich FP.** Cytochrome P-450 3A4: regulation and role in drug metabolism. *Annu Rev Pharmacol Toxicol.* 1999; 39: 1-17.
20. **Finch CK, Chrisman CR, Baciewicz AM, Self TH.** Rifampicin and rifabutin drug interactions: an update. *Arch Intern Med.* 2002; 162 (9): 985-92.
21. **Nattis A, Josephberg R.** Rifampin as an efficacious therapy for chronic CSC. *Retinal Physician,* 2015; 12: 52-7.
22. **Shulman S, Goldenberg D, Schwartz R, Habot-Wilner Z, Barak A, Ehrlich N, Loewenstein A, Goldstein M.** Oral Rifampin treatment for longstanding chronic central serous chorioretinopathy. *Graefes Archive for Clinical and Experimental Ophthalmology.* 2016; 254(1):15-22.
23. **Choudhury D, Sharma P, Dora J.** Role of Rifampicin and Ketoconazole in Chronic Central Serous Chorioretinopathy & 58; a Comparative Study. *Journal of Evidence Based Medicine and Healthcare,* 2016; 3 (72): 3940-4.
24. **Khan MS, Sameen M, Lodhi AA, Ahmed M, Ahmed N, Kamal M, Junejo SA.** Effect of half adult dose of oral Rifampicin (300mg) in patients with idiopathic central serous chorioretinopathy. *Pakistan journal of medical sciences.* 2016 Sep;32(5):1158.
25. **Kim SW, Oh J, Oh IK, Huh K.** Retinal pigment epithelial tear after half fluence PDT for serous pigment epithelial detachment in central serous chorioretinopathy. *Ophthalmic Surg Lasers Imaging,* 2009; 40: 300-303.