

# Pattern of Central Serous Chorioretinopathy (CSCR) on Fundus Fluorescein Angiography

Shahid Jamal Siddiqui, Syed Imtiaz Ali Shah, Muhammad Afzal Pechuho , Safdar Ali Abbasi, Fouzia Fateh Shaikh.

*Pak J Ophthalmol 2008, Vol. 24 No. 4*

.....  
See end of article for  
authors affiliations

**Purpose:** To study the pattern of central serous chorioretinopathy (CSCR) on fundus fluorescein angiography (FFA).

.....  
Correspondence to:  
Shahid Jamal Siddiqui  
Associate Professor of  
Ophthalmology  
Banglow # 05 Type II  
CMC Staff Colony  
Larkana

**Material and Methods:** The hospital based descriptive study of 30 patients was conducted at the Department of Ophthalmology Chandka Medical College and Hospital Larkana, from December 2003 to February 2008. The patients were selected from the retina clinic. After history and complete ocular examination the clinical diagnosis of CSCR was established. The fundus photographs and fluorescein angiography was done in all the 30 patients. Before injecting fluorescein, test dose was given and pupils were dilated with tropicamide 1% and phenylephrine 10%. Injection fluorescein sodium 25% 3ml i.e 250 mg/ml was given intravenously and multiple photographs were taken by the digital fundus camera. The patterns of CSCR on fundus fluorescein angiography were observed and notified.

**Results:** In this hospital based descriptive study of 30 patients of CSCR 27 were male (90%) and 03 were female (10%). The patients between 20-55 years of age were presented, with a mean age of 35.4 years. 26 patients had unilateral and 04 with bilateral disease. Number of eyes was 34. All patients presented with blurred vision, positive relative central scotoma and dome shaped elevation at the macula. The duration of visual disturbances on presentation was three days to three months. On fundus fluorescein angiography of 30 patients hyper-

fluorescence with ink-blot appearance was seen in 23 eyes (67.64%) and smoke-stack appearance in 11 eyes (30.35%).

**Conclusion:** Ink-blot pattern is more frequently seen in CSCR on fundus fluorescein angiography.

Received for publication

May' 2008

.....

**C**entral Serous Chorioretinopathy (CSCR) is characterized by idiopathic serous detachment of the sensory retina<sup>1</sup>. It is an exudative macular disease that predominantly affects young to middle aged men. The characteristic neurosensory detachment on the posterior pole is caused by leakage of fluid seen at the level of retinal pigment epithelium<sup>2</sup>. Several theories have explained the mechanism and pathogenesis of CSCR. In all of these theories increased choroidal vascular permeability is supposed to be the reason for the serous detachment of the retinal pigment epithelium (RPE)<sup>1,3-5</sup>.

The fundus fluorescein angiography (FFA) findings are very important in the diagnosis of CSCR. In CSCR, there is a breakdown of the outer blood retinal barrier which allows the passage of free fluorescein molecules into the subretinal space<sup>6</sup>. Various patterns of dye leakage are seen the most common are smoke-stack and ink-blot<sup>5</sup>. The unusual forms are inverse smoke-stack, diffuse RPE leakage (ooze), RPE atrophic tracts<sup>1,7</sup>. The objective of this study was to identify and see the various patterns of CSCR on FFA.

#### MATERIAL AND METHODS

The hospital based descriptive study of 30 patients was conducted at the Department of Ophthalmology Chandka Medical College and Hospital Larkana. The patients were selected from the retina clinic. After history and complete ocular examination the clinical diagnosis of CSCR was established. The fundus photographs and fluorescein angiography was done in all the 30 patients. A test dose of fluorescein was given and pupils were dilated with topical 1% and phenylephrine 10%. Injection fluorescein sodium 25% 3ml i.e 250 mg/ml was given intravenously and multiple photographs were taken by the digital fundus camera. The patterns of CSCR on fundus fluorescein angiography were observed and recorded.

#### RESULTS

In this hospital based descriptive study of 30 patients of CSCR 27 were male (90%) and 03 female (10%). The patients presented were between 20-55 years of age, with a median age of 35.4 years. Twenty six (86.66%) patients had unilateral and 04 (13.33%) were with bilateral disease (Table-1). Number of eyes was 34. All patients presented with blurred vision, positive relative central scotoma and dome shaped elevation at the macula (Figures 1-A, 2-A, 3A). The duration of visual disturbances on presentation was three days to three months. On fundus fluorescein angiography of 30 patients, hyper-fluorescence with ink-blot appearance was seen in 23 eyes (67.64%) (Figure 1-B) and smoke-stack appearance in 11 eyes (30.35%) (Table-2 and Figures 2-B and 2-C).

#### DISCUSSION

Fundus fluorescein angiography (FFA) plays a crucial role in the understanding of different disease processes affecting the eye. A good knowledge of the changes occurring in the fluorescein angiogram is important for correct diagnosis and management of eye disorders.

**Table 1:** Patients Data

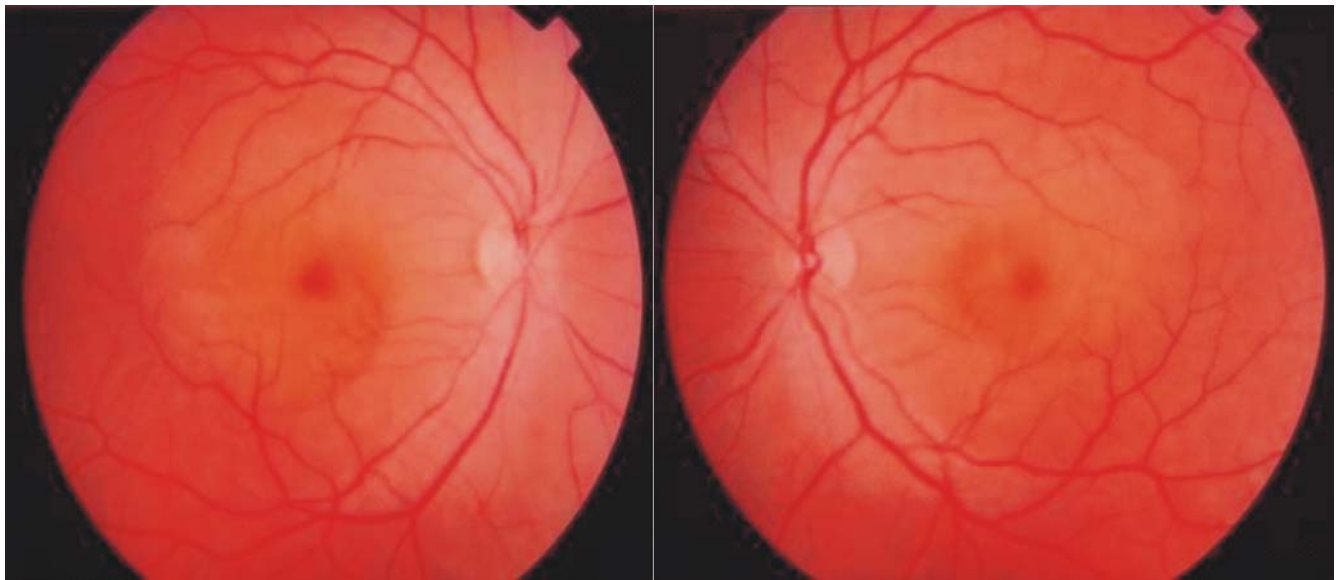
Total Number of Patients	30
Male	27 (90%)
Female	03 (10%)
Age (Range)	20-55 years
Mean Age	35.4 years

Unilateral	26 (86.66%)
Bilateral	04 (13.33%)

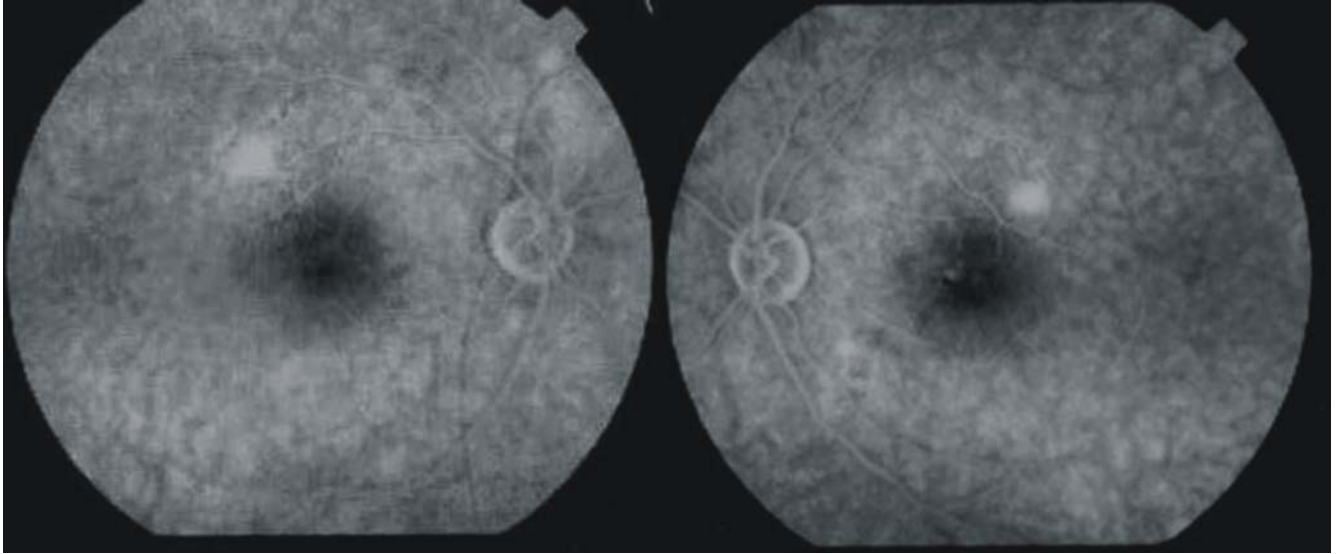
**Table 2:** Patterns of CSCR on FFA

Fluorescein pattern	Number of Eyes (34) n(%)
Ink-blot	23 (67.64)
Smoke-stack	11(32.35)

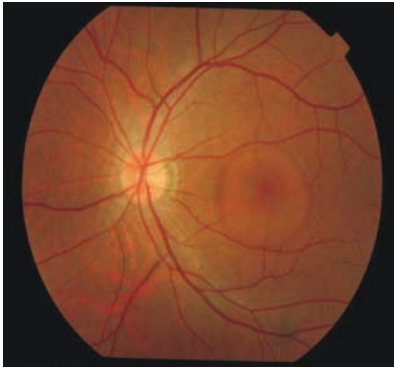Our study of 30 cases of rural Sindh population demonstrates that CSCR is more common in males (90%) than females (10%). The patients between 20 – 55 years of age (mean age 35.4 years) were presented Cynthia and colleagues have reported mean age of 55 years (range 35 – 78 years) in their study<sup>8</sup>. Fundus fluorescein angiography (FFA) in 23 eyes (67.64%) revealed ink-blot appearance and in 11 eyes (32.35%) smoke-stack appearance in our study of 34 eyes with CSCR, which demonstrate that ink-blot appearance is more frequent than smoke-stack appearance. Kanski<sup>6</sup> has reported that smoke-stack appearance is more common than ink-blot, whereas other studies by Baig, Peykan and their colleagues have reported ink-blot appearance more commonly seen in CSCR on FFA than smoke-stack appearance<sup>1,9</sup>.



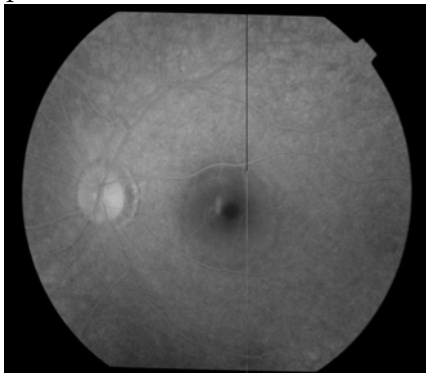
**Fig. 1-A:** Fundus Photographs showing bilateral CSCR.



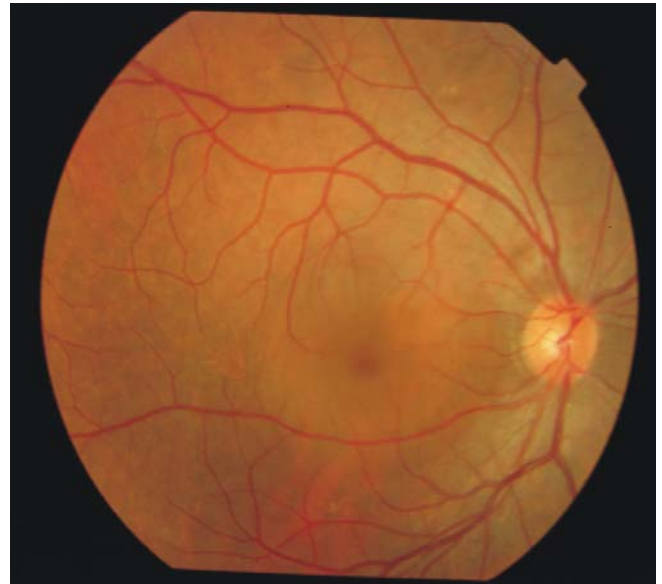
**Fig. 1-B:** Fundus fluorescein angiogram shows ink-blot appearance in bilateral CSCR.



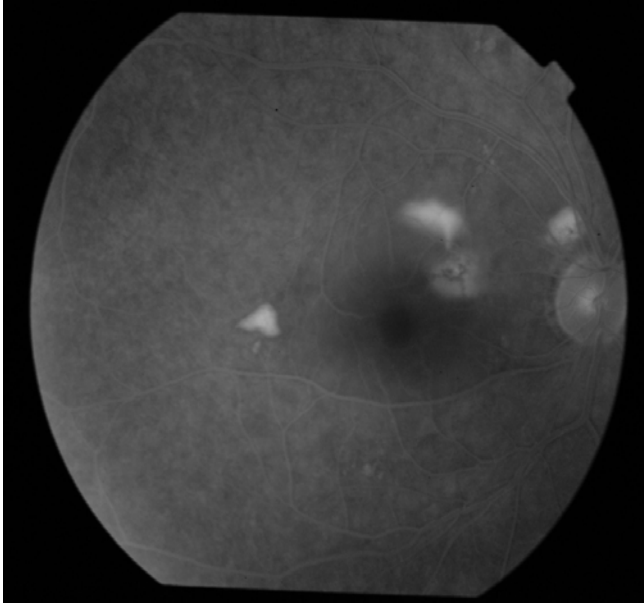
**Fig. 2-A:** Fundus photograph of left eye showing dome shaped elevation at the macula.



**Fig. 2-B:** Fundus fluorescein angiogram of left eye showing smoke-stack appearance.



**Fig. 3-A:** Fundus photograph of right eye showing dome shaped elevation at the macula.



**Fig. 3-B:** Fundus fluorescein angiogram of right eye showing smoke-stack appearance.

**Author's affiliation**

Dr: Shahid Jamal Siddiqui  
 Associate Professor  
 Department of Ophthalmology  
 Chandka Medical College & Hospital  
 Larkana Sindh.

Prof: Syed Imtiaz Ali Shah  
 Professor & Head  
 Department of Ophthalmology  
 Chandka Medical College & Hospital  
 Larkana Sindh.

Dr. Muhammad afzal pechuho  
 Assistant Professor  
 Department of Ophthalmology  
 Chandka Medical College & Hospital  
 Larkana Sindh.

Dr. Safdar Ali Abbasi  
 Department of Ophthalmology  
 Chandka Medical College & Hospital  
 Larkana Sindh.

Dr. Fouzia Fateh Shaikh  
 Department of Ophthalmology  
 Chandka Medical College & Hospital  
 Larkana Sindh.

**REFERENCE**

1. **Peykan T, Turgut Y, Burak T, et al.** Unusual Fundus Fluorescein Angiography findings in Central Serous Chorioretinopathy. *J of Retina - Vitreous.* 2007; 15: 223-5.
2. **Michael T, Elzbeita P, Karl K, et al.** Topical Fundus Pulsation measurement in patients with active Central Serous Chorioretinopathy. *Arch Ophthalmol.* 2003; 121: 975-8.
3. **Guyer DR, Yannuzzi LA, Slakter JS, et al.** Digital indocyanine green video angiography of Central Serous Chorioretinopathy. *Arch Ophthalmol.* 1994; 112: 1057-62.
4. **Hayashi K, Hasegava Y, Tokoro T.** Indocyanine green angiography of Central Serous Chorioretinopathy. *Int Ophthalmol.* 1986; 9: 37-41.
5. **Haimovici R, Rumelt S, Melby J.** Endocrine abnormalities in patients with Central Serous Chorioretinopathy. *Ophthalmology.* 2003; 110: 698.
6. **Kanski JJ:** Acquired macular disorders. In *Clinical Ophthalmology* 6<sup>th</sup> ed; Butterworth Hienemann. 2007; 468.
7. **Von Ruckmann A, Fitzke Frederick W, Fan Joseph, et al.** Abnormalities of Fundus autofluorescence in Central Serous Retinopathy. *Am J Ophthalmol* 2002; 133: 780-6.
8. **Cynthia ACR, Lawrence A, Yannuzzi et al:** Corticosteroids and Central Serous Chorioretinopathy. *Ophthalmology* 2002; 109: 1834.
9. **Baig MSA, Zafar M, Rab M, Ahmed J.** Role of Fundus Fluorescein Angiography in the diagnosis of Central Serous Chorioretinopathy. *Pak J Surg.* 2004; 20: 31-4.