

Clinical Presentations of Benign Intraconal Tumors

Asad Raza Jafri, Muhammad Saeed Iqbal, Memon Muhammad Khan, Partab Rai

Pak J Ophthalmol 2008, Vol. 24 No. 4

.....
See end of article for
authors affiliations

Purpose: To determine the clinical presentations of benign intraconal orbital tumors for early diagnosis and prompt treatment.

.....

Correspondence to:
Asad Raza Jafri
Flat # 105/1,
Asaish Apartment, Block-16,
Gulistan-e-Johar, 75290
Karachi

Material and Methods: This study was conducted in the Department of Ophthalmology, Jinnah Post graduate Medical Centre, Karachi from March 2004 to February 2006. Total 30 patients of all age groups with axial proptosis and mass in the intraconal region seen on CT scan or MRI were included and followed for one year. Patients' presenting complaints and clinical examination (ocular/systemic) were noted. Diagnosis of disease was confirmed on the histopathology of excised mass.

Results: The commonest clinical presentation was axial proptosis in all (100%) cases followed by decreased visual acuity in 18 (60%) cases, corneal exposure in 5 (16.66%) cases, choroidal folds in 4 (13.33%) cases and complete loss of vision in 3 (10%) cases caused by compression of optic nerve.

Histopathology showed Lymphangioma in 11 (36.66%) cases, Cavernous hemangioma in 9 (30%), Neurofibroma in 4 (13.33%), Schwannoma in 3 (10%), Hemangiopericytoma in 2 (6.66%) and Optic nerve glioma in 1 (3.33%) case.

Conclusion: Early diagnosis on the basis of clinical presentation, imaging and histopathologically can prevent loss of vision and other complications.

Received for publication
March' 2008

.....

Orbit is a closed cavity with compact arrangement of different tissues derived from all three germinal layers, containing the globe, extra-ocular muscles, fat, vascular tissue, nerves, glandular and connective tissue which are essential for ocular functions. A wide variety of pathologies and space occupying lesions can be seen in any age, sex and race¹.

Sub-dividing the orbit into intra and extra-conal compartment is clinically correct but is not formulated on anatomic ground because no structure separates these two areas. Major fibrous septa connect the extra-ocular muscles to the periosteum and do not form a continuous inter-muscular membrane in the orbit^{2,3}.

Intra-conal space refers to an area bounded by the four recti muscles extending from the posterior surface of the globe to the annulus of Zinn at the apex of the orbit.

Tumors within the muscle cone lead to an axial proptosis in most cases, which by compressing the optic nerve may cause a decrease in the visual acuity⁴ and may also cause limitation of extraocular movements.

These are usually benign growths specially cavernous haemangioma⁵, which is the most common arising from a preexisting but non-patent vascular malformations⁶. Others include haemangiopericytoma⁷, lymphangioma, schwannoma⁸, optic nerve glioma and optic nerve sheath meningioma.

Assessment of the space-occupying lesion within the muscle cone needs certain modalities of radiological imaging such as plain x-ray orbit, ophthalmic B-scan ultrasonography, computed tomography (CT scan) and magnetic resonance imaging (MRI) of orbit and brain⁹.

If the intra-conal lesion is causing compressive effects over the optic nerve, it requires immediate treatment so that vision can be saved. Restoration of the eyeball to its normal position with the preservation of vision, ocular motor functions and cosmesis are the main goals of surgical intervention.

The purpose of the study was to highlight the importance of early presentation and early referral of patients with intraconal tumors to the respective departments which can help to prevent both visual and more importantly physical morbidity.

MATERIAL AND METHODS

This study was conducted at the Department of Ophthalmology, Jinnah Postgraduate Medical Centre, Karachi, during the period of two years from March 2004 till February 2006. Total 30 cases were included in this study and followed for duration of one year. The data was recorded in SPSS version 10.

Inclusion criteria were any patient with axial proptosis and patient with mass in intraconal region on CT scan or MRI. Patients presenting with non axial proptosis and patients with mass extending outside the intraconal region on imaging were not included in the study.

All patients were admitted in eye ward JPMC. A detailed history was obtained on a printed proforma. Particular attention was given to the history of any existing or previous ocular disorder, past history of trauma and any previous ocular or orbital surgery. All patients were inquired about any systemic illness especially diabetes mellitus, hypertension, and hyperthyroidism.

The ocular examination was started with assessment of best corrected far and near visual acuity for each eye. Anterior segment was examined with slit lamp biomicroscope, giving special emphasis on the condition of the cornea and pupil abnormalities like RAPD. IOP was recorded with applanation tonometer in primary and up gaze. Retinal examination was performed by the indirect ophthalmoscope using +20D lens and on slit lamp biomicroscopy with +90D lens. In orbital examination, axial proptosis was measured with Hertel exophthalmometer¹⁰ and any associated horizontal and vertical displacements were measured with the help of scale. Ocular motility defect associated with any diplopia was also recorded.

Ear, nose and throat examination was done in all patients to rule out the presence of any para-nasal sinuses or nasopharyngeal mass which could be the possible etiological factor in producing proptosis¹⁰.

The systemic examination (especially chest and abdomen) was performed to search for primary neoplasm elsewhere in the body¹⁰ and vice versa. Following investigations were done:

- Complete Blood and ESR
- Serum TSH, T₃, T₄
- X-ray orbits
- Ophthalmic B-scan ultrasonography (USG).
- CT scan/MRI (orbit and brain)
- X-ray chest
- Abdominal USG

Excisional biopsy and then histopathological studies assisted to reach the final diagnosis.

RESULTS

Of these 30 patients 18 (60%) were male and 12 (40%) were female (Fig. 1) with a mean age of 35 years (ranging from 10–60 years).

All these 30 patients (100%) presented with axial proptosis. Beside this, second common presentation was decreased visual acuity in 18 (60%) cases followed by corneal exposure in 5 (16.66%) cases, choroidal folds in 4 (13.33%) cases and complete loss of vision in 3 (10%) cases (Table 1).

Defective vision of these patients was documented. Twelve patients (40%) presented with best corrected vision of 6/18 or better, 02 patients (6.67%) presented with vision of 6/60 to 6/36, vision of 12 patients (40%) was between 1/60 to 5/60, 01 patient (3.3%) had perception of only hand movement while 03 patients (10%) had absence of projection of light (Table 2).

In addition to clinical presentation, diagnosis of all cases was confirmed as intraconal tumors on the basis of ultrasonography and CT/MRI scan imaging (Fig. 2). Each case was treated surgically and histopathological studies further confirmed the diagnosis.

Table 1: Clinical presentation of intraconal tumors n = 30

Clinical Presentation	No. of Patients n (%)
Axial proptosis	30 (100)
Decreased visual acuity	18 (60)
Corneal exposure	5 (16.7)
Choroidal folds	4(13.3)
Complete loss of vision	3 (10)

Table 2: Visual acuity at the time of presentation n= 30

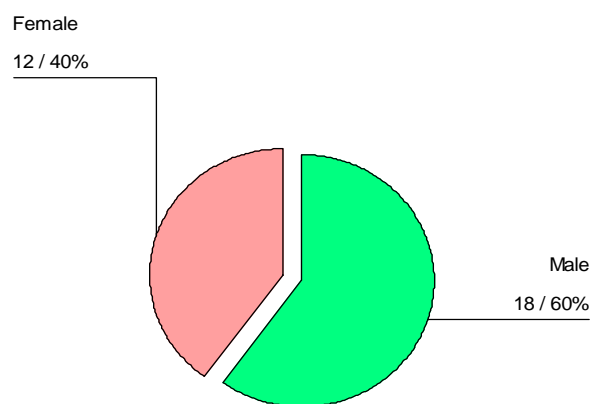
Best corrected visual acuity	No. of patients n (%)
Projection of light absent	3 (10)
Projection of light present	0 (0)
Hand movement perceived	1(3)

Between 1/60-3/60	7(23)
Between 4/60-5/60	5 (17)
Between 6/60-6/34	2 (7)
Between 6/18-6/9	12(40)

Table 3 Histopathological diagnosis n = 30

Histopathological Diagnosis	No. of patients n (%)
Lymphangioma	11 (37)
Cavernous haemangioma	9 (30)
Neurofibroma	4 (3)
Schwanoma	3 (10)
Haemangiopericytoma	2 (7)
Optic nerve glioma	1 (3)

Histopathological studies reported that the most common intraconal tumor is Lymphangioma (Fig. 3) which was found in 11 (36.66%) cases. Nine (30%) cases were proved to be Cavernous haemangioma (Fig. 4). Neurofibroma was present in 04 (13.33%) cases, Schwanoma in 03 (10%) cases, Haemangiopericytoma in 02 (6.66%) and optic nerve glioma in 1 (3.33%) case (Table 3).



Male: Female = 1.5: 1

Fig. 1: Sex distribution n = 30

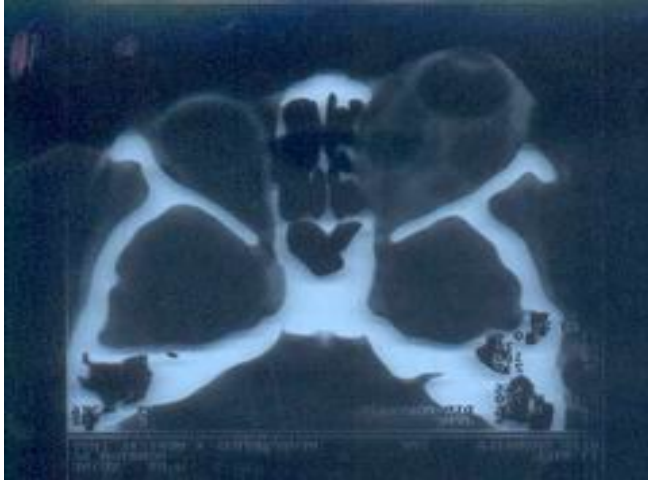

Fig. 2: Axial view - showing multiple intraconal cystic lesions

DISCUSSION

The orbital tumors increase orbital volume and cause a mass effect. Although a mass may be histologically benign but it can invade intraorbital or adjacent orbital structures and can cause significant damage. A wide variety of pathological processes and space occupying lesions can be seen in any age, sex and race¹.

When dealing with the benign intraconal orbital tumors one must keep in mind that they are slow growing usually presenting with the forward displacement of globe¹¹, because of their tendency to lead irreversible loss of vision due to the mass effect on the optic nerve. Direct optic nerve compression, globe indentation with induced hyperopia, or increased intracranial pressure with optic nerve compression may be responsible for visual symptoms¹². Christante¹³ in his study reported that out of 57 patients, proptosis was the main presenting complaint in 80% of cases while 40% had visual deterioration. Zhang¹⁴ in his study reported 17 (77.27%) out of 22 patients with visual impairment as the first presenting symptom. Thorn-Kany¹⁵ in his study of 8 patients reported that seven cases presented with a painless proptosis and in one case with a failing of visual acuity of the concerned eye. Selva D¹⁶, in his study of 5 cases has reported that all cases presents with a history of progressive painless proptosis and CT scan revealed homogenous intraconal mass. In our study the most common clinical presentation was axial proptosis in all the 30 (100%) cases while visual loss was found in 18(60%) of cases. Early surgery for removal of the tumor was favored after onset of symptoms.

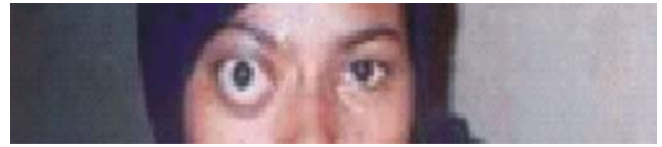

Fig. 3: Lymphangioma



Fig. 4: Cavernous haemangioma

Shields JA¹⁷, reported the most commonly diagnosed intraconal tumors were lymphoid tumor (139 cases; 11%), cavernous haemangioma (77 cases; 6%), lymphangioma (54 cases; 4%) and optic nerve glioma (48 cases; 4%). Wright¹⁸ suggested that lymphangiomas are variants of venous malformations but clinical, haemodynamic and histopathologic studies strongly suggest that lymphangiomas are distinct orbital hamartomas¹⁹. These are benign tumors and often present during childhood, the largest reported series by Jones²⁰ involving 62 cases.

We have 2 cases of cavernous haemangioma and 1 case of neurofibroma. It was easy to reach at exact tissue diagnosis after histopathological opinion except in the cases of lymphangioma where the multiple cystic lesions were found on CT scan and preoperatively. When tissue specimens were reviewed by histopathologist, different vascular channels and cystic spaces filled with blood or fluid were noted. On the basis of clinical, radiological and histopathological findings, we were able to label these patients as lymphangioma.

CONCLUSION

The most common clinical presentation of intraconal tumors is axial proptosis but there are some uncommon presentations which can lead to misdiagnosis of such orbital masses. Tumor location and radiological findings can provide important information regarding the diagnosis of a tumor prior to biopsy or tumor resection. This will help in the determination of treatment strategy. Prompt referral of the patient to the department with facility for orbital surgery plays crucial role in this regard.

Author's affiliation

Dr. Asad Raza Jafri
Senior Registrar Ophthalmology
Karachi Medical & Dental College
North Nazimabad, Karachi

Dr. Muhammad Saeed Iqbal
Assistant Professor Ophthalmology
Sir Syed College of Medical Sciences Hospital
Qayyumabad, Korangi Raod, Karachi

Dr. Memon Mohammad Khan
Assistant Professor Ophthalmology
Kulsoom Bai Valika Hospital,
S.I.T.E., Karachi

Dr. Partab Rai
Assistant Professor Ophthalmology
Chandka Medical College and Hospital
Larkana

REFERENCE

1. **Munir-ul-haq M.** A statistical analysis of 581 primary orbital tumors in Pakistan. *Pak J Ophthalmol.* 1987; 3: 111-20.
2. **Whitnall SE.** Anatomy of human organs and accessory organs of vision. 2nd ed. London: Oxford University Press. 1932.
3. **Koorneff L.** New insight in the human orbital connective: results of new anatomic approach. *Arch Ophthalmol.* 1977; 95: 1269.
4. **Shields JA, Blackwell B, Augsburger JJ.** Classification and incidence of space-occupying lesions of the orbit. A survey of 654 biopsies. *Arch Ophthalmol.* 1984; 102: 1606-11.
5. **Hood CI.** Cavernous hemangioma of the orbit. A consideration of pathogenesis with an illustrative case. *Arch Ophthalmol.* 1970; 83: 49-53.
6. **Cabrera Vargas ME, Perez AJ, Diaz AC, et al.** Orbital hemangiopericytoma: a case with involvement of the intraconal space. *Arch Soc Esp Oftalmol.* 2000; 75: 701-4.
7. **Tsuzuki N, Katoh H, Ohnuki A, et al.** Cystic Schwannoma of the orbit: case report. *Surg Neurol.* 2001; 5: 384.
8. **Asif M, Shafiq K, Ahmed M, et al.** Orbital masses: incidence and clinical presentation. *Pak J Ophthalmol.* 1998; 14:149-152.
9. **Fafowora OF, Cookey-gam AI, Obajimi MO.** Radiological evaluation of orbital tumors in Ibadan, Nigeria. *Afr J Med Sci.* 1996; 25: 361-4.
10. **Khurana AK.** Investigations of orbital space occupying lesions, In modern Ophthalmology by LC Datta. Jaypee Brothers Publishers, New Delhi, 1st edition. 1994: 89-102.
11. **Geoffrey J, Gladstone, Frank A, John DS.** Intraconal tumors of the orbit. 4th edition W.B. Saunders Company. 1994; 13: 99.
12. **Cockerham KP, Cockerham GC, Stutzman R, et al.** The clinical spectrum of schwannomas presenting with visual dysfunction: a clinico-pathologic study of three cases. *Surv Ophthalmol.* 1994; 44: 226-34.
13. **Cristane L.** Surgical treatment of meningioma of the orbit and optic canal: A retrospective study with particular attention to visual outcome. *Acta Neuroarchiv.* 1994; 126: 27-32.
14. **Zhang CH, Zhang TC, Zhong JS, et al.** Early diagnosis of the tumors in orbital apex and optic nerve. *Zhonghua Yan Ke Za Zhi.* 2004; 40: 34-6.
15. **Thorn-Kany M, Arrue P, Delisle MB, et al.** Cavernous hemangiomas of the orbit: MR imaging. *Neuroradiol.* 1999; 26: 79-86.
16. **Selva D, Strianeses D, Bonavolonta G, et al.** Orbital venous lymphatic malformations (Lymphangiomas) mimicking cavernous hemangiomas. *Am J Ophthalmol.* 2001; 131: 364-70.
17. **Shields JA, Shields CL, Scartozzi R.** Survey of 1264 patients with orbital tumors and simulating lesions. *Ophthalmology.* 2004; 111: 997-1008.
18. **Wright JE.** Orbital vascular anomalies. *Trans Am Acad Ophthalmol Otolaryngol.* 1974; 78: 606.
19. **Rootman J, Hay E, Grace D.** Orbital adnexal lymphangioma: A spectrum of haemodynamically isolated vascular hamartoma. *Ophthalmol.* 1986; 93: 1558.
20. **Jones IS.** Lymphangioma of ocular adnexa. An analysis of 62 cases. *Trans Am Ophthalmol Soc* 1959; 57: 602.