

Role of Orbital Septum and Sub Orbicularis Fibroadipose Tissue in Congenital Ptosis Surgery

Rao Muhammad Rashad Qamar, Qasim Mansoor, Mazhar-uz-zaman Somro, Imran Atta-ulah

Pak J Ophthalmol 2008, Vol. 24 No. 3

.....
See end of article for
authors affiliations

.....

Correspondence to:
Rao Muhammad Rashad
Qamar
29-B, Medical Colony
Bahawalpur

Received for publication
January' 2007
.....

Purpose. To analyze the role of orbital septum and suborbicularis fibroadipose tissue in making and defining upper lid skin crease in children who underwent ptosis surgery.

Material and Methods. A retrospective study of 26 eyes of 22 children (age range 04 to 14 years) undergoing surgery over two year period was undertaken with regard to cosmetic outcome. A surgical technique by anterior approach employing orbital septum sutures during surgery in children is described. All surgery was performed by same ophthalmic surgeon under general anesthesia. A standard levator resection was undertaken, following which orbital septum and suborbicularis fibro adipose tissue was redefined and sutured with 6/0 vicryl.

Result. All patients achieved a well-defined lid crease postoperatively, with a good cosmetic outcome. The significant postoperative complications were stitch granuloma in two patients and mild residual ptosis occurred in five cases, requiring further procedure.

Conclusion: Special attention to the suturing of orbital septum and suborbicularis fibro adipose tissue as a separate tissue layer during levator resection in congenital ptosis gives good lid crease definition which may enhance the overall cosmetic outcome.

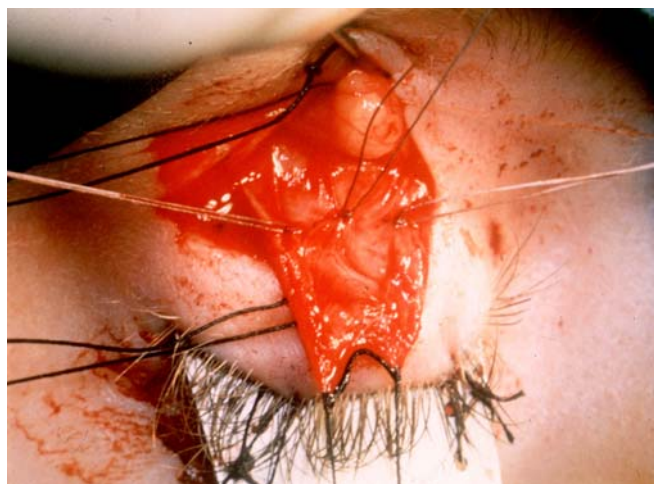
It is an important consideration in congenital ptosis surgery to achieve bilaterally symmetrical upper lid skin crease in both height and shape. Particular attention has to be paid to unilateral ptosis, as a failure to do so may give poor cosmetic outcome. The orbital septum along with fibrous septa in sub orbicularis oculi fibroadipose tissue plays an important role in defining the upper lid skin crease. An inadequately defined and misplaced skin crease typically gives rise to an asymmetrical appearance.

A series of patients undergoing surgery for congenital ptosis is described. The orbital septum and submuscular fibroadipose tissue were sutured to define the lid crease.

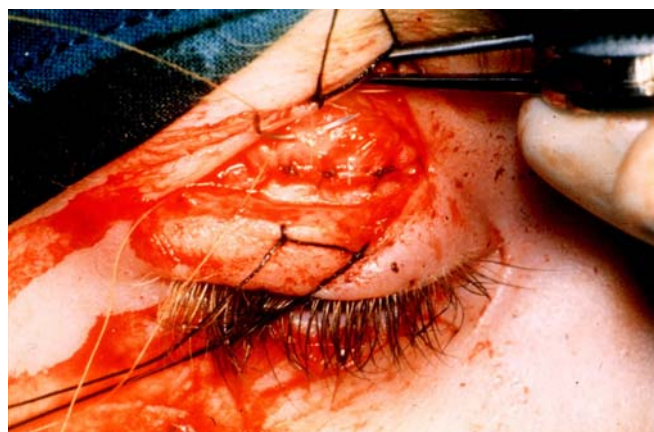
MATERIAL AND METHODS

22 children undergoing levator resection over a two year period were assessed with regard to postoperative cosmetic appearance. Four cases were bilateral. The average age at the time of surgery was 4 years (range 6 months to 14 years). Ten patients were male and 12 were female. Average follow up was 2 years (range: 3 months to 4 years). All surgery was same performed by one consultant ophthalmic surgeon under general anesthesia.

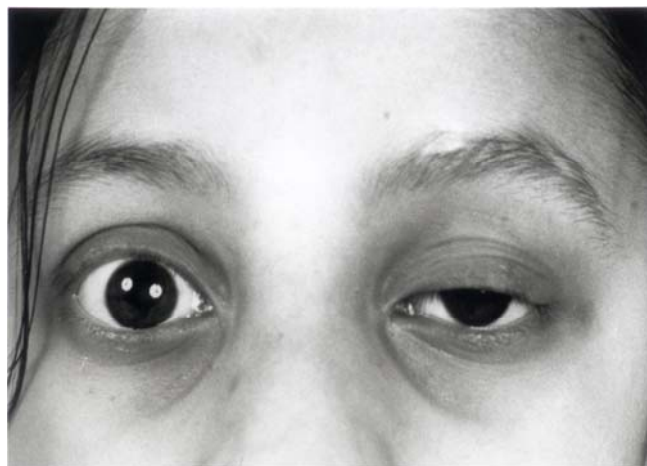Legends:



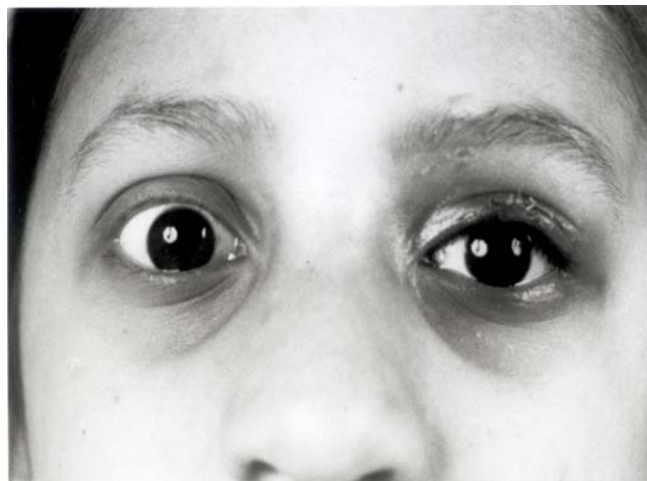1. Levator exposed, resected and sutured.



2. Orbital septum sutured.



3a- Pre operative ptosis



3b- postoperative good lid crease with acceptable ptosis correction

The surgical technique comprised of separation of all layers and identification of suborbicularis fibroadipose tissue and orbital septum. The orbital septum was identified by grasping the tissue in question and pulling it inferiorly while palpating inner border of

supraorbital rim. When the levator muscle exposed a rough measurement was taken by caliper keeping in mind the amount of levator resection needs to correct the given ptosis. Following standard levator resection, the orbital septum along with submuscular fibroadipose tissue was sutured with interrupted 6/0 vicryl and in few cases chromic catgut 6/0 was used for suturing of orbital septum. The overlying orbicularis was also repaired, and the skin was closed with interrupted 6/0 vicryl. A 4/0 silk tension suture was placed through margin of lower tarsus, taped to the forehead and removed after 24 hours.

RESULTS

In all patients a well-defined lid crease symmetrical in height and shape was obtained. The significant postoperative complications were suture related granuloma in two patients that did not influence the final outcome. Good lid height and shape of skin crease was obtained in 17 patients, however residual ptosis occurred in 5 cases and required further surgical procedure at a later date. Reoperation was uncomplicated and final outcome was successful.

DISCUSSION

Embryologically, most of the connective tissue of upper lid is derived from mesenchyme¹⁻⁴. The orbital septum is derived from mesenchyme of second arch¹. Anatomy of orbital septum is described differently both by anatomists and surgeons but generally it is accepted that orbital septum originates from arcus marginalis of frontal bone and inserts into levator aponeurosis inferiorly near the upper margin of tarsal plate and follows levator aponeurosis forward to skin²⁻⁴. Suborbicularis fibroadipose tissue consists of multiple fibrous septa that merge posteriorly with the orbital septum and give orbital septum a multilayered quality².

Simple congenital ptosis is thought to be the result of developmental dystrophy of levator muscle. Normal muscle fibers are replaced by fibrous connective tissue without contractile properties. Ptosis is more marked in an up gaze and the upper lid is relatively retracted in a down gaze⁵⁻⁶. In ptosis surgery, a good cosmetic outcome is very important, this holds true for congenital myogenic ptosis as well. Ptosis surgery with adjustable suture is popular in adults but least tolerated in children, it is therefore important to consider an approach that gives good ptosis correction with cosmetically acceptable upper

lid skin crease⁷. The ideal procedures in ptosis surgery are those that least disturb normal anatomy but also allow for good results³. In this study an anterior approach was selected, thus avoiding conjunctiva, lacrimal gland and tarsus^{3,5,8}. In all cases, following levator resection, the cut edges of orbital septum were reapposed and sutured^{6,9}. This technique appears to enhance the overall cosmetic outcome. Alternative methods for defining the lid crease in congenital ptosis have been described, in particular closure of skin incision with deep bites to underlying levator aponeurosis^{3,7}.

Fibroadipose tissue appears to enhance the function of orbital septum by augmenting the contour of superior sulcus when eyelids are open. It is very important to locate anatomically where orbital septum fuses with levator aponeurosis^{2,4,10}. It was observed that orbital septum fused with levator aponeurosis a few millimeters (2-4mm) above the supratarsal border. Although slight variation does exist, therefore orbital septum not only contains orbital fat in the orbit but it also plays an important part in keeping cosmetically good upper lid crease.

CONCLUSION

Although many procedures have been described in the surgical management of congenital ptosis, little emphasis has been placed on maintaining the integrity of orbital septum. This study indicates that the placement of orbital septum sutures directly following levator resection may aid the formation of a well defined and positioned skin crease, thus enhancing the cosmetic outcome.

Author's affiliation

Dr. Rao Muhammad Rashad Qamar
Assistant Professor
Quaid-e-Azam Medical College
Bahawalpur

Dr. Qasim Mansoor
Eye Surgeon
UK

Dr. Mazhar-uz-zaman Somro
Eye Surgeon
Khan pur, Distt. Rahim Yar Khan

Dr. Imran Atta-ullah
Eye Surgeon
Haroon Abad

REFERENCE

1. **Bremond-Gignac DS, Deplus S, Cussenot O.** Anatomic study of orbital septum. *Surg radiol Anat.* 1994; 16: 121-4.
2. **Meyer DR, Lindberg JV, Wobig JL.** Anatomy of orbital septum and associated eyelid connective tissues. Implications for ptosis surgery. *Ophthal Plast Reconstr Surg.* 1991; 7: 104-13.
3. **Jones LT.** The anatomy of the upper eyelid and its relationship to ptosis surgery. *Am J Ophthalmol.* 1964; 57: 943-59.
4. **Wolff E:** Anatomy of eye and orbit. Philadelphia, Blackiston Company. 1954: 153-209.
5. **Mustarde J, Callahan A, Jones L:** Ophthalmic Plastic Surgery- Up-to-Date. Birmingham, Aesculapius Publishing, 1970, 6-12.
6. **McElvanney AM, Adhikary HP:** Congenital ptosis, a good cosmetic result with redefinition and suturing of the orbital septum *Eye.* 1996;10: 548-50.
7. **Collin JRO, O'Donnell BA.** Adjustable sutures in eyelid surgery for ptosis and lid retraction. *Br J Ophthalmol.* 1994; 78: 167-74.
8. **Berke RN, Hackensack NJ, Wadsworth JAC.** Histology of levator muscle in congenital and acquired ptosis. *Arch Ophthalmol.* 1955; 53: 413-28.
9. **Baylis HI, Cies WA.** Identifying the orbital septum. *Arch Ophthalmol.* 1976; 94: 805.
10. **Anderson RC, Beard C.** The levator aponeurosis: attachments and their clinical significance. *Arch Ophthalmol.* 1977; 95: 1437-49.