



**EDITORIAL**

- 4 **Open Access: DOAJ and Plan S, Digitization and Disruption**  
Lapeña JF

**ORIGINAL ARTICLES**

- 7 **Nasopharyngeal Tuberculosis in a Philippine Tertiary General Hospital**  
Gomez MAT, Villarta RL, Caro RM, Manasan CVC, Carnate JM
- 11 **Salivary pH and Taste Sensitivity among Geriatric and Non-Geriatric Patients in a Tertiary Hospital: A Cross-Sectional Study**  
Crisostomo MV, Ureta CV
- 16 **Timing of Tracheostomy, Weaning from Mechanical Ventilation and Duration of Hospitalization among a Sample of Pediatric Patients**  
Ferroliano JBA, Lapeña JFF, Carrillo RJD
- 20 **Timing of Tracheostomy and Outcomes in Adults with Moderate and Severe Tetanus: A Cross-Sectional Study**  
Espinosa WZ, Vinco VV
- 24 **Association of Ultrasonographic Findings and Thyroid Malignancy: A Cross-Sectional Study**  
Trinchera CS, Cruz ETS
- 29 **Maxillofacial Gunshot and Blast Injuries Seen in a Tertiary Military Hospital**  
Garimbao JFP
- 32 **Facial Paralysis in Longitudinal versus Oblique and Otic-Sparing versus Non Otic-Sparing Temporal Bone Fractures**  
Chua RJ, Lacanilao RC

**CASE REPORTS**

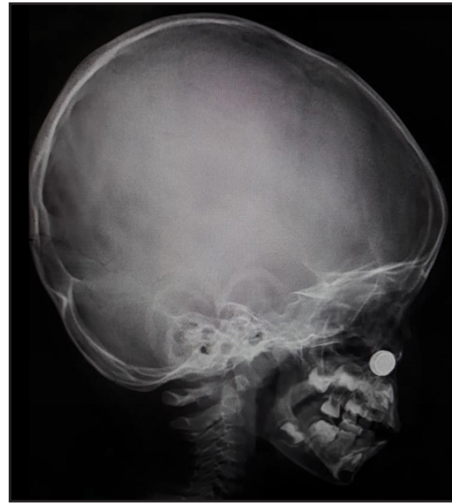- 35 **Kikuchi-Fujimoto Disease in a Filipino Boy: A Case Report**  
Escalderon JRDJ, Monroy AA
- 39 **Congenital Muscular Torticollis: A Case Report**  
Villanueva LMB
- 42 **Emergent Reconstruction of Laryngeal Penetrating Neck Injury: A Case Report**  
Pecolera RS, Onofre RDC
- 47 **Autologous Fat Transfer to Improve Aesthetic Appearance in Facial Asymmetry from Parry-Romberg Syndrome: A Case Report**  
Sison MNK, Cruz ETS, Fernandez MAR

**FEATURED GRAND ROUNDS**

- 52 **Left Hemifacial Lymphatic Malformation in a Nine-Year-Old Boy**  
Cambe SMM, Rabo JIS, Navarro-Locsin CGS

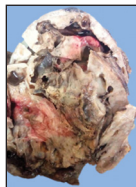
**UNDER THE MICROSCOPE**

- 55 **Traumatic Ulcerative Granuloma with Stromal Eosinophilia**  
Inoferio KSA, Agbay RLM, Carnate JM



- Open Access: DOAJ and Plan S, Digitization and Disruption
- Nasopharyngeal Tuberculosis in a Philippine Tertiary General Hospital
- Salivary pH and Taste Sensitivity among Geriatric and Non-Geriatric Patients in a Tertiary Hospital: A Cross-Sectional Study
- Timing of Tracheostomy, Weaning from Mechanical Ventilation and Duration of Hospitalization among a Sample of Pediatric Patients
- Timing of Tracheostomy and Outcomes in Adults with Moderate and Severe Tetanus: A Cross-Sectional Study
- Association of Ultrasonographic Findings and Thyroid Malignancy: A Cross-Sectional Study
- Maxillofacial Gunshot and Blast Injuries Seen in a Tertiary Military Hospital
- Facial Paralysis in Longitudinal versus Oblique and Otic-Sparing versus Non Otic-Sparing Temporal Bone Fractures
- Kikuchi-Fujimoto Disease in a Filipino Boy: A Case Report
- Congenital Muscular Torticollis: A Case Report
- Emergent Reconstruction of Laryngeal Penetrating Neck Injury: A Case Report
- Autologous Fat Transfer to Improve Aesthetic Appearance in Facial Asymmetry from Parry-Romberg Syndrome: A Case Report
- Left Hemifacial Lymphatic Malformation in a Nine-Year-Old Boy
- Traumatic Ulcerative Granuloma with Stromal Eosinophilia


**COVER IMAGES**



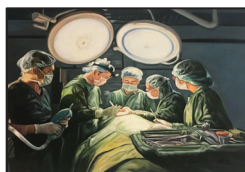From "Under the Microscope"  
Mandibulectomy Specimen  
Phone Huawei Y611  
720x1280 Resolution  
By Jennifer Tan-Go, MD



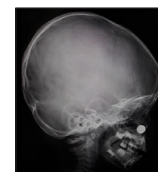"Philippine Banaue Rice Terraces"  
Setting: Photo  
Apple iPad mini 3  
Model No. MGJ22PP/A  
Software version: 12.4.2  
By Rowena C. Saplala



"Alpha Rooster"  
Crayola Markers on Cardboard 8x6  
By Anna Carlissa A. Aujero, MD



"Surhano"  
Acrylic on Canvas 24x36  
By Angelito R. Lepalam 2017



"Digital Lateral Nasal Bone X-Ray"  
of Foreign Body  
Toy Battery in the Nose  
By Justin Ian A. Jabson, MD