



Faith Jennine P. Bacalla, MD
Joman, Q. Laxamana, MD

Department of Otorhinolaryngology
Head and Neck Surgery
Jose B. Lingad Memorial General Hospital

Combined Cartilage Graft Reconstruction of the Nasal Tip Complex after Resection of Nasal Tip Schwannoma: A Case Report

ABSTRACT

Objective: To present a rare case of nasal tip schwannoma and describe its resection and reconstruction using combined cartilage grafts.

Methods:

Design: Case Report
Setting: Tertiary Government Training Hospital
Patient: One

Results: A 13-year-old boy presented with a progressively enlarging nasal tip and severe left nasal obstruction causing breathing difficulties and psychosocial distress. There was a bulging septal mass obstructing 90% of the left nasal cavity. Septal incision biopsy revealed schwannoma and definitive surgery via open rhinoplasty approach was done. The non-encapsulated schwannoma extended from the subcutaneous nasal tip to the left septal mucosa. There was no evidence of skin or cartilage invasion, but prolonged pressure from the expansile schwannoma caused severe lower lateral cartilage and anterior septal atrophy leading to a collapsed and expanded nasal tip after resection. To correct this, a total reconstruction of the anterior tip complex was done using combined ear cartilage seagull wing graft, shield graft and septal extension graft.

Conclusion: Nasal tip and septal schwannoma is rare and can cause significant nasal obstruction and deformity. Complete excision is vital to avoid recurrence. Total reconstruction of the lower lateral cartilages using autologous septal and ear cartilage grafts may be a safe and effective technique that yields acceptable aesthetic results.

Keywords: *nasal septum; nasal tip; schwannoma; ear cartilage; rhinoplasty; nasal cartilages; esthetics; neurilemmoma; adolescent*

Schwannomas are slow growing, benign tumors originating from Schwann cells of the peripheral nerve sheath. About 20-40% of cases occur in the head and neck but it is rarely found in the sino-nasal area¹ and even more rare in the pediatric age group.² Delayed diagnosis and treatment can result in expansive growth that may cause severe functional and aesthetic complications. We present one such case.

Correspondence: Dr. Joman Q. Laxamana
Department of Otorhinolaryngology
Head and Neck Surgery
Jose B. Lingad Memorial General Hospital
McArthur Highway, Dolores
San Fernando, Pampanga 2000
Philippines
Phone: +63 45 409 6688 local 144
Email: jqlaxamana@gmail.com

The authors of this case report declare that this manuscript is an original material, which has not been published or is being considered for publication, partially or in full, in any form. Each author believes the manuscript represents honest work, and all have met the requirements for authorship.

Disclosures: The authors signed a disclosure that no financial or other personal relationships, intellectual passion, or personal beliefs and institutional affiliations may lead to conflict of interests.



Creative Commons (CC BY-NC-ND 4.0)
Attribution - NonCommercial - NoDerivatives 4.0 International

CASE REPORT

A 13-year-old boy presented with a 1-year history of enlarging nasal tip and progressive left nasal obstruction and nostril asymmetry. The nasal tip was bulbous, firm, non-tender and with no skin discoloration. (Figure 1) He had no complaints of nasal discharge, pain, anosmia, epistaxis or paresthesia. Anterior rhinoscopy revealed a smooth, fleshy mass on the left side of the nasal septum occupying 90% of the nasal vestibule. (Figure 2)

Contrast-enhanced Paranasal Sinus Computed Tomography (CT) scan showed a 2.0 x 1.5 x 3.0 centimeter enhancing soft tissue mass occupying the nasal tip and supratip, extending into the mid-portion of the left nasal cavity. (Figure 3) There was thinning of the anterior septal cartilage with no bone erosion.

Endoscopic incision biopsy of the septal mass revealed schwannoma. Definitive surgery involved an open rhinoplasty approach under general anesthesia. A transcolumellar incision combined with a bilateral marginal incision was done to fully expose the mass and nasal septum. The mass was non-encapsulated with its bulk occupying the subcutaneous nasal tip and its flat end extending to the left nasal septal mucosa up to the bony-cartilaginous junction. There was no involvement of the cartilaginous septum and nasal tip skin. Excision of the mass with a margin of normal soft tissue and mucosa was done. The tip component of the mass measured 3.5 x 2.0 x 1.0 cm and the septal component measured 2.5 x 2.0 x 1.0 cm. (Figure 4)

After excision, both the lateral and medial crura of the atrophied lower lateral cartilage were unable to support the expanded nasal tip skin and alae. A neo-cartilage complex was designed using both septal and ear cartilage. The central septal cartilage was harvested while leaving an intact 1cm caudal and dorsal L-strut. The right concha cavum and cyma were also harvested via an anterior incision. (Figure 5) The septal cartilage was used as an extended septal extension graft a small shield graft. The conchal cartilage was divided lengthwise and shaped into the medial and lateral crura. (Figure 6)

Total blood loss was negligible and there was no post-operative pain, bleeding or infection. After 3 months, the nasal tip skin had wrapped around the neo-cartilage complex with good projection and no drooping. There was improvement of the nostril asymmetry and resolution of the left nasal obstruction. (Figure 7) Our patient is being monitored for recurrence and advised to undergo definitive rhinoplasty after 4-5 years.

DISCUSSION

Schwannomas, also known as neurilemmomas are benign usually solitary tumors that originate from Schwann cells of peripheral

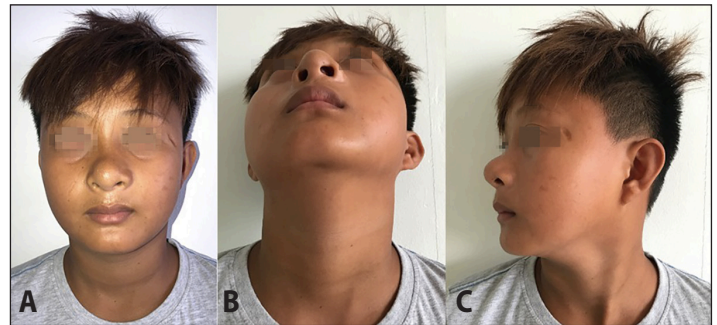


Figure 1. Preoperative photos showing the enlarged nasal tip: **A.** Bulbous nasal tip deviated to the right; **B.** Asymmetrical nostril shape; and **C.** Slight tip rotation and supratip fullness.

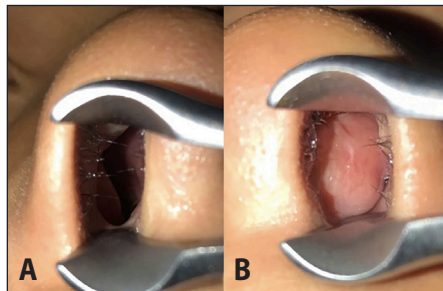


Figure 2. Anterior rhinoscopy findings; **A.** Patent right nasal cavity; **B.** Smooth, pink, fleshy mass occupying 90% of left nasal vestibule and attached medially to the membranous septum and caudal septum.

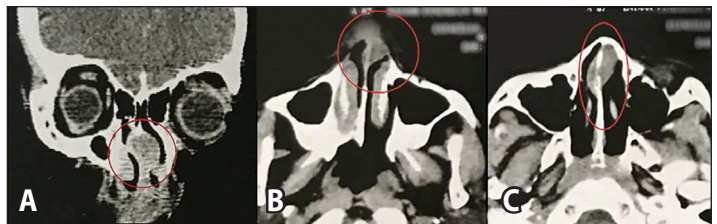


Figure 3. Preoperative contrast enhanced paranasal sinus Computed Tomography (CT) scans; **A.** Coronal view showing an enhancing midline mass predominantly bulging in the left nasal vestibule (encircled); **B.** Axial view showing involvement of the nasal tip superiorly (encircled); and **C.** Axial view showing septal cartilage atrophy where the mass traverses the septum (encircled).

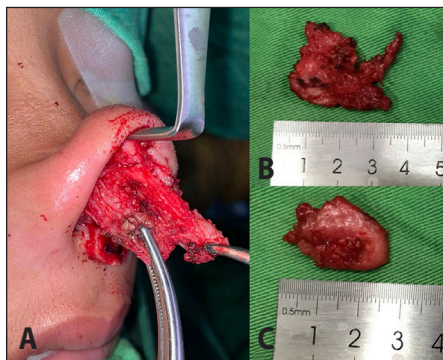

Figure 4. Intraoperative findings: **A.** Open rhinoplasty exposure of non-encapsulated mass firmly attached to nasal vestibular skin and nasal tip soft tissue; **B.** Tip component measuring 3.5 x 2.0 x 1.0 cm; and **C.** Septal component measuring 2.5 x 2.0 x 1.0 cm.

nerve sheaths, which may arise from motor, sensory, sympathetic, or cranial nerves, and thus grow anywhere. In this case the nasal tip schwannoma may have originated from the nasopalatine or nasociliary nerves.³ These tumors usually appear between the 2nd and 4th decade of life and pediatric occurrence as in this case is also extremely rare.²

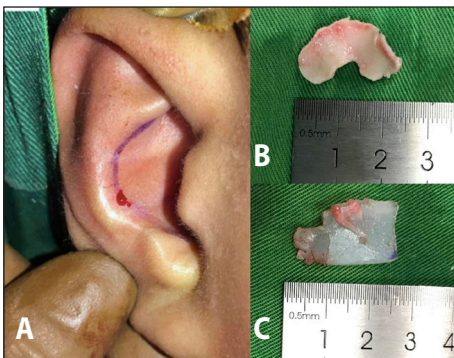


Figure 5. Cartilage harvesting: **A.** Anterior incision with preservation of the helix; **B.** harvested right conchal cartilage; and **C.** harvested central portion of the septal cartilage.

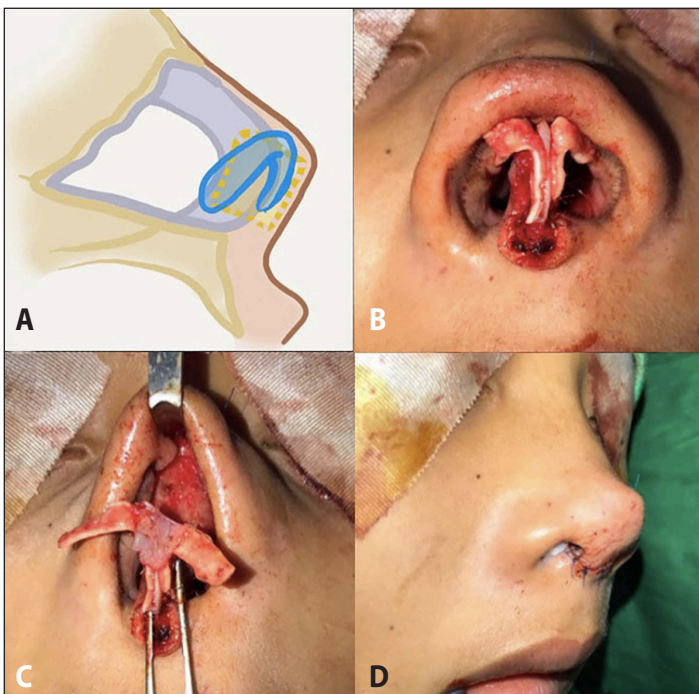


Figure 6. Reconstruction of nasal tip framework: **A.** Schematic diagram of combined seagull wing graft (blue solid lines) and septal extension graft (yellow dashed lines); **B.** Insinuated seagull wing grafts fold to form bilateral crura of the nasal tip; **C.** Portion of septal cartilage used as a shield graft for better tip definition; and **D.** Adequate nasal tip projection and acceptable definition after closure.

About 25-40% of cases are seen on the head and neck and only 4% are sino-nasal.⁴ These most commonly arise from the ethmoid sinuses followed by the maxillary sinuses, nasal cavity and sphenoid sinuses.⁴ Schwannomas of the nasal tip are rare, with to our knowledge, only 11 patients documented in the English literature, based on a search of MEDLINE (PubMed), the Directory of Open Access Journals (DOAJ), and Google Scholar, using the search terms “nasal tip”, “schwannoma” and “neurilemmoma”. Similarly, we found no documented case in the Philippines with an expanded search including HERDIN Plus, the ASEAN Citation Index (ACI) and Western Pacific Region Index Medicus (WPRIM).

Schwannomas may appear as well delineated, globular, firm to rubbery masses. They can be encapsulated or non-encapsulated

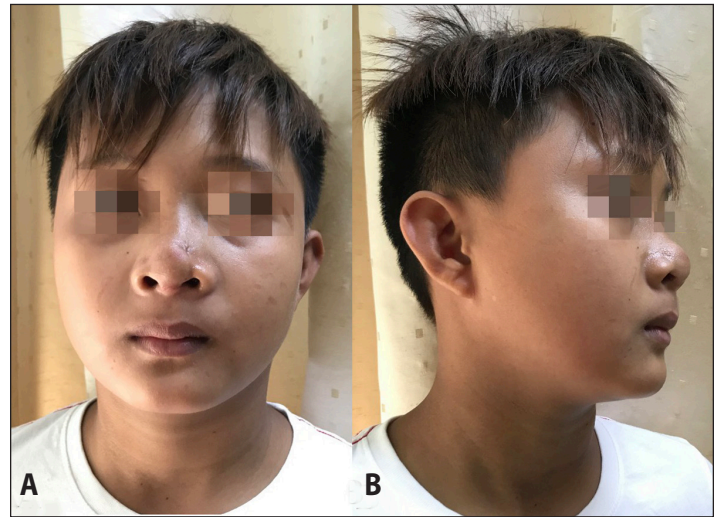

Figure 7. Three month post operative photos: **A.** Acceptable aesthetic outcome and shrinkage of the nasal tip; **B.** Tip is fairly projected even after nasal tip shrinkage and expected natural resorption of cartilage grafts.

(plexiform subtype), making total excision more difficult, as in this case⁵. Frozen section biopsy may be helpful in ensuring tumor-free margins.⁶ A CT scan is useful to determine extent of the mass and involvement of adjacent bony structures but is usually non-diagnostic.⁷ Schwannomas are seen microscopically with cellular Antoni A areas with Verocay bodies and hypocellular myxoid Antoni B areas.⁸ Magnetic Resonance Imaging (MRI) can distinguish between schwannomas with predominant Antoni A component (intermediate signal on T1 and T2) or predominant Antoni B component (hyperintense T2), but it does not show the relevant sinonasal bony anatomy crucial for operative planning.⁷ Immunostaining using S-100 protein can also be done to confirm the diagnosis.⁹

In this case, the bulky schwannoma caused expansion of the nasal tip skin and weakening of the lower lateral cartilages and disruption of fibrous tip support structures. Left unsupported, the unsightly wide tip collapses and constricts the nasal vestibule. To ensure nostril patency and correct the severe tip drooping, the lower lateral cartilage framework should be restored. The ideal material for nasal cartilage reconstruction is autologous septal and ear cartilage. The straight and resilient septal cartilage is ideal for central support and tip projection while the flexible and naturally arched ear cartilages can be formed into similarly curved lower lateral cartilages. There is low morbidity of the donor sites with high resistance to infection and a low rate of resorption.¹⁰ Extracorporeal nasal cartilage reconstruction has been used for cleft nose deformities and severe nasal deformities.¹¹ In 2006, Pedroza *et al.*, developed the seagull wing graft composed of cut conchal cartilages sutured together designed to replace the lower lateral cartilages.¹² Using the limited cartilage we harvested, we constructed



a nasal tripod by combining the seagull wing graft, septal extension graft and a shield graft. This complex could support the weight of the nasal tip and withstand the forthcoming wound contracture thereby preventing tip collapse, alar pinching and poor tip definition. To the best of our knowledge, our case is the first instance of nasal tip framework reconstruction using combined conchal seagull wing graft and a septal extension graft based on a search of MEDLINE (PubMed), the Directory of Open Access Journals (DOAJ), and Google Scholar, using the MeSH terms “rhinoplasty”, “ear cartilage” and “surgical flaps”. Our initial results suggest that the composite neo-cartilage structure may act as an effective tripod for long term tip support. The expanded skin and soft tissue envelope are also expected to “shrink-wrap” around the neo-cartilage over time leading to a more aesthetically pleasing tip shape.

After total excision, the recurrence rate is 5%¹³ and there are accounts of rare malignant transformation so that long-term follow-up is advised.¹⁴ Our case is further complicated by the young age of the patient. His facial skeleton and nasal septal cartilages will mature to adult size around the age of 18¹⁵ and definitive rhinoplasty should be delayed until that time.

In summary, schwannoma of the nasal tip and septum is rare and can cause significant nasal obstruction and deformity. The plexiform non-encapsulated subtype necessitates more aggressive resection to ensure tumor free margins and low risk of recurrence. Our novel technique of total lower lateral cartilage reconstruction using combined seagull wing ear cartilage graft, shield graft and a septal extension graft may be a safe and effective procedure with an acceptable aesthetic outcome.

REFERENCES

1. Karatas A, Cebi IT, Salviz M, Kocak A, Selcuk T. Schwannoma of the Nasal Septum. *Egypt J Ear Nose Throat Allied Sci.* 2016 Nov;17(3):185-188. DOI: 10.1016/j.ejenta.2016.06.001.
2. Başar İ, Hanalioğlu Ş, Narin F, Bilginer B. Pediatric vestibular schwannomas: Evaluation of clinical features, treatment strategies and long-term results of 10 cases. *Tr-ENT.* 2018;28(3):116-125. DOI: 10.5606/Tr-ENT.2018.57966.
3. Dhawle MS, Rathod SG, Bhatkule MA, Bindu RS. Sinonasal Schwannoma - A Case Report. *J Clin Diagn Res.* 2017 May;11(5):ED22-ED23. DOI:10.7860/JCDR/2017/21532.9851; PubMed PMID: 28658783; PubMed Central PMCID: PMC5483685.
4. Kumar S, Sayoo C. Sinonasal Schwannoma: A Rare Sinonasal Neoplasm. *Indian J Otolaryngol Head Neck Surg.* 2017 Sep;69(3):425-427. DOI:10.1007/s12070-017-1125-2; PubMed PMID: 28929080; PubMed Central PMCID: PMC5581763.
5. Destro F, Sharma S, Maestri L, Vella C, Collini P, Riccipetroni G. Visceral plexiform schwannoma: A case series. *Mol Clin Oncol.* 2021 Jan;14(1):14. DOI:10.3892/mco.2020.2176; PubMed PMID: 33282289; PubMed Central PMCID: PMC770955.
6. Nanarng V, Jacob S, Mahapatra D, Mathew JE. Intraoperative diagnosis of central nervous system lesions: Comparison of squash smear, touch imprint, and frozen section. *J Cytol.* 2015 Jul-Sep;32(3):153-158. DOI:10.4103/0970-9371.168835; PubMed PMID: 26729974; PubMed Central PMCID: 26729974.
7. Kim YS, Kim HJ, Kim CH, Kim J. CT and MR imaging findings of sinonasal schwannoma: a review of 12 cases. *AJNR Am J Neuroradiol.* 2013 Mar;34(3):628-33. DOI: 10.3174/ajnr.A3257; PubMed PMID: 22954739; PubMed Central PMCID: PMC7964917.
8. Wippold FJ 2nd, Lubner M, Perrin RJ, Lämmle M, Perry A. Neuropathology for the neuroradiologist: Antoni A and Antoni B tissue patterns. *AJNR Am J Neuroradiol.* 2007 Oct;28(9):1633-8. DOI: 10.3174/ajnr.A0682; PubMed PMID: 17893219; PubMed Central PMCID: PMC8134199.
9. Buob D, Wacrenier A, Chevalier D, Aubert S, Quinchon JF, Gosselin B, Leroy X. Schwannoma of the sinonasal tract: a clinicopathologic and immunohistochemical study of 5 cases. *Arch Pathol Lab Med.* 2003 Sep;127(9):1196-9. DOI: 10.5858/2003-127-1196-SOTSTA; PubMed PMID: 12946223.
10. Kim JY, Yang HJ, Jeong JW. A New Technique for Conchal Cartilage Harvest. *Arch Plast Surg.* 2017 Mar;44(2):166-169. DOI:10.5999/aps.2017.44.2.166; PubMed PMID: 28352607; PubMed Central PMCID: PMC5366525.
11. Tasca I, Compadretti GC, Losano TI, Lijdens Y, Boccio C. Extracorporeal septoplasty with internal nasal valve stabilisation. *Acta Otorhinolaryngol Ital.* 2018 Aug;38(4):331-337. DOI:10.14639/0392-100X-1525; PubMed PMID: 30197424; PubMed Central PMCID: PMC6146577.
12. Pedroza, F, Anjos, GC, Patrocinio, LG, Barreto, JM, Cortes, J, Quessep, SH. Seagull Wing Graft. *Arch Facial Plast Surg.* 2006 Nov-Dec;8(6):396-403. DOI: 10.1001/archfaci.8.6.396; PubMed PMID: 17116787.
13. Fehlings MG, Nater A, Zamorano JJ, Tetreault LA, Varga PP, Gokaslan ZL, et al. Risk Factors for Recurrence of Surgically Treated Conventional Spinal Schwannomas: Analysis of 169 Patients from a Multicenter International Database. *Spine (Phila Pa 1976).* 2016 Mar;41(5):390-398. DOI:10.1097/BRS.0000000000001232; PubMed PMID: 26555828; PubMed Central PMCID: PMC4769652.
14. Mey KH, Buchwald C, Daugaard S, Prause JU. Sinonasal schwannoma--a clinicopathological analysis of five rare cases. *Rhinology.* 2006 Mar;44(1):46-52. PubMed PMID: 16550950.
15. van der Heijden P, Korsten-Meijer AG, van der Laan BF, Wit HP, Goorhuis-Brouwer SM. Nasal Growth and Maturation Age in Adolescents: A Systematic Review. *Arch Otolaryngol Head Neck Surg.* 2008 Dec;134(12):1288-1293. DOI:10.1001/archoto.2008.501; PubMed PMID: 19075124.